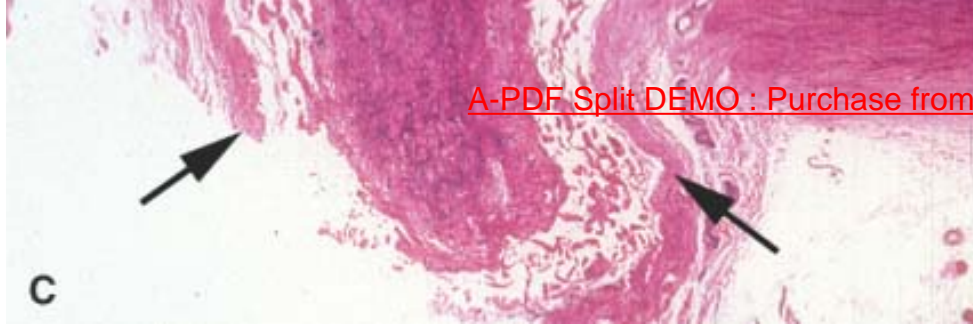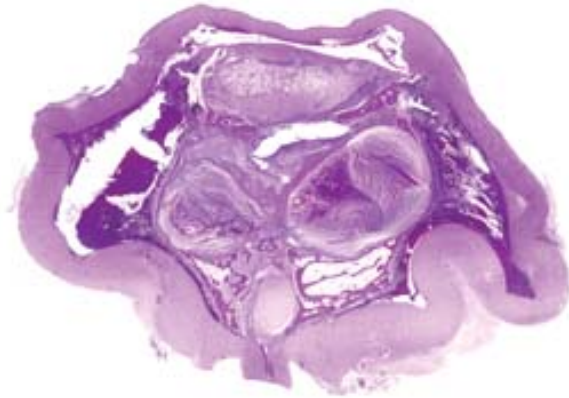


**Figure 29-27** Phthisis bulbi. The eye is small and internally disorganized. The tension exerted on this hypotonic eye by the extraocular muscles contributes to a square rather than round shape. Note the atrophic optic nerve and the presence of intraocular bone posteriorly and anteriorly.



## References

1. Friend SH, Bernards R, Rogelj S, et al: A human DNA segment with properties of the gene that predisposes to retinoblastoma and osteosarcoma. *Nature* 323:643–646, 1986.
2. Hatton MP, Rubin PA: The pathophysiology of thyroid-associated ophthalmopathy. *Ophthalmol Clin North Am* 15:113–119, 2002.
3. Perry SR, Rootman J, White VA: The clinical and pathologic constellation of Wegener granulomatosis of the orbit. *Ophthalmology* 104:683–694, 1997.
4. Rao NA, Hidayat AA, McLean IW, Zimmerman LE: Sebaceous carcinomas of the ocular adnexa: a clinicopathologic study of 104 cases, with five-year follow-up data. *Hum Pathol* 13:113–122, 1982.
5. Nichols CW, Eagle RC Jr, Yanoff M, Menocal NG: Conjunctival biopsy as an aid in the evaluation of the patient with suspected sarcoidosis. *Ophthalmology* 87:287–291, 1980.
6. Scott IU, Karp CL, Nuovo GJ: Human papillomavirus 16 and 18 expression in conjunctival intraepithelial neoplasia. *Ophthalmology* 109:542–547, 2002.
7. Folberg R, Jakobiec FA, Bernardino VB Jr, Iwamoto T: Benign conjunctival melanocytic lesions: clinicopathologic features. *Ophthalmology* 96:436–461, 1989.
8. Jakobiec FA, Folberg R, Iwamoto T: Clinicopathologic characteristics of premalignant and malignant melanocytic lesions of the conjunctiva. *Ophthalmology* 96:147–166, 1989.
9. Klintworth, GK: The molecular genetics of the corneal dystrophies: current status. *Front Biosci* 8:D687–D713, 2003.
10. Stone EM, Fingert JH, Alward WL, et al: Identification of a gene that causes primary open angle glaucoma. *Science* 275:668–670, 1997.

11. Swiderski RE, Ross JL, Fingert JH, et al: Localization of MYOC transcripts in human eye and optic nerve by in situ hybridization. *Invest Ophthalmol Vis Sci* 41:3420–3428, 2000.
  12. Kuo I, Rao NA: Ocular disease in AIDS. *Springer Semin Immunopathol* 21:161–177, 1999.
  13. Zamir E, Hudson H, Ober RR, et al: Massive mycobacterial choroiditis during highly active antiretroviral therapy: another immune-recovery uveitis? *Ophthalmology* 109:2144–2148, 2002.
  14. Boyd SR, Young S, Lightman S: Immunopathology of the noninfectious posterior and intermediate uveitides. *Surv Ophthalmol* 46:209–233, 2001.
  15. Singh AD, Topham A: Incidence of uveal melanoma in the United States: 1973–1997. *Ophthalmology* 110:956–961, 2003.
  16. Singh AD, Topham A: Survival rates with uveal melanoma in the United States: 1973–1997. *Ophthalmology* 110:962–965, 2003.
  17. Seddon JM, Albert DM, Lavin PT, Robinson N: A prognostic factor study of disease-free interval and survival following enucleation for uveal melanoma. *Arch Ophthalmol* 101:1894–1899, 1983.
  18. Folberg R, Salomao D, Grossniklaus HE, Proia AD, Rao NA, Cameron JD: Recommendations for the reporting of tissues removed as part of the surgical treatment of common malignancies of the eye and its adnexa: the Association of Directors of Anatomic and Surgical Pathology. *Hum Pathol* 34:114–118, 2003.
  19. Aalto Y, Eriksson L, Seregard S, Larsson O, Knuutila S: Concomitant loss of chromosome 3 and whole arm losses and gains of chromosome 1, 6, or 8 in metastasizing primary uveal melanoma. *Invest Ophthalmol Vis Sci* 42:313–317, 2001.
  20. Maniotis AJ, Chen X, Garcia C, et al: Control of melanoma morphogenesis, endothelial survival, and perfusion by extracellular matrix. *Lab Invest* 82:1031–1043, 2002.
  - 20A. Folberg R, Maniotis AJ: Vasculogenic mimicry. *ARMIS* (in press), 2004.
  21. Clarijs R, Otte-Holler I, Ruiter DJ, de Waal RM. Presence of a fluid-conducting meshwork in xenografted cutaneous and primary human uveal melanoma. *Invest Ophthalmol Vis Sci* 43:912–918, 2002.
- 

22. Frank RN: Diabetic retinopathy. *N Engl J Med* 350:48–58, 2004.
23. Pe'er J, Folberg R, Itin A, Gnessin H, Hemo I, Keshet E: Upregulated expression of vascular endothelial growth factor in proliferative diabetic retinopathy. *Br J Ophthalmol* 80:241–245, 1996.
24. Tolentino MJ, McLeod DS, Taomoto M, Otsuji T, Adamis AP, Litty GA: Pathologic features of vascular endothelial growth factor-induced retinopathy in the nonhuman primate. *Am J Ophthalmol* 133:373–385, 2002.
25. Pe'er J, Shweiki D, Itin A, Hemo I, Gnessin H, Keshet E: Hypoxia-induced expression of vascular endothelial growth factor by retinal cells is a common factor in neovascularizing ocular diseases. *Lab Invest* 72:638–645, 1995.
26. Mechoulam H, Pierce E: Retinopathy of prematurity: molecular pathology and therapeutic strategies. *Am J Pharmacogenomics* 3:261–277, 2003.

27. Romayananda N, Goldberg MF: Histopathology of sickle cell retinopathy. *Trans Am Acad Ophthalmol Otolaryngol* 77:652–676, 1973.
28. Cao J, Mathews MK, McLeod DS, Merges C, Hjelmeland LM, Luty GA: Angiogenic factors in human proliferative sickle cell retinopathy. *Br J Ophthalmol* 83:838–846, 1999.
29. Kim SY, Mocanu C, McLeod DS, et al: Expression of pigment epithelium-derived factor (PEDF) and vascular endothelial growth factor (VEGF) in sickle cell retina and choroid. *Exp Eye Res* 77:433–445, 2003.
30. Hayreh SS: So-called "central retinal vein occlusion." Part I: Pathogenesis, terminology, clinical features. *Ophthalmologica* 172:1–13, 1976.
31. Pe'er J, Folberg R, Itin A, Gnessin H, Hemo I, Keshet E: Vascular endothelial growth factor upregulation in human central retinal vein occlusion. *Ophthalmology* 105:412–416, 1998.
32. Hyman L, Neborsky R: Risk factors for age-related macular degeneration: an update. *Curr Opin Ophthalmol* 13:171–175, 2002;
33. Bird AC: The Bowman lecture: towards an understanding of age-related macular disease. *Eye* 17:457–466, 2003.
34. Pfohler C, Haus A, Palmowski A, et al: Melanoma-associated retinopathy: high frequency of subclinical findings in patients with melanoma. *Br J Dermatol* 149:74–78, 2003.
35. Rivolta C, Sharon D, DeAngelis MM, Dryja TP: Retinitis pigmentosa and allied diseases: numerous diseases, genes, and inheritance patterns. *Hum Mol Genet* 11:1219–1227, 2002.
36. Marcus DM, Brooks SE, Leff G, et al: Trilateral retinoblastoma: insights into histogenesis and management. *Surv Ophthalmol* 43:59–70, 1998.
37. Margo C, Hidayat A, Kopelman J, Zimmerman LE: Retinocytoma: a benign variant of retinoblastoma. *Arch Ophthalmol* 101:1519–1531, 1983.
38. Hayreh SS: Anterior ischemic optic neuropathy. *Clin Neurosci* 4:251–263, 1997.
39. Tso MO, Hayreh SS: Optic disc edema in raised intracranial pressure. Part IV: axoplasmic transport in experimental papilledema. *Arch Ophthalmol* 95:1458–1462, 1977.
40. Tso MO, Hayreh SS: Optic disc edema in raised intracranial pressure. Part IV: axoplasmic transport in experimental papilledema. *Arch Ophthalmol* 95:1458–1462, 1977.
41. Wiggs JL, Auguste J, Allingham RR, et al: Lack of association of mutations in optineurin with disease in patients with adult-onset primary open-angle glaucoma. *Arch Ophthalmol* 121:1181–1183, 2003.
42. Wax MB, Tezel G: Neurobiology of glaucomatous optic neuropathy: diverse cellular events in neurodegeneration and neuroprotection. *Mol Neurobiol* 26:45–55, 2002.
43. Schwartz M: Neurodegeneration and neuroprotection in glaucoma: development of a therapeutic neuroprotective vaccine: the Friedenwald lecture. *Invest Ophthalmol Vis Sci* 44:1407–1411, 2003.
44. Howell N: Leber hereditary optic neuropathy: respiratory chain dysfunction and degeneration of the optic nerve. *Vision Res* 38:1495–1504, 1998.
45. Sadun A: Acquired mitochondrial impairment as a cause of optic nerve disease. *Trans Am Ophthalmol Soc* 96:881–923, 1998.
46. Beck RW, Trobe JD, Moke PS, et al: High- and low-risk profiles for the development of multiple sclerosis within 10 years after optic neuritis: experience of the optic neuritis treatment trial. *Arch Ophthalmol* 121:944–949, 2003.

