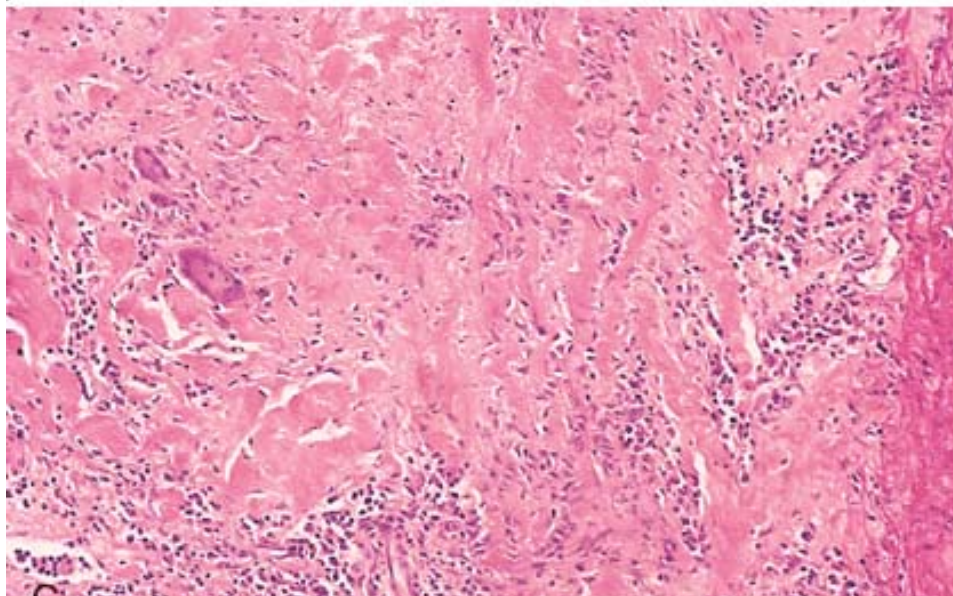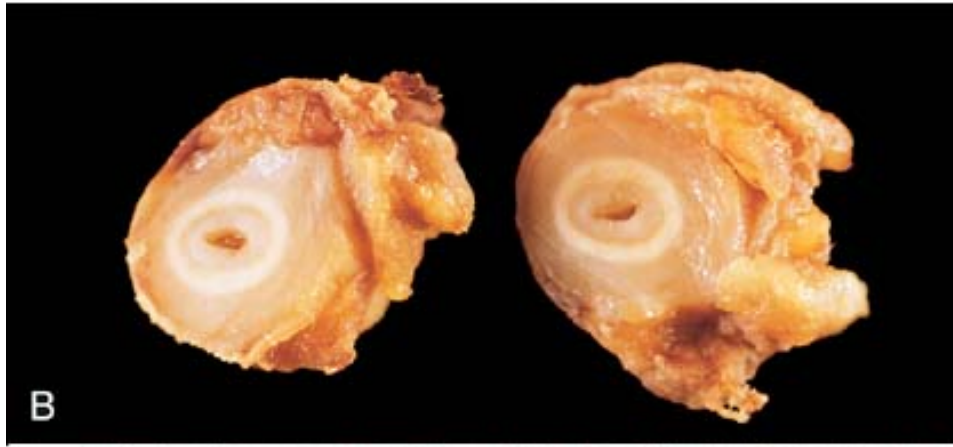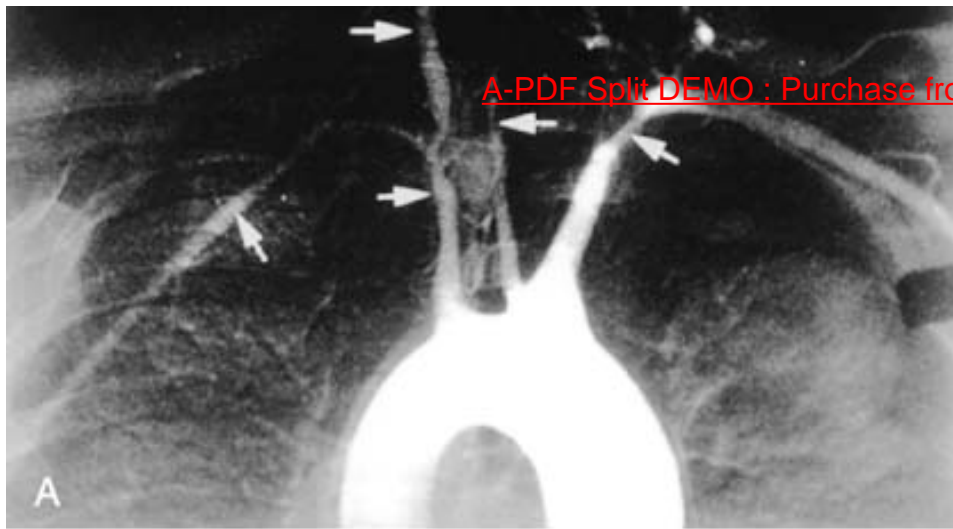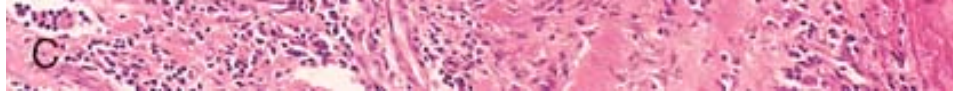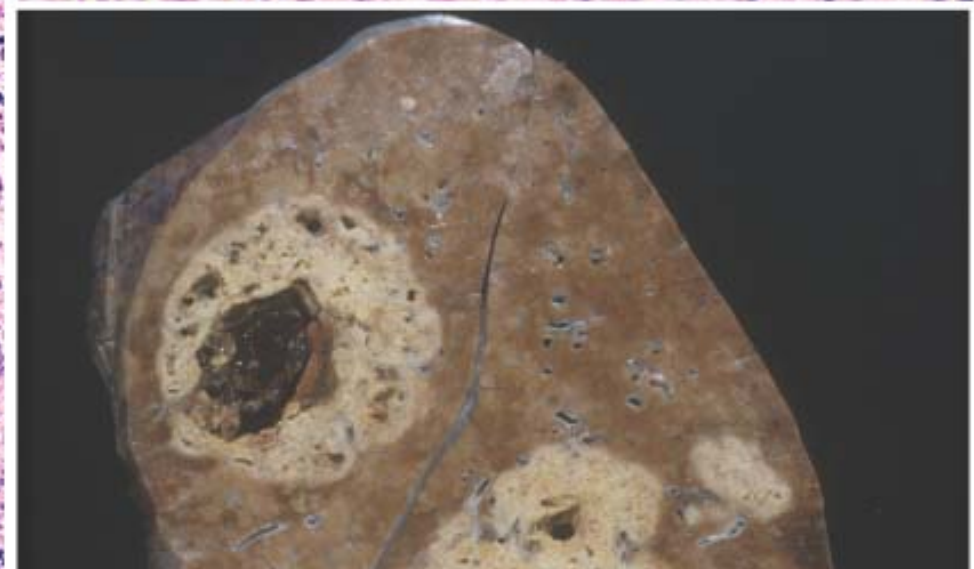
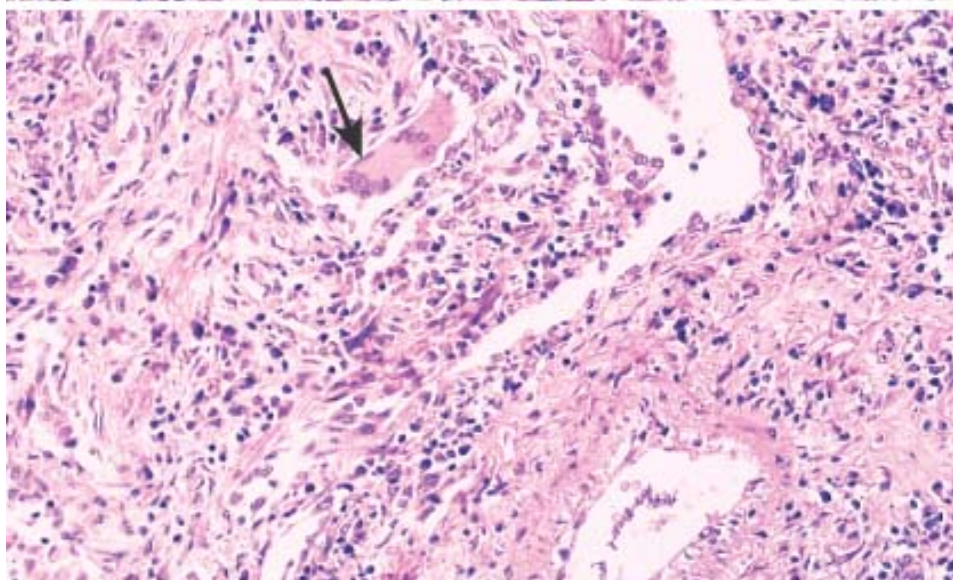
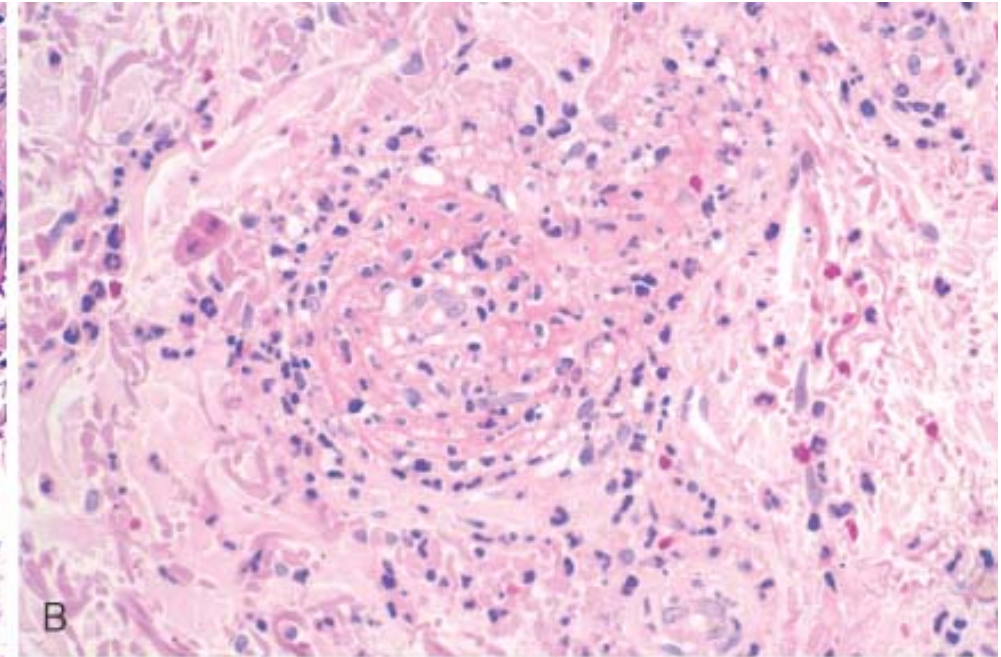
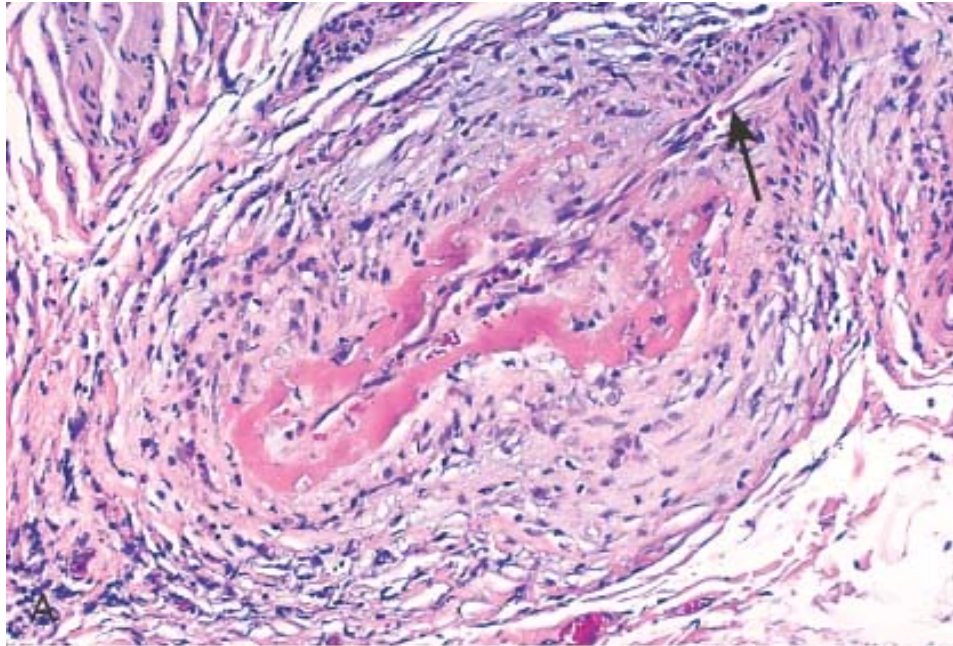


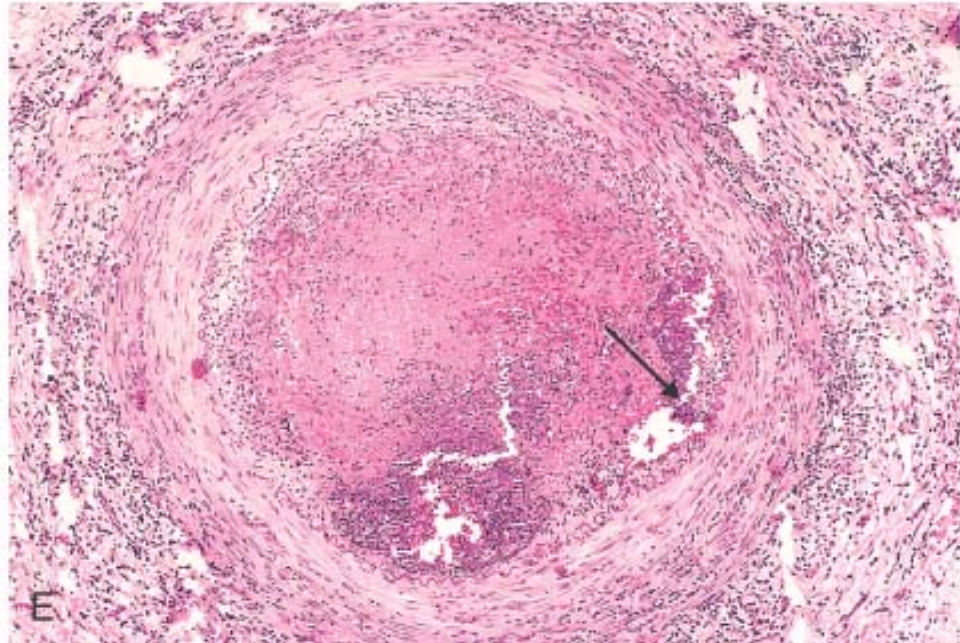
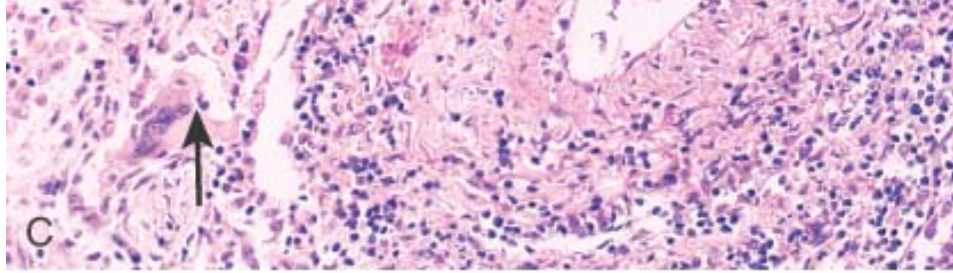




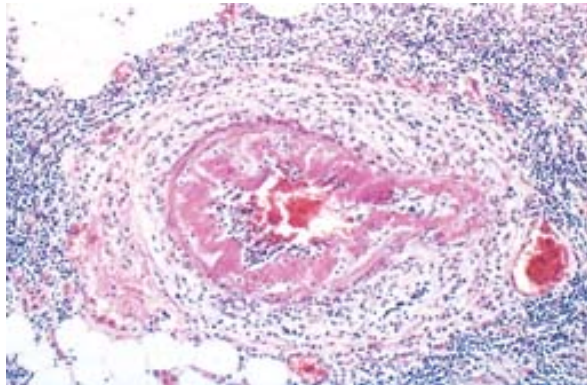
**Figure 11-26** Representative forms of systemic medium-sized to small vessel vasculitis. *A*, Polyarteritis nodosa. *B*, Leukocytoclastic vasculitis. *C* and *D*, Wegener granulomatosis. *E*, Thromboangiitis obliterans (Buerger disease). In polyarteritis nodosa (*A*), there is segmental fibrinoid necrosis and thrombotic occlusion of the lumen of this small artery. Note that part of the vessel wall at the upper right (*arrow*) is uninvolved. In leukocytoclastic vasculitis (*B*), shown here from a skin biopsy, there is fragmentation of neutrophils in and around blood vessel walls. In Wegener granulomatosis (*C*), there is inflammation (vasculitis) of a small artery along with adjacent granulomatous inflammation, in which epithelioid cells and giant cells (*arrows*) are seen. *D*, Gross photo from the lung of a patient with fatal Wegener granulomatosis, demonstrating large nodular lesions. In a typical case of Buerger disease (*E*), the lumen is occluded by a thrombus containing two abscesses (*arrow*). The vessel wall is infiltrated with leukocytes. (*A*, and *D*, courtesy of Sidney Murphree, MD, Department of Pathology, University of Texas Southwestern Medical School, Dallas, TX; *B*, courtesy of Scott Granter, M.D., Brigham and Women's Hospital, Boston.)



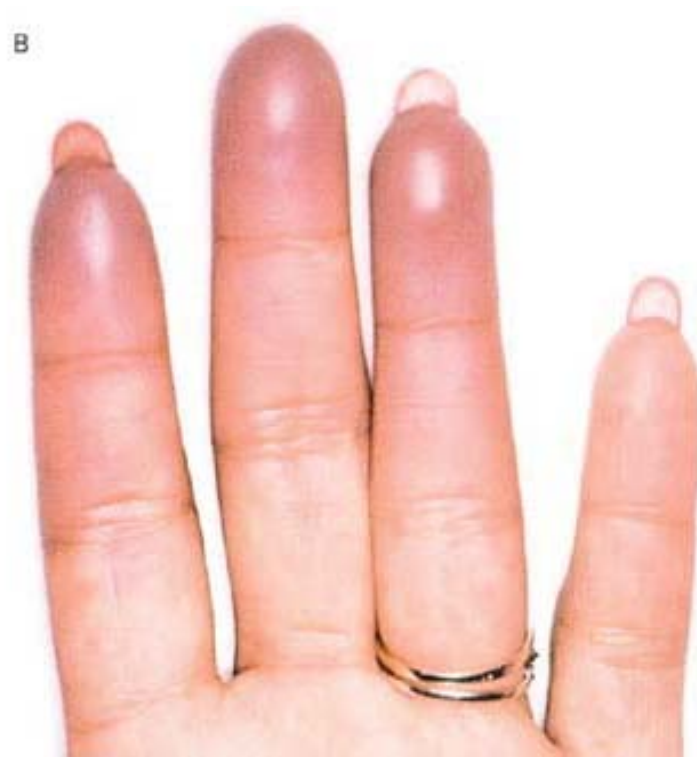
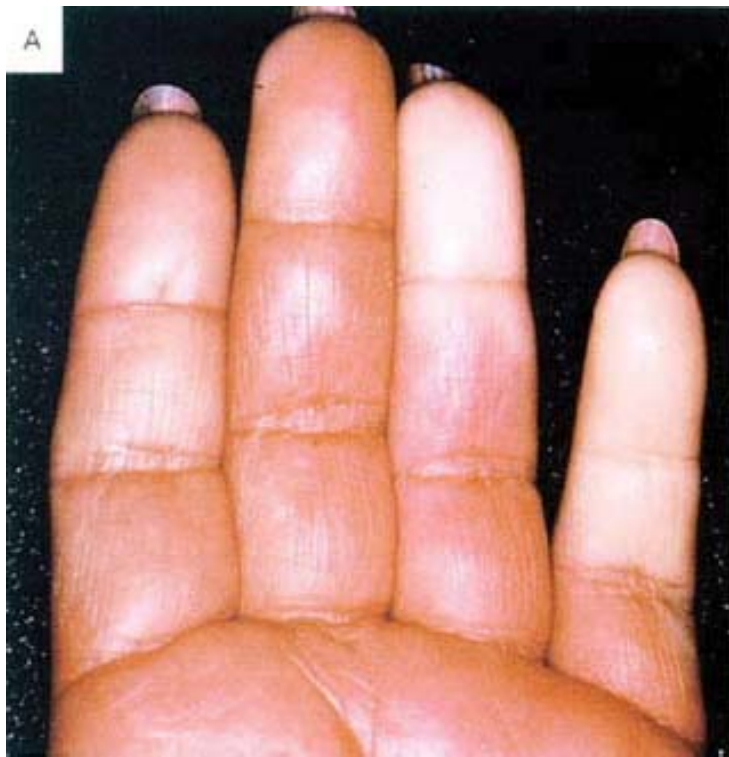


**Figure 11-27** Vasculitis with fibrinoid necrosis in a patient with active systemic lupus erythematosus.



**Figure 11-28** Raynaud phenomenon. *A*, Sharply demarcated pallor of the distal fingers resulting from the closure of digital arteries. *B*, Cyanosis of the fingertips. (Reproduced from Salvarani C, et al.: *Polymyalgia rheumatica and giant-cell arteritis*. *N Engl J Med* 347:261, 2002.)



**TABLE 11-6 -- Classification of Vascular Tumors and Tumor-Like Conditions**

<i><b>Benign Neoplasms, Developmental and Acquired Conditions</b></i>
Hemangioma
••Capillary hemangioma
••Cavernous hemangioma
••Pyogenic granuloma (lobular capillary hemangioma)
Lymphangioma
••Simple (capillary) lymphangioma
••Cavernous lymphangioma (cystic lymphangioma)
Glomus tumor
Vascular ectasias
••Nevus flammeus
••Spider telangiectasia (arterial spider)
••Hereditary hemorrhagic telangiectasis (Osler-Weber-Rendu disease)

Reactive vascular proliferations
••Bacillary angiomatosis
<b><i>Intermediate-Grade Neoplasms</i></b>
Kaposi sarcoma
Hemangioendothelioma
<b><i>Malignant Neoplasms</i></b>
Angiosarcoma
Hemangiopericytoma

The endothelial derivation of neoplastic proliferations that do not form distinct vascular lumina can usually be confirmed by immunohistochemical demonstration of endothelium-specific markers such as CD31, CD34, or vWF. Because these lesions constitute abnormalities of unregulated vascular proliferation, the possibility of controlling such growth by agents that inhibit blood vessel formation (anti-angiogenic factors) is particularly exciting.

## BENIGN TUMORS AND TUMOR-LIKE CONDITIONS

### Hemangioma

Difficult to distinguish with certainty from malformations or hamartomas, *hemangiomas* (*angiomas*) are most commonly localized; however, some involve large segments of the body such as an entire extremity (called *angiomatosis*). The majority are superficial lesions, often of the head or neck, but they may occur internally, with nearly one third in the liver. Malignant transformation occurs rarely if at all ( Fig. 11-30 ).

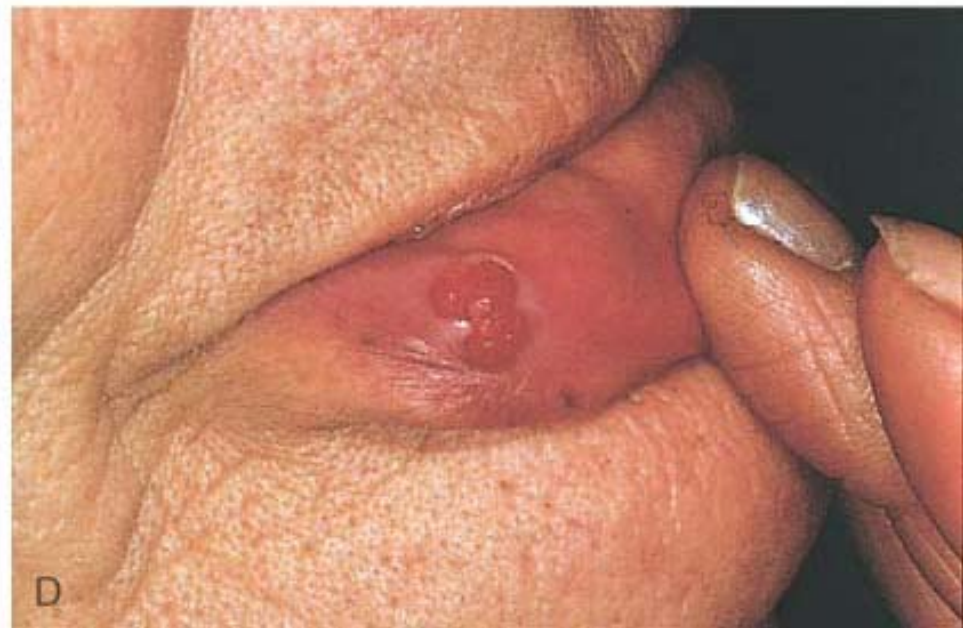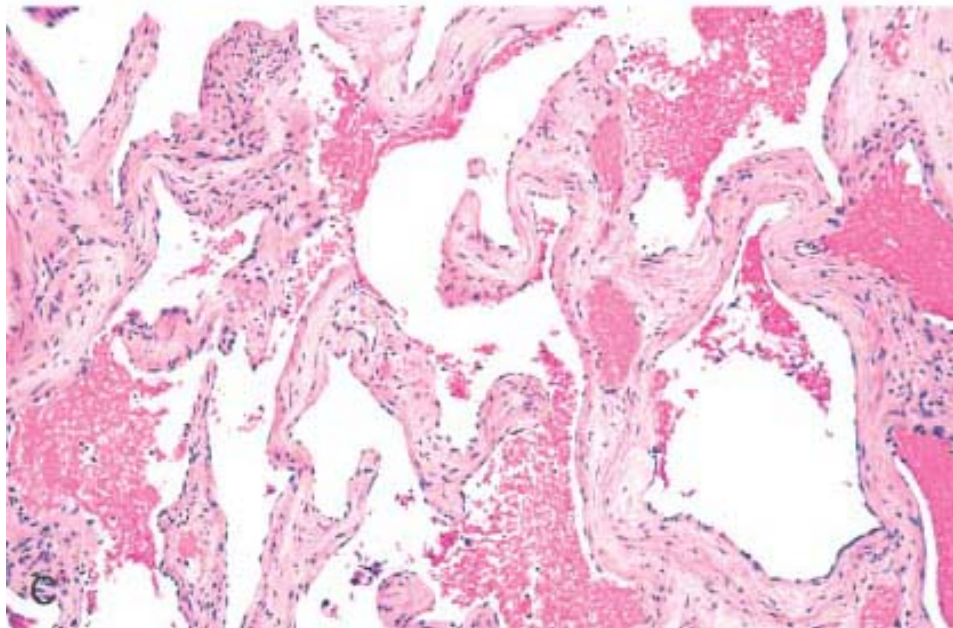
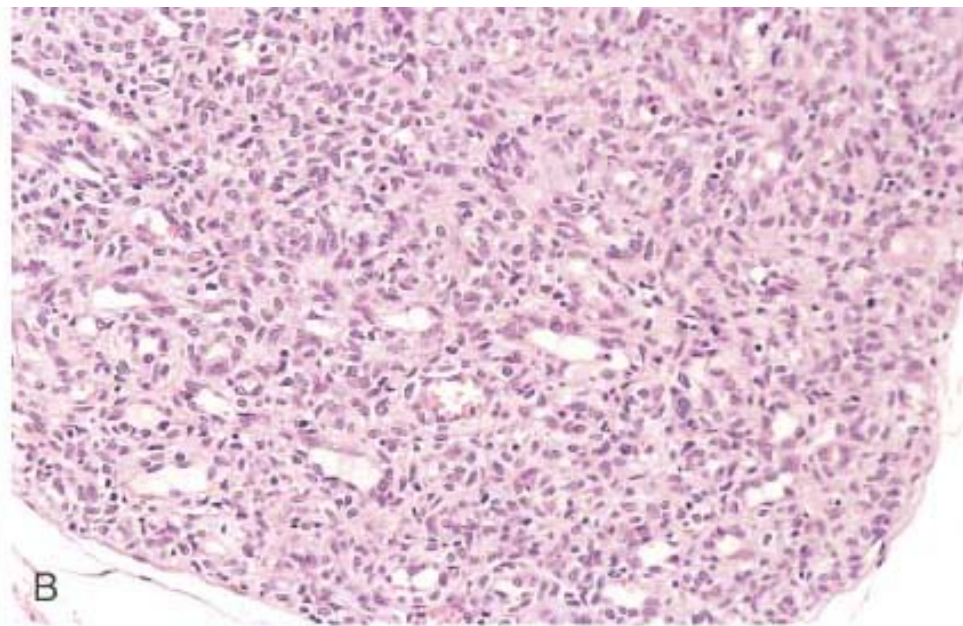
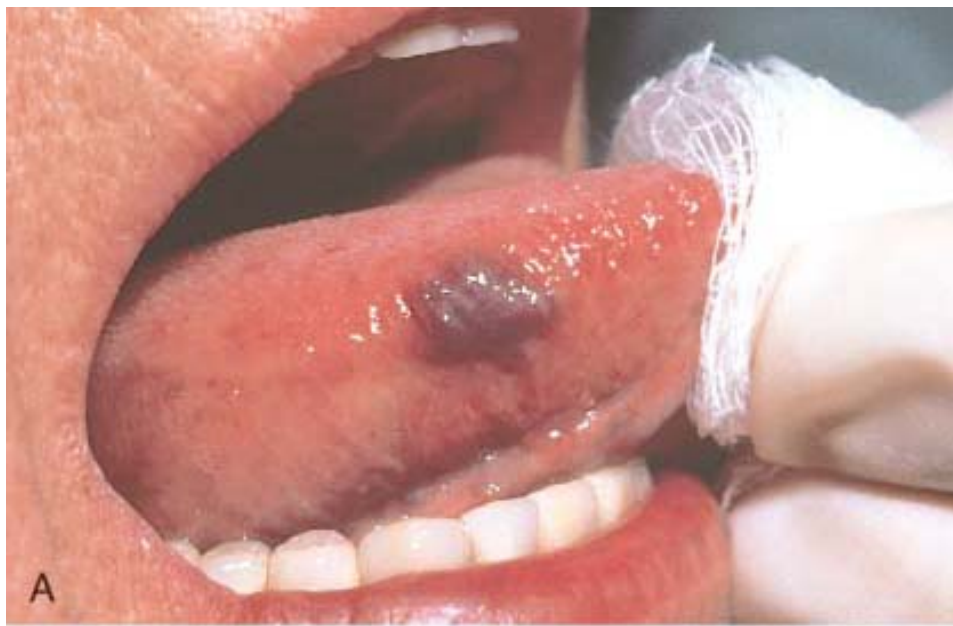Hemangiomas constitute 7% of all benign tumors in infancy and childhood ( Chapter 10 ). Most are present from birth and expand along with the growth of the child. Nevertheless, many of the capillary lesions regress spontaneously at or before puberty. There are several histologic and clinical variants.

### Capillary Hemangioma.

*Capillary hemangiomas*, the largest single type of vascular tumor, are most common in the skin, subcutaneous tissues, and mucous membranes of the oral cavities and lips, but they may also occur in the liver, spleen, and kidneys. The "strawberry type" of capillary hemangioma (*juvenile hemangioma*) of the skin of newborns is extremely common (1 in 200 births), may be multiple, grows rapidly in the first few months, begins to fade when the

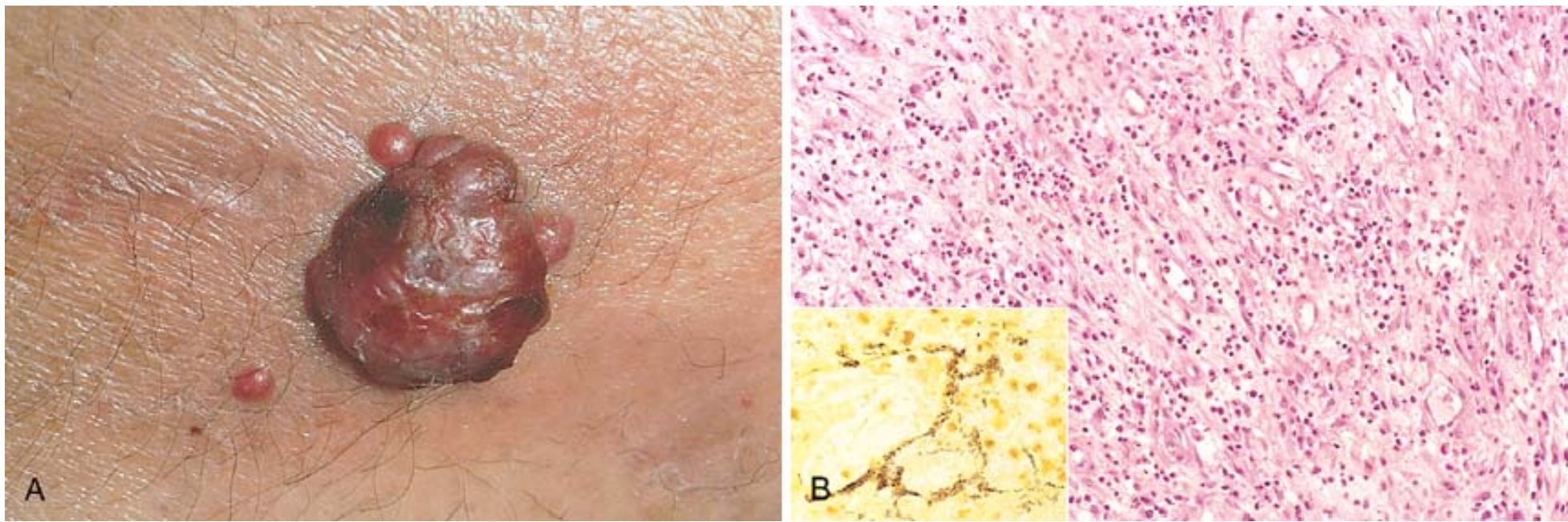
**Figure 11-30** Hemangiomas. *A*, Hemangioma of the tongue. *B*, Histology of juvenile capillary hemangioma. *C*, Histology of cavernous hemangioma. *D*, Pyogenic granuloma of the lip. (*A* and *D*, courtesy of John Sexton, M.D., Beth Israel Hospital, Boston; *B*, courtesy of Christopher D.M. Fletcher, M.D., Brigham and Women's Hospital, Boston; and *C*, courtesy of Thomas Rogers, M.D., University of Texas Southwestern Medical School, Dallas, TX.)



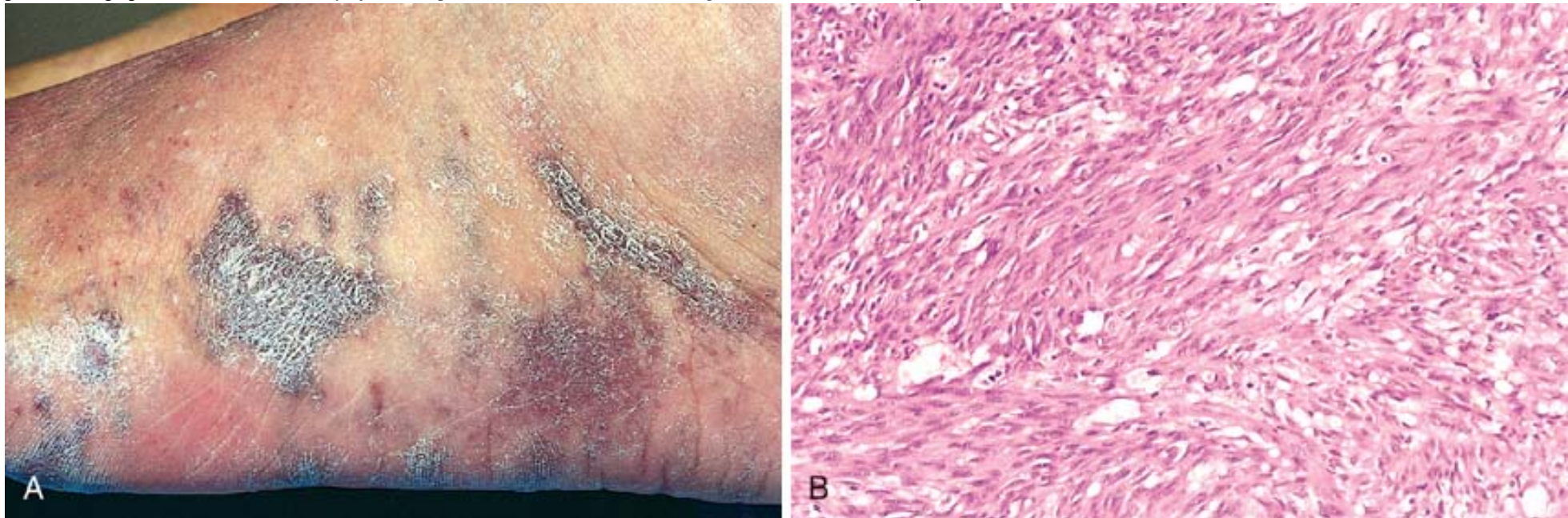


**Figure 11-31** Bacillary angiomatosis. *A*, Photograph of a moist, erosive cutaneous lesion. *B*, Histologic appearance with acute neutrophilic inflammation and vascular (capillary) proliferation. *Inset*, demonstration by modified silver (Warthin-Starry) stain of clusters of tangled bacilli (black). (*A*, courtesy of Richard Johnson, M.D. Beth Israel Deaconess Medical Center, Boston, MA; *B* and *inset*, courtesy of Scott Granter, M.D., Brigham and Women's Hospital, Boston, MA.)



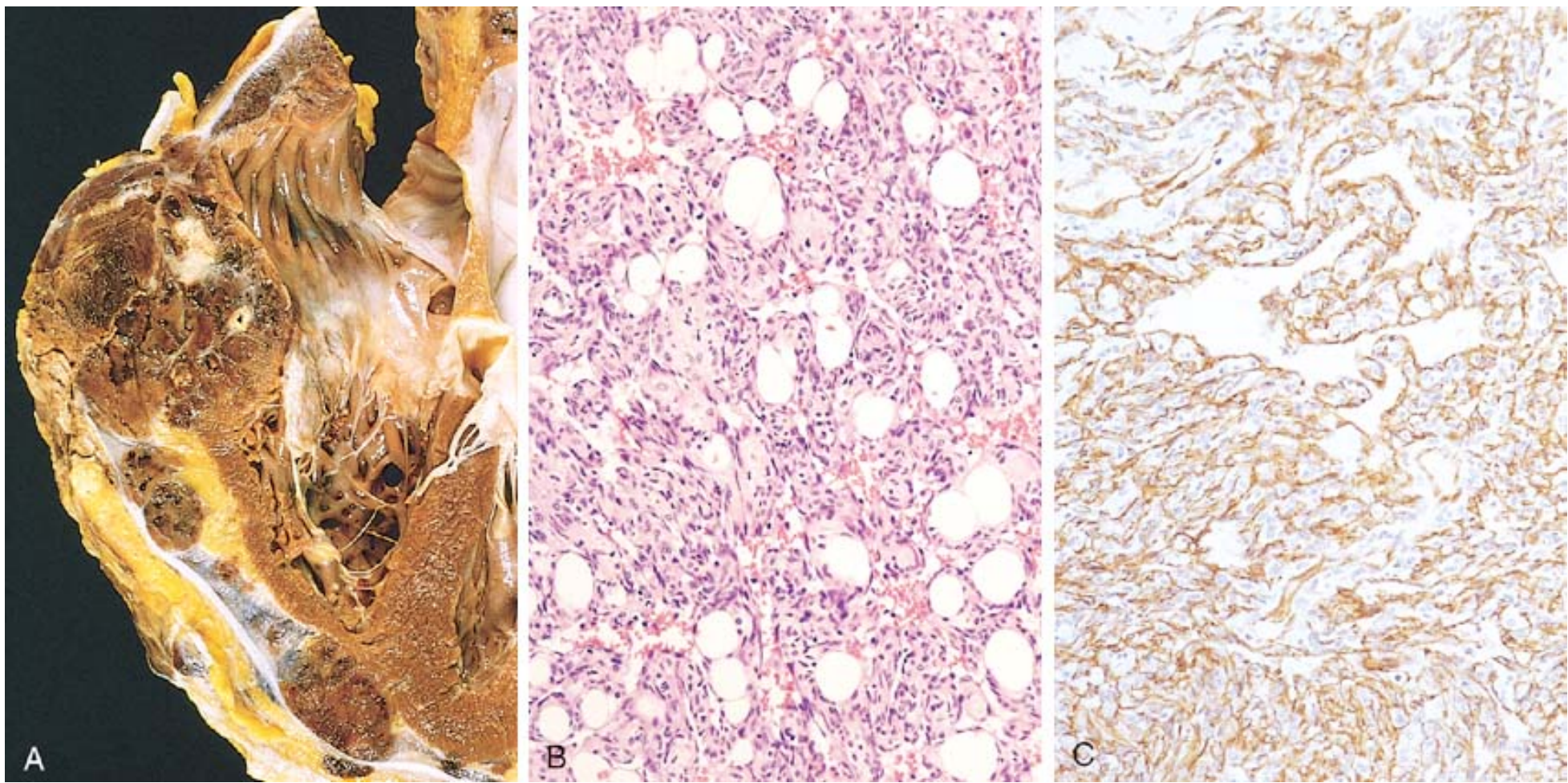


**Figure 11-32** Kaposi sarcoma. *A*, Gross photograph, illustrating coalescent red-purple macules and plaques of the skin. *B*, Histology of nodular form, demonstrating sheets of plump, proliferating spindle cells. (*B*, courtesy of Christopher D.M. Fletcher, M.D., Brigham and Women's Hospital, Boston, MA.)



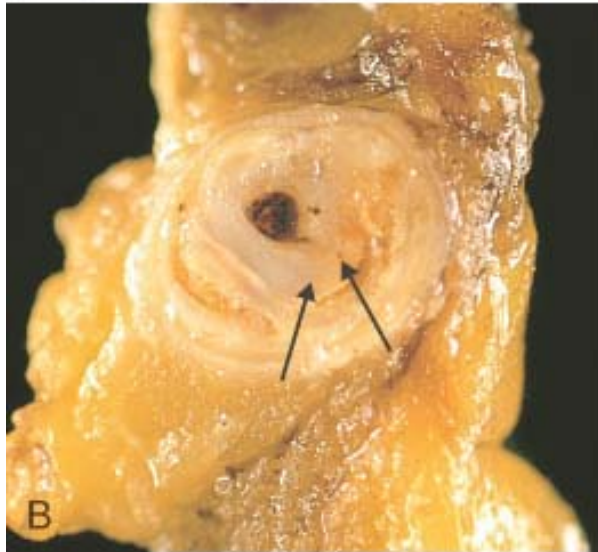
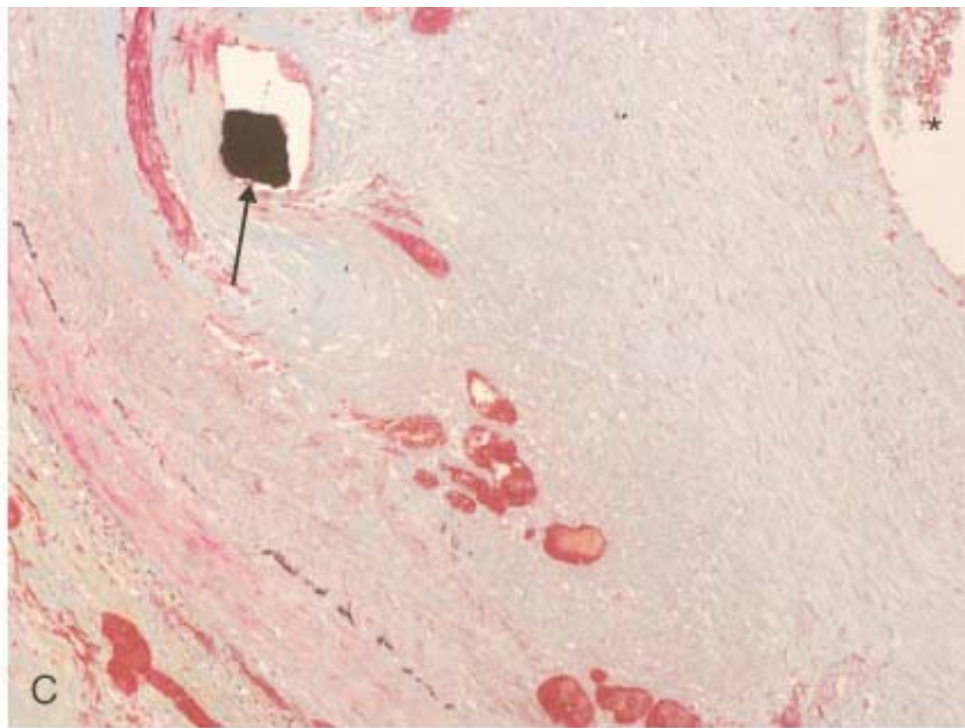
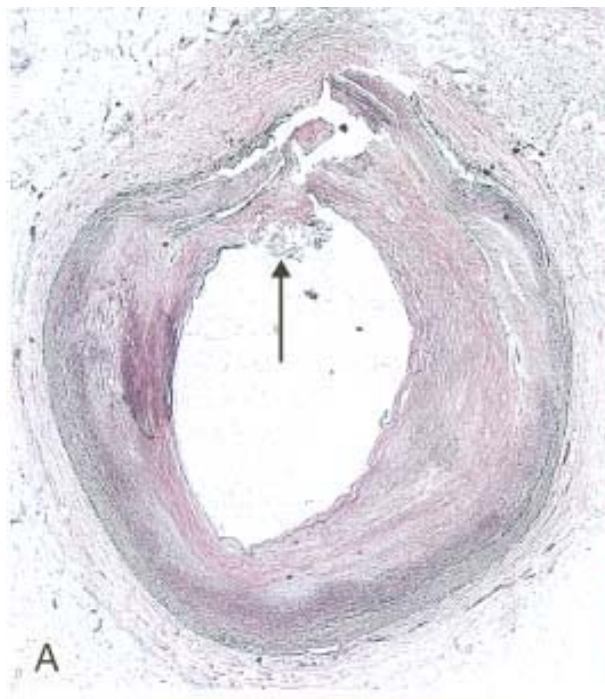
**Figure 11-33** Angiosarcoma. *A*, Gross photograph of angiosarcoma of the heart (right ventricle). *B*, Photomicrograph of moderately well-differentiated angiosarcoma with dense clumps of irregular, moderate anaplastic cells and distinct vascular lumens. *C*, Positive immunohistochemical staining of angiosarcoma for the endothelial cell marker CD31, proving the endothelial nature of the tumor cells.





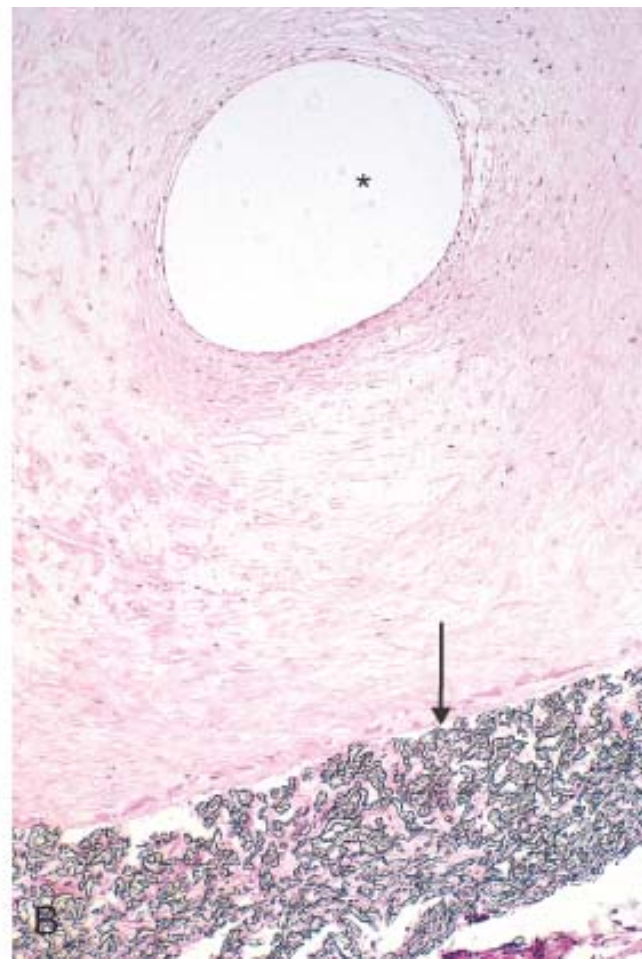
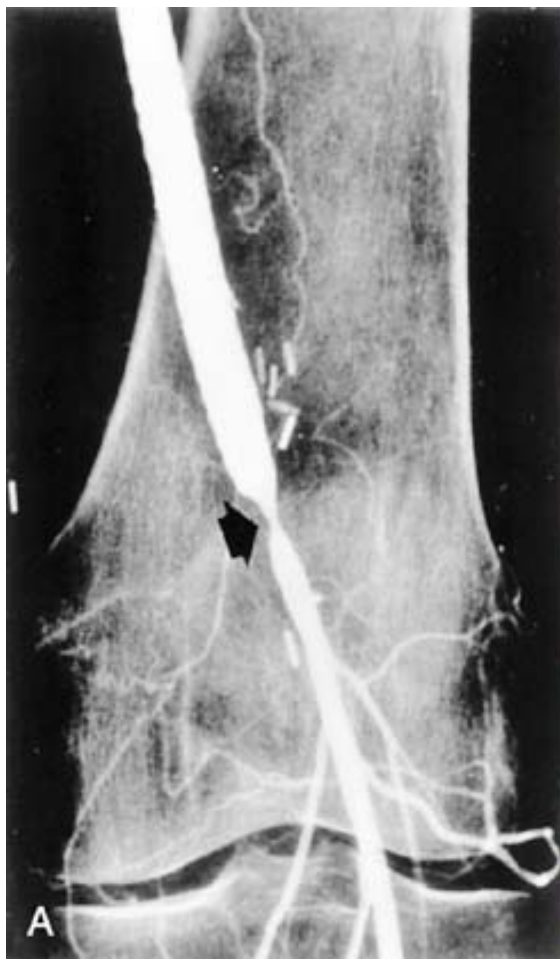**Figure 11-34** Balloon angioplasty and endovascular stents. *A*, Coronary artery with recent balloon angioplasty, in a low-power photomicrograph showing the split encompassing the intima and media (*arrow*) and partial circumferential dissection. *B*, Gross photograph of restenosis following balloon angioplasty, demonstrating residual atherosclerotic plaque (*left arrow*) and a new, glistening proliferative lesion (*right arrow*). *C*, Coronary arterial stent implanted long term, demonstrating thickened neointima separating the stent wires (black spot shown by *arrow*) from the lumen (*asterisk*). (*C*, Reproduced from Schoen FJ, Edwards WD. *Pathology of cardiovascular interventions, including endovascular therapies, revascularization, vascular replacement, cardiac assist/replacement, arrhythmia control, and repaired congenital heart disease*. In Silver MD, Gotlieb AI, Schoen FJ (eds): *Cardiovascular Pathology*, 3rd ed. Philadelphia, Churchill Livingstone, 2001.)





**Figure 11-35** Anastomotic hyperplasia at the distal anastomosis of synthetic femoropopliteal graft. *A*, Angiogram demonstrating constriction (*arrow*). *B*, Photomicrograph demonstrating Gore-Tex graft (*arrow*) with prominent intimal proliferation and very small residual lumen (*asterisk*). (*A*, courtesy of Anthony D. Whittemore, M.D., Brigham and Women's Hospital, Boston, MA.)





## References

1. Carmeliet P, Jain RK: Angiogenesis in cancer and other diseases. *Nature* 407:249, 2000.
2. Shin D, et al: Expression of ephrin-B2 identifies a stable genetic difference between arterial and venous vascular smooth muscle as well as endothelial cells, and marks subsets of microvessels at sites of adult neovascularization. *Dev Biol* 230:139, 2001.
3. Karkkainen MJ, et al: Lymphatic endothelium: a new frontier of metastasis research. *Nat Cell Biol* 4:E2, 2002.
4. Garcia-Cardena G, et al: Biomechanical activation of vascular endothelium as a determinant of its functional phenotype. *Proc Nat Acad Sci USA* 98:4478, 2001.
5. Stevens T, et al: NHLBI workshop report: endothelial cell phenotypes in heart, lung and blood diseases. *Am J Physiol Cell Physiol* 281:C1422, 2001.
6. Berk BC: Vascular smooth muscle growth: autocrine growth mechanisms. *Physiol Rev* 81:999, 2001.
7. Carmeliet P: Mechanisms of angiogenesis and arteriogenesis. *Nat Med* 6:389, 2000.
8. Yancopoulos GD, et al: Vascular-specific growth factors and blood vessel formation. *Nature* 407:242, 2000.



9. Shin JT, Fishman MC: From zebrafish to humans: modular medical models. *Annu Rev Genomics Hum Genet* 3:311, 2002.
10. Folkman J: Angiogenesis-dependent diseases. *Semin Oncol* 28:536, 2001.
11. Folkman J, et al: Angiogenesis research: guidelines for translation to clinical application. *Thromb Haemost* 86:23, 2001.
12. Angelini P, et al: Coronary anomalies: incidence, pathophysiology, and clinical relevance. *Circulation* 105:2449, 2002.
13. Fleetwood IG, Steinberg GK: Arteriovenous malformations. *Lancet* 359:863, 2002.
14. Sary HC, et al: A definition of advanced types of atherosclerotic lesions and a histological classification of atherosclerosis. *Circulation* 92:1355, 1995.
15. Komatsu A, Sakurai I: A study of the development of atherosclerosis in childhood and young adults: risk factors and the prevention of progression in Japan and the USA. The Pathological Determinants of Atherosclerosis in Youth (PDAY) Research Group. *Pathol Intern* 46:541, 1996.
16. Kannel WB, Wilson PWF: An update on coronary risk factors. *Med Clin North Am* 79:951, 1995.
17. Ridker PM, et al: Risk factors for atherosclerotic disease. In Braunwald E, Zipes DP, Libby P (eds): *Heart Disease*, 6th ed. Philadelphia, WB Saunders Co., 2001, p. 1010–1039.
18. Glass CK, Witztum JL: Atherosclerosis: the road ahead. *Cell* 104:503, 2001.
19. Libby P: The vascular biology of atherosclerosis. In Braunwald E, Zipes DP, Libby P (eds): *Heart Disease*, 6th ed. Philadelphia, WB Saunders Co., 2001, p. 995–1009.
20. Lusis AJ: Atherosclerosis. *Nature* 407:233, 2000.
21. Gimbrone MA Jr, et al: Endothelial dysfunction, hemodynamic forces, and atherogenesis. *Ann NY Acad Sci* 902:239, 2000.
22. Berk BC, et al: Endothelial atheroprotective and anti-inflammatory mechanisms. *Ann NY Acad Sci* 947:93, 2001.
23. Ross R: Atherosclerosis—an inflammatory disease *N Engl J Med* 340:115, 1999.
24. Libby P, et al: Inflammation and atherosclerosis. *Circulation* 105:1135, 2002.
25. Breslow JL: Genetics of lipoprotein abnormalities associated with coronary artery disease susceptibility. *Annu Rev Genet* 34:233, 2000.
26. Reardon CA, Getz GS: Mouse models of atherosclerosis. *Curr Opin Lipidol* 12:167, 2001.
27. Geng Y-J, Libby P: Progression of atheroma: a struggle between death and procreation. *Arterioscler Thromb Vasc Biol* 22:1370, 2002.
28. Benditt EP: Implications of the monoclonal character of human atherosclerotic plaques. *Am J Pathol* 86:693, 1977.
29. Chung IM, et al: Clonal architecture of normal and atherosclerotic aorta: implications for atherogenesis and vascular development. *Am J Pathol* 152:913, 1998.
30. O'Connor S, et al: Potential infectious etiologies of atherosclerosis: a multifactorial perspective. *Emerg Infect Dis* 7:780, 2001.
31. Streblov DN, et al: Do pathogens accelerate atherosclerosis? *J Nutr* 131:2798S, 2001.
32. Lifton RP, et al: Molecular mechanisms of human hypertension. *Cell* 104:545, 2001.
33. Hingorani AD, Brown MJ: Identifying the genes for human hypertension. *Nephrol Dial Transplant* 11:575, 1996.



34. Kannel WB: Elevated systolic blood pressure as a cardiovascular risk factor. *Am J Cardiol* 85:251, 2000.
35. Hyman DJ, Pavlik VN: Characteristics of patients with uncontrolled hypertension in the United States. *N Engl J Med* 345:479, 2002.
36. Kaplan NM: Systemic hypertension: mechanisms and diagnosis. In Braunwald E, Zipes DP, Libby P (eds): *Heart Disease*, 6th ed. Philadelphia, WB Saunders Co., 2001, p. 941–971.
37. Corti R, et al: Vasoepitidase inhibitors: a new therapeutic concept in cardiovascular disease? *Circulation* 104:1856, 2001.
38. Thibonnier M, Schork NJ: The genetics of hypertension. *Curr Opin Genet Develop* 5:362, 1995.
39. Beckman JA, O'Gara PT: Diseases of the aorta. *Adv Int Med* 44:267, 1999.
40. Ernst CB: Abdominal aortic aneurysm. *N Engl J Med* 328:1167, 1993.
41. Curci JA, et al: Expression and localization of macrophage elastase (matrix metalloproteinase-12) in abdominal aortic aneurysms. *J Clin Invest* 102:1900, 1998.
42. Yoon S, et al: Genetic analysis of MMP3, MMP9, and PAI-1 in Finnish patients with abdominal aortic or intracranial aneurysms. *Biochem Biophys Res Commun* 265:563, 1999.
43. Carrell TWG, et al: Stromelysin-1 (matrix metalloproteinase-3) and tissue inhibitor of metalloproteinase-3 are overexpressed in the wall of abdominal aortic aneurysms. *Circulation* 105:477, 2001.
44. Knox J, et al: Evidence for altered balance between matrix metalloproteinases and their inhibitors in human aortic diseases. *Circulation* 95:205, 1997.
45. Hallett JW Jr: Management of abdominal aortic aneurysms. *Mayo Clin Proc* 75:395, 2000.
46. Arko FR, et al: Endovascular stent-grafts for the repair of infrarenal abdominal aortic aneurysms: a brief review. *J Interv Cardiol* 14:475, 2001.
47. Najibi S, et al: Endovascular aortic aneurysm operations. *Arch Surg* 137:211, 2002.
48. Khan IA, Nair CK: Clinical, diagnostic, and management perspectives of aortic dissection. *Chest* 122:311, 2002.
49. Jennette JC, Falk RJ: Small-vessel vasculitis. *N Engl J Med* 337:1512, 1997.
50. Cuellar ML: Drug-induced vasculitis. *Curr Rheumatol Rep* 4:55, 2002.
51. Fransson CFM, et al: Antiproteinase 3 and antimyeloperoxidase associated vasculitis. *Kidney Internat* 57:2195, 2000.
52. Savige J, et al: Antineutrophil cytoplasmic antibodies and associated diseases: a review of the clinical and laboratory features. *Kidney Internat* 57:846, 2000.
53. Harper L, Savage COS: Leukocyte-endothelial interactions in antineutrophil cytoplasmic antibody-associated systemic vasculitis. *Rheum Dis Clin North Am* 27:887, 2001.



55. Gran JT: Some thoughts about the etiopathogenesis of temporal arteritis—a review. *Scand J Rheumatol* 31:1, 2002.
56. Fraga A, Medina F: Takasayu's arteritis. *Curr Rheumatol Rep* 4:30, 2002.
57. Hughes LB, Bridges SL Jr: Polyarteritis nodosa and microscopic polyangiitis: etiologic and diagnostic considerations. *Curr Rheumatol Rep* 4:75, 2002.
58. Gedalia A: Kawasaki disease: an update. *Curr Rheumatol Rep* 4:25, 2002.
59. Freeman AF, Shulman ST: Recent developments in Kawasaki disease. *Curr Opin Infect Dis* 14:357, 2001.
60. Koutkia P, et al: Leucocytoclastic vasculitis: an update for the clinician. *Scand J Rheumatol* 30:315, 2001.
61. Gross W: Churg-Strauss syndrome: update on recent developments. *Curr Opin Rheumatol* 14:11, 2002.
62. Churg A: Recent advances in the Churg-Strauss syndrome. *Mod Pathol* 14:1284, 2001.
- 62A. Olin JW: Thromboangitis obliterans. *N Engl J Med* 343:864, 2004.
63. Golan TD: Lupus vasculitis: differential diagnosis with antiphospholipid syndrome. *Curr Rheumatol Rep* 4:18, 2002.
64. Wigley FM: Raynaud's phenomenon. *N Engl J Med* 347:1001, 2002.
65. Antman K, Chang Y: Kaposi's sarcoma. *N Engl J Med* 342:1027, 2000.
66. Chang Y, et al: Identification of herpesvirus-like DNA sequences in AIDS-associated Kaposi's sarcoma. *Science* 266:1865, 1994.
67. Ensoli B, et al: Reactivation and role of HHV-8 in Kaposi sarcoma initiation. *Adv Cancer Res* 81:161, 2001.
68. Boshoff C, Weiss R: AIDS-related malignancies. *Nature Rev Cancer* 2:373, 2002.
69. Regar E, et al: Stent development and local drug delivery. *Br Med Bull* 59:227, 2001.
70. Lowe HC, et al: Coronary in-stent restenosis: current status and future strategies. *J Am Coll Cardiol* 39:183, 2002.
71. Schoen FJ, Edwards WD: Pathology of cardiovascular interventions, including endovascular therapies, revascularization, vascular replacement, cardiac assist/replacement, arrhythmia control and repaired congenital heart disease. In Silver MD, Gotlieb AI, Schoen FJ (eds): *Cardiovascular Pathology*. Philadelphia, Churchill Livingstone, 2001, p. 678.
72. Safian RD: Accelerated atherosclerosis in saphenous vein bypass grafts: a spectrum of diffuse plaque instability. *Prog Cardiovasc Dis* 44:437, 2002.

The human heart is a remarkably efficient, durable, and reliable pump that propels over 6000 liters of blood through the body daily and beats more than 40 million times a year during an individual's lifetime, thereby providing the tissues with a steady supply of vital nutrients and facilitating the excretion of waste products. As might be anticipated, cardiac dysfunction can be associated with devastating physiologic consequences. Heart disease is the predominant cause of disability and death in industrialized nations. In the United States, it accounts for about 40% of all postnatal deaths, totaling about 750,000 individuals annually and nearly twice the number of deaths caused by all forms of cancer combined. The yearly economic burden of ischemic heart disease, the most prevalent subgroup, is estimated to be in excess of \$100 billion. The major categories of cardiac diseases considered in this chapter include congenital heart abnormalities, ischemic heart disease, heart disease caused by systemic hypertension, heart disease caused by pulmonary diseases (cor pulmonale), diseases of the cardiac valves, and primary myocardial diseases. A few comments about pericardial diseases and cardiac neoplasms as well as cardiac transplantation are also offered. Before considering details of specific conditions, we will review salient features of normal anatomy and function as well as the principles of cardiac hypertrophy and failure, the common end points of many different types of heart disease.

## Normal

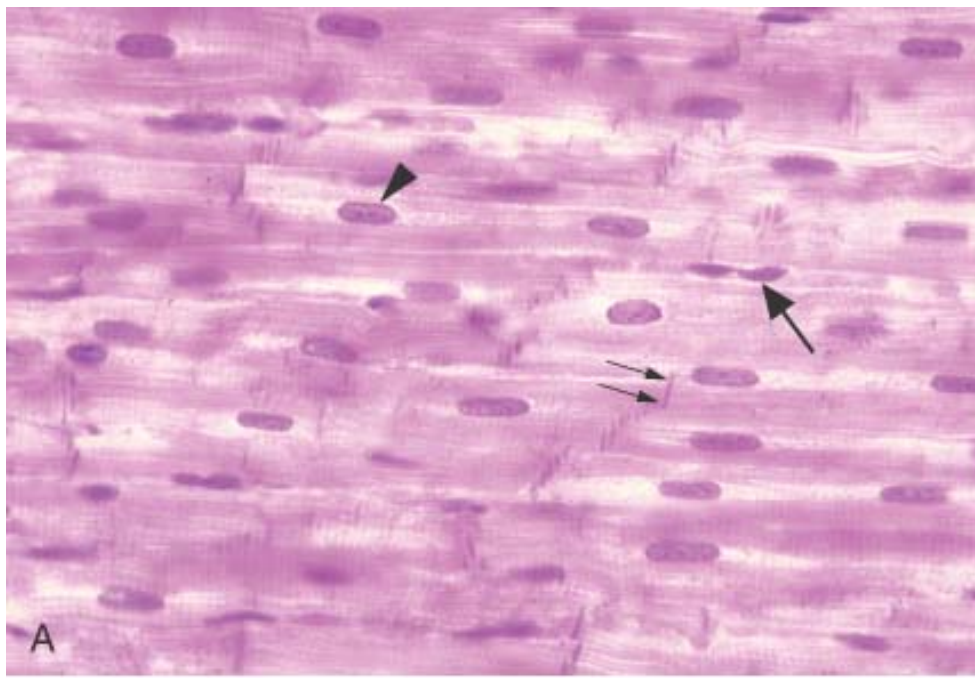
The normal heart weight varies with body height and weight; it averages approximately 250 to 300 g in females and 300 to 350 g in males. The usual thickness of the free wall of the right ventricle is 0.3 to 0.5 cm and that of the left ventricle 1.3 to 1.5 cm. As will be seen, increases in cardiac size and weight accompany many forms of heart disease. Greater heart weight or ventricular thickness indicates *hypertrophy*, and an enlarged chamber size implies *dilation*. An increase in cardiac weight or size (owing to hypertrophy and/or dilation) is termed *cardiomegaly*.

## Myocardium

Basic to the heart's function is the near-inexhaustible cardiac muscle, the *myocardium*, composed primarily of a collection of specialized muscle cells called *cardiac myocytes* ( Fig. 12-1 ). They are arranged largely in a circumferential and

**Figure 12-1** Myocardium (cardiac muscle). *A* The histology of myocardium is shown, emphasizing the centrally-placed nuclei of the cardiac myocytes (arrowhead), intercalated discs (representing specialized end-to-end junctions of adjoining cells; highlighted by a double arrow) and the sarcomeric structure visible as cross-striations within myocytes. A capillary endothelial cell is indicated by an arrow. (*Photomicrograph courtesy of Mark Flomenbaum, M.D., Ph.D., Office of the Chief Medical Examiner, New York City, NY.*) *B* Electron microscopy of myocardium, showing myofibrillar (my) and mitochondrial (mi) architecture and the sarcolemmal membrane (s). Z bands are indicated by arrows. Bar = 1  $\mu$ m. (*Reproduced by permission from Vivaldi MT, et al. Triphenyltetrazolium staining of irreversible injury following coronary artery occlusion in rats. Am J Pathol 121:522, 1985. Copyright J.B. Lippincott, 1985.*)





**Figure 12-2** Aortic valve histology, shown as a low-magnification photomicrograph of cuspal cross-section in the systolic (nondistended) state, emphasizing three major layers (ventricularis [v], spongiosa [s], and fibrosa [f]). Superficial endothelial cells (*arrow*) and diffusely distributed deep interstitial cells are noted. The strength of the valve is predominantly

derived from the fibrosa, with its dense collagen (yellow). This section highlights the dense, laminated elastic tissue in the ventricularis (*double arrow*). The outflow surface is at top. (Reproduced by permission from Schoen FJ: Aortic valve structure-function correlations: Role of elastic fibers no longer a stretch of the imagination. J Heart Valve Dis 6:1, 1997.)

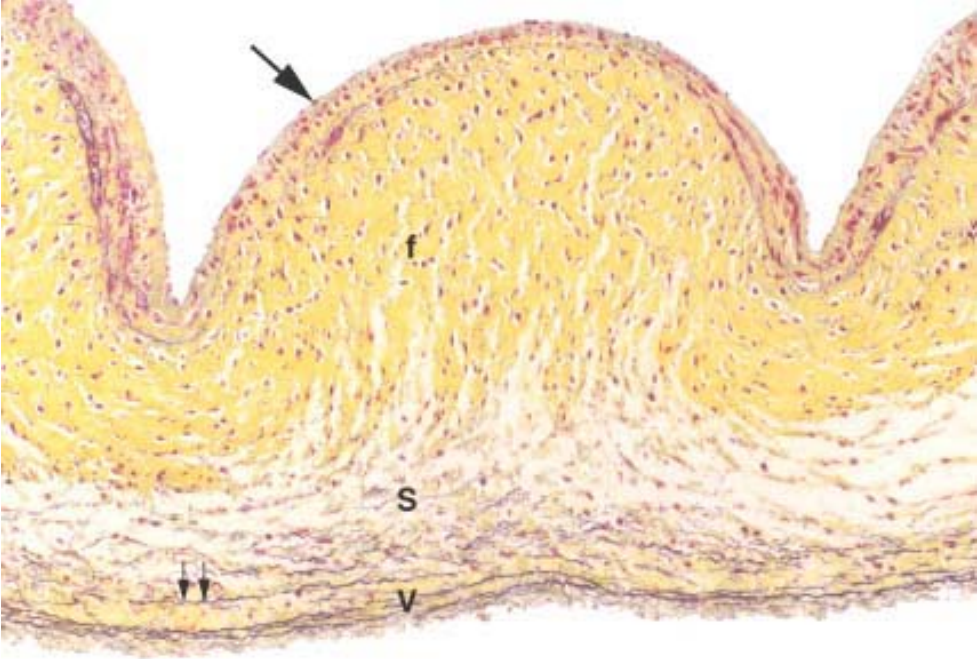


TABLE 12-1 -- Changes in the Aging Heart

<b>Chambers</b>
Increased left atrial cavity size
Decreased left ventricular cavity size
Sigmoid-shaped ventricular septum
<b>Valves</b>
Aortic valve calcific deposits
Mitral valve annular calcific deposits
Fibrous thickening of leaflets
Buckling of mitral leaflets toward the left atrium
Lambl excrescences
<b>Epicardial Coronary Arteries</b>
Tortuosity
Increased cross-sectional luminal area



Calcific deposits
Atherosclerotic plaque
<b><i>Myocardium</i></b>
Increased mass
Increased subepicardial fat
Brown atrophy
Lipofuscin deposition
Basophilic degeneration
Amyloid deposits
<b><i>Aorta</i></b>
Dilated ascending aorta with rightward shift
Elongated (tortuous) thoracic aorta
Sinotubular junction calcific deposits
Elastic fragmentation and collagen accumulation
Atherosclerotic plaque

With advancing age, the amount of epicardial fat increases, particularly over the anterior surface of the right ventricle and in the atrial septum. A reduction in the size of the left ventricular cavity, particularly in the base-to-apex dimension, is associated with increasing age and accentuated by systemic hypertension. Accompanied by a rightward shift and tortuosity of a dilated ascending aorta, this chamber alteration causes the basal ventricular septum to bend leftward, bulging into the left ventricular outflow tract (termed *sigmoid septum*). Such reduction in the size of the left ventricular cavity can simulate the obstruction to blood leaving the left ventricle that often occurs with hypertrophic cardiomyopathy, discussed later in this chapter.

Several changes of the valves are noted with aging, including calcification of the mitral annulus and aortic valve, the latter frequently leading to aortic stenosis. In addition, the valves can develop fibrous thickening, and the mitral leaflets tend to buckle back toward the left atrium during ventricular systole, simulating a prolapsing (myxomatous) mitral valve (see later). Moreover, many older persons develop small filiform processes (*Lambl excrescences*) on the closure lines of aortic and mitral valves, probably arising from the organization of small thrombi on the valve contact margins.

Compared with younger myocardium, "elderly" myocardium also has fewer myocytes, increased collagenized connective tissue and, in some individuals, deposition of amyloid. In the muscle cells, lipofuscin deposits ( Chapter 1 ), and *basophilic degeneration*, an accumulation within cardiac myocytes of a gray-blue byproduct of glycogen metabolism, may be present. Extensive lipofuscin deposition in a small, atrophied heart is called *brown atrophy*; this change often accompanies cachectic weight loss, as seen in terminal cancer.

Although the morphologic changes described are common in elderly patients at necropsy, and they may mimic disease, in only a minority are they associated with clinical cardiac dysfunction.

**Pathology**

Although many diseases can involve the heart and blood vessels, <sup>[6]</sup> <sup>[7]</sup> cardiovascular dysfunction results from one or more of five principal mechanisms:

- *Failure of the pump.* In the most common circumstance, the cardiac muscle contracts weakly or inadequately, and the chambers cannot empty properly. In some conditions, however, the muscle cannot relax sufficiently to permit ventricular filling.
- *An obstruction to flow,* owing to a lesion preventing valve opening or otherwise causing increased ventricular chamber pressure (e.g., aortic valvular stenosis, systemic hypertension, or aortic coarctation). The increased pressure overworks the chamber that pumps against the obstruction.
- *Regurgitant flow* causes some of the output from each contraction to flow backward, adding a volume workload to each of the chambers, which must pump the extra blood (e.g., left ventricle in aortic regurgitation; left atrium and left ventricle in mitral regurgitation).
- *Disorders of cardiac conduction.* Heart block or arrhythmias owing to uncoordinated generation of impulses (e.g., atrial or ventricular fibrillation) lead to nonuniform and inefficient contractions of the muscular walls.
- *Disruption of the continuity of the circulatory system* that permits blood to escape (e.g., gunshot wound through the thoracic aorta).

Most cardiovascular disease arises from the interaction of environmental factors and genetic susceptibility. *The contemporary view holds that most clinical cardiovascular diseases result from a complex interplay of genetics and environmental factors that disrupt networks controlling morphogenesis, myocyte survival, biomechanical stress responses, contractility, and electrical conduction.*<sup>[8]</sup> For example, there is growing recognition that pathogenesis of congenital heart defects, in many cases, involves an underlying genetic abnormality whose expression is strongly modified by external (environmental or maternal) factors. Moreover, since a diverse group of cytoskeletal protein mutations have been linked with cardiac muscle cell dysfunction in the cardiomyopathies, perhaps subtle mutations or polymorphisms in these genes could confer an increased risk or more rapid onset of heart failure in response to acquired cardiac injury. In these and other examples, the clinical expression of cardiac disease represents the end result of multiple internal and external cues for growth, death, and survival of cardiac myocytes. These factors and pathways are shared with other normal tissues and pathological processes.<sup>[9]</sup>

## Heart Failure

The abnormalities described above often culminate in heart failure, an extremely common result of many forms of heart disease. In heart failure, often called *congestive heart failure (CHF)*, the heart is unable to pump blood at a rate commensurate with the requirements of the metabolizing tissues or can do so only at an elevated filling pressure. Although usually caused by a slowly developing intrinsic deficit in myocardial contraction, a similar clinical syndrome is present in some patients with heart failure caused by conditions in which the normal heart is suddenly presented with a load that exceeds its capacity (e.g., fluid overload, acute myocardial infarction, acute valvular dysfunction) or in which ventricular filling is impaired (see below). CHF is a common and often recurrent condition with a poor prognosis. The magnitude of the problem is exemplified by the impact of CHF in the United States, where each year it affects nearly 5 million individuals, is the underlying or contributing cause of death of an estimated 300,000, and necessitates over 1 million hospitalizations.<sup>[10]</sup> Moreover, CHF is the leading discharge diagnosis in hospitalized patients over age 65 and has an associated annual cost of \$18 billion. In many pathologic states, the onset of heart failure is preceded by *cardiac hypertrophy*, the compensatory response of the myocardium to increased mechanical work (see below).

The cardiovascular system maintains arterial pressure and perfusion of vital organs in the presence of excessive hemodynamic burden or disturbance in myocardial contractility by a number of mechanisms.<sup>[11]</sup> The most important are:

- *The Frank-Starling mechanism*, in which the increased preload of dilation (thereby increasing cross-bridges within the sarcomeres) helps to sustain cardiac performance by enhancing contractility
- *Myocardial structural changes, including augmented muscle mass (hypertrophy) with or without cardiac chamber dilation*, in which the mass of contractile tissue is augmented
- *Activation of neurohumoral systems*, especially (1) release of the neurotransmitter norepinephrine by adrenergic cardiac nerves (which increases heart rate and augments myocardial contractility and vascular resistance), (2) activation of the renin-angiotensin-aldosterone system, and (3) release of atrial natriuretic peptide.



These adaptive mechanisms may be adequate to maintain the overall pumping performance of the heart at relatively normal levels, but their capacity to sustain cardiac performance may ultimately be exceeded. Moreover, pathologic changes, such as apoptosis, cytoskeletal alterations, and extracellular matrix (particularly collagen) synthesis and remodeling, may also occur, causing structural and functional disturbances. Most instances of heart failure are the consequence of progressive deterioration of myocardial contractile function (*systolic dysfunction*), as often occurs with ischemic injury, pressure or volume overload, or dilated cardiomyopathy. The most frequent specific causes are ischemic heart disease and hypertension. Sometimes, however, failure results from an inability of the heart chamber to relax, expand, and fill sufficiently during diastole to accommodate an adequate ventricular blood volume (*diastolic dysfunction*), as can occur with massive left ventricular hypertrophy, myocardial fibrosis, deposition of amyloid, or constrictive pericarditis.<sup>[12]</sup> *Whatever its basis, CHF is characterized by diminished cardiac output (sometimes called forward failure) or damming back of blood in the venous system (so-called backward failure), or both.*

The molecular, cellular, and structural changes in the heart that occur as a response to injury, and cause changes in size, shape, and function, are often called *left ventricular remodeling*. Our discussion focuses on structural changes and considers heart failure to be a progressive disorder, which can culminate in a clinical syndrome characterized by impaired cardiac function and circulatory congestion. Nevertheless, we recognize that the modern treatment of chronic heart failure emphasizes the neurohumoral hypothesis, in which neuroendocrine activation is important in the progression of heart failure. Thus, inhibition of neurohormones may have long-term beneficial effects on morbidity and mortality.<sup>[13]</sup> In the future, patients with CHF may be helped by implanted mechanical cardiac assist devices, an area in which considerable progress has recently been made.<sup>[14]</sup>

#### **CARDIAC HYPERTROPHY: PATHOPHYSIOLOGY AND PROGRESSION TO FAILURE**

The cardiac myocyte is generally considered a terminally differentiated cell that has lost its ability to divide. Under normal circumstances, functionally useful augmentation of myocyte number (*hyperplasia*) cannot occur. Increased mechanical load causes an increase in the content of subcellular components and a consequent increase in cell size (*hypertrophy*). Increased mechanical work owing to pressure or volume overload or trophic signals (e.g., hyperthyroidism through stimulation of beta-adrenergic receptors) increases the rate of protein synthesis, the amount of protein in each cell, the number of sarcomeres and mitochondria, the dimension and mass of myocytes and, consequently, the size of the heart. Nevertheless, the extent to which adult cardiac myocytes have some capacity to synthesize DNA and whether this leads to some degree of cell division is an area of considerable recent attention and debate.<sup>[15]</sup>

The extent of hypertrophy varies for different underlying causes. Heart weight usually ranges from 350 to 600 gm (up to approximately two times normal) in pulmonary hypertension and ischemic heart disease; from 400 to 800 gm (up to two to three times normal) in systemic hypertension, aortic stenosis, mitral regurgitation, or dilated cardiomyopathy; from 600 to 1000 gm (three or more times normal) in aortic regurgitation or hypertrophic cardiomyopathy. Hearts weighing more than 1000 gm are rare.

The pattern of hypertrophy reflects the nature of the stimulus ( Fig. 12-3 ). Pressure-overloaded ventricles (e.g., in hypertension or aortic stenosis) develop *pressure-overload* (also called *concentric*) *hypertrophy* of the left ventricle, with an increased wall thickness. In the left ventricle the augmented muscle may reduce the cavity diameter. In pressure overload, the predominant deposition of sarcomeres is parallel to the long axes of cells; cross-sectional area of myocytes is expanded (but cell length is not). In contrast, volume overload stimulates deposition of new sarcomeres and cell length (as well as

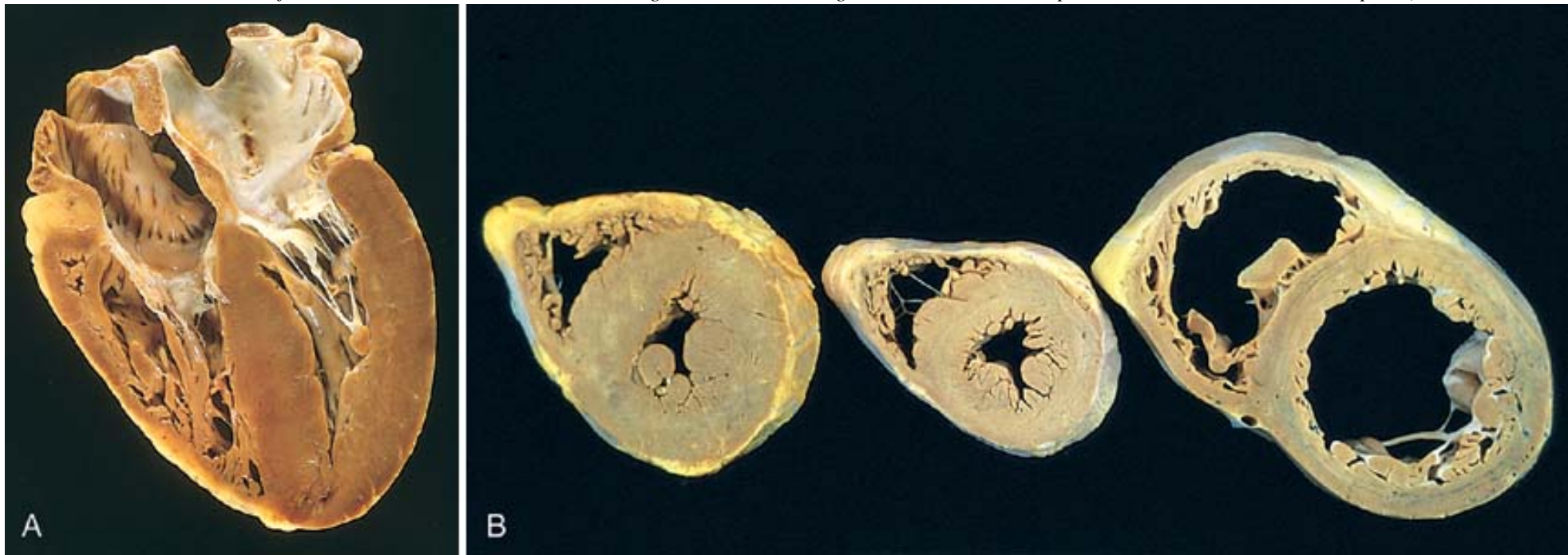
width) is increased. Thus, *volume-overload hypertrophy* is characterized by dilation with increased ventricular diameter. In volume overload, muscle mass and wall thickness are increased approximately in proportion to chamber diameter. However, owing to dilation, wall thickness of a heart in which both hypertrophy and dilation have occurred is not necessarily increased, and it may be normal or less than normal. Thus, wall thickness is by itself not an adequate measure of volume-overload hypertrophy.

Cardiac hypertrophy is also accompanied by numerous transcriptional and morphologic changes. With prolonged hemodynamic overload, gene expression is altered, leading to re-expression of a pattern of protein synthesis analogous to that seen in fetal cardiac development; other changes are analogous to events that occur during mitosis of normally proliferating cells ( Chapter 1 ). Early mediators of hypertrophy include the immediate-early genes (e.g., *c-fos*, *c-myc*, *c-jun* and *EGRI*). Selective up-regulation or re-expression of embryonic/fetal

forms of contractile and other proteins also occurs, including  $\beta$ -myosin heavy chain, ANP, and collagen (see Chapter 1 ). The increased myocyte size that occurs in cardiac hypertrophy is usually accompanied by decreased capillary density, increased intercapillary distance, and deposition of fibrous tissue. Nevertheless, the enlarged muscle mass has increased metabolic requirements and increased wall tension, both major determinants of the oxygen consumption of the heart. The other major factors in oxygen consumption are heart rate and contractility (inotropic state, or force of contraction), both of which are often increased in hypertrophic states.

*Thus, the geometry, structure, and composition (cells and extracellular matrix) of the hypertrophied heart are not normal. Cardiac hypertrophy constitutes a tenuous balance between adaptive characteristics (including new sarcomeres) and potentially deleterious structural and biochemical/molecular alterations*

**Figure 12-3** Left ventricular hypertrophy. *A*, Pressure hypertrophy due to left ventricular outflow obstruction. The left ventricle is on the lower right in this apical four-chamber view of the heart. *B*, Altered cardiac configuration in left ventricular hypertrophy without and with dilation, viewed in transverse heart sections. Compared with a normal heart (*center*), the pressure-hypertrophied hearts (*left* and in *A*) have increased mass and a thick left ventricular wall, but the hypertrophied and dilated heart (*right*) has increased mass but a normal wall thickness. (Reproduced by permission from Edwards WD: *Cardiac anatomy and examination of cardiac specimens*. In Emmanouilides GC, Riemenschneider TA, Allen HD, Gutgesell HP (eds): *Moss and Adams Heart Disease in Infants, Children, and Adolescents: Including the Fetus and Young Adults*, 5th ed. Philadelphia, Williams and Wilkins, 1995, p. 86.)



**Figure 12-4** Schematic representation of the sequence of events in cardiac hypertrophy and its progression to heart failure, emphasizing cellular and extracellular changes.



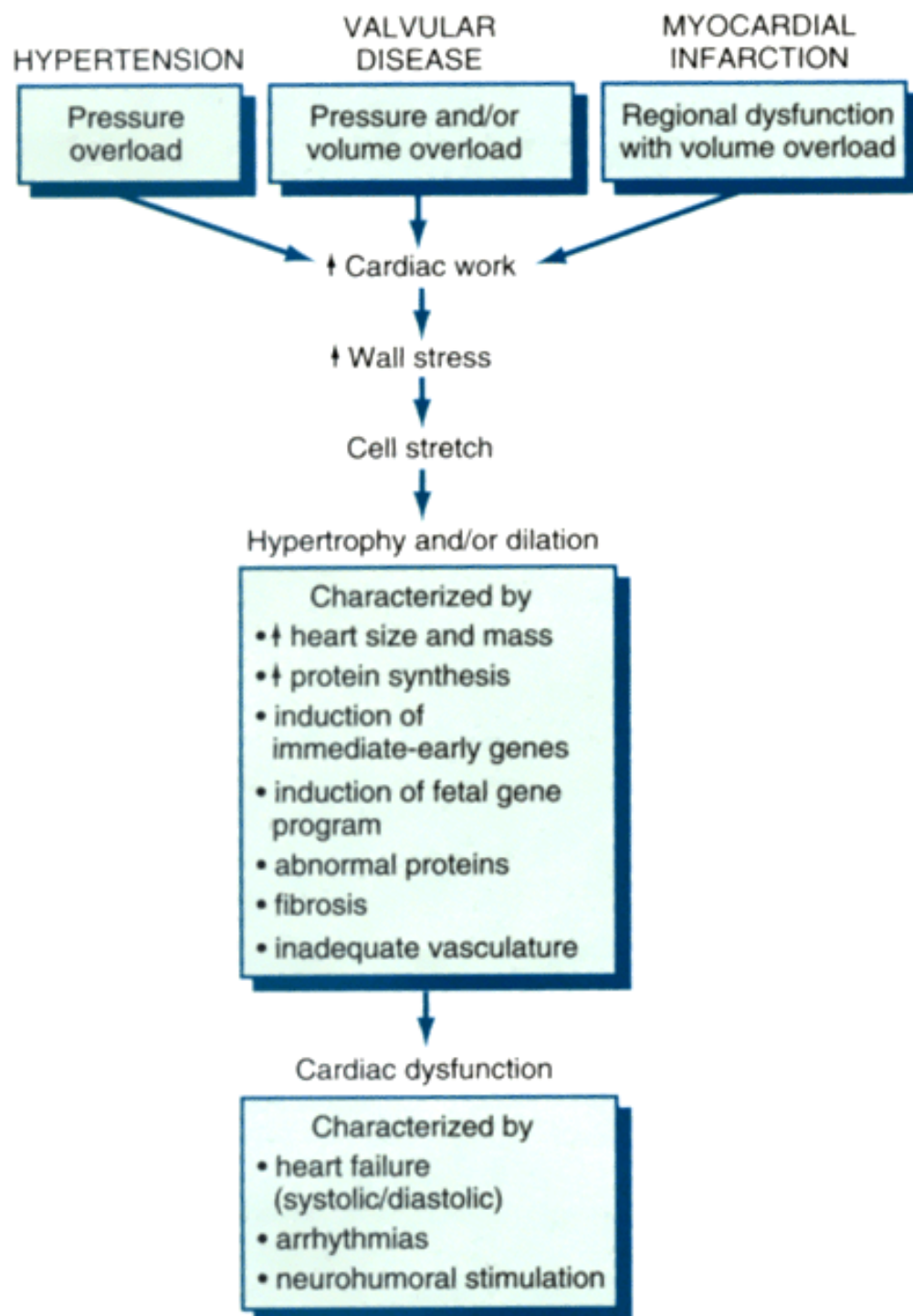


TABLE 12-2 -- Frequencies of Congenital Cardiac Malformations \*

Malformation	Incidence per Million Live Births	%
Ventricular septal defect	4482	42
Atrial septal defect	1043	10
Pulmonary stenosis	•836	•8
Patent ductus arteriosus	•781	•7
Tetralogy of Fallot	•577	•5
Coarctation of aorta	•492	•5
Atrioventricular septal defect	•396	•4
Aortic stenosis	•388	•4
Transposition of great arteries	•388	•4
Truncus arteriosus	•136	•1
Total anomalous pulmonary venous connection	•120	•1
Tricuspid atresia	•118	•1
TOTAL	9757	

*Source: Hoffman JIE, Kaplan S: The incidence of congenital heart disease. J Am Coll Cardiol 39:1890, 2002.*

\*Presented as upper quartile of 44 published studies. Percentages do not add to 100% owing to rounding.

echocardiography and magnetic resonance imaging). The enhanced resolving power of noninvasive methods should prove particularly useful in the study of familial structural defects, because apparently unaffected relatives can be evaluated for subclinical evidence of anomalies.

#### **Etiology and Pathogenesis.**

The etiology of congenital malformations in general was discussed in Chapter 10 . We therefore confine our remarks to factors of particular relevance to congenital cardiac malformations.

Congenital heart defects are caused by developmental abnormalities. However, the genes that may be involved in these defects have been identified in only a minority of conditions. In fact, well-defined genetic or environmental influences are identifiable in only about 10% of cases of congenital heart disease, but the understanding of probable genetic links is increasing. The obvious role of genetic factors in some cases is demonstrated by the occurrence of familial forms of congenital heart disease and by an association of congenital cardiac malformations with certain chromosomal abnormalities (e.g., trisomies 13, 15, 18, and 21, and the Turner syndrome). Indeed, a congenital heart defect in a parent or preceding sibling is the greatest risk factor for developing a cardiac malformation. Trisomy 21 (associated with Down syndrome) is the most common known genetic cause of congenital heart disease. *Environmental factors*, such as congenital rubella infection or teratogens, are responsible for some additional cases. Multifactorial genetic, environmental, and maternal factors probably account for the remaining majority of cases in which a cause is not apparent.

The growing understanding of the genetics of congenital heart disease has also led to the recognition that powerful disease modifiers must exist. There is wide variation in the



nature and severity of lesions in patients with identical genetic abnormalities. This suggests that altering key environmental or maternal factors could modify disease in high-risk individuals, whether or not the disease is caused by a distinct genetic abnormality. For instance, this type of strategy has resulted in marked reduction in neural tube defects by increasing maternal dietary folate.<sup>[25]</sup>

#### Genetics of Cardiac Development and Congenital Heart Disease.

Composed of diverse cell lineages, the heart is among the first organs to form and function in vertebrate embryos. Cardiac morphogenesis involves a myriad of genes and is tightly regulated to ensure an effective embryonic circulation. Key steps involve specification of cardiac cell fate, morphogenesis and looping of the heart tube, segmentation and growth of the cardiac chambers, cardiac valve formation, and connection of the great vessels to the heart.<sup>[26]</sup> The genetic regulation of heart formation has been widely studied in model organisms, including chick, frog, mouse, and zebrafish. In recent years, the zebrafish, an organism that is transparent and has external fertilization, a brief generation time, and no requirement of a functional cardiovascular system for survival during embryogenesis, has permitted detailed genetic analysis of both normal development and cardiac defects.<sup>[27]</sup> <sup>[28]</sup> The molecular pathways controlling cardiac development provide a foundation for understanding the basis of some congenital heart defects and can be used to reveal pathways and interactions important in human disease.<sup>[29]</sup>

Several congenital heart diseases are associated with mutations in transcription factors. For example, mutation of the gene that encodes the transcription factor, TBX5, has been shown to cause the ASD and VSD observed in the Holt-Oram syndrome, a rare hereditary condition associated with heart, arm, and hand defects.<sup>[30]</sup> Another gene, encoding the transcription factor NKX2.5, causes nonsyndromic (isolated) ASD in humans when one copy is missing. This gene is the human counterpart of the *tinman* gene of the fruit fly (so named because, like the Tin Man in *The Wizard of Oz*, fruit fly embryos lacking both copies of *tinman* have no hearts). Nevertheless, most ASDs do not have an identifiable genetic etiology, and the mechanisms by which mutated transcription factors cause clinically important heart defects are just beginning to be understood.<sup>[31]</sup>

Until recently, in most studies, defects were classified by their pathology; for example, all VSDs were considered as one group. A major advance has been to examine familial aggregation of defects based on presumed pathogenesis. Since some cardiac structures share developmental pathways, anatomically and clinically distinct lesions may be related by a common genetic defect. Thus, the occurrence of distinct defects in the same family remains consistent with a genetic model. Defects unrelated by pathogenesis would require a different interpretation.

Developmental errors in mesenchymal tissue migration exemplify the concept that distinct syndromes share a common pathogenesis. Included in this category is a wide range of anomalies of the outflow tract, some due to failure of fusion and others due to failure of septation. These lesions include isolated interruption of the aortic arch, persistent truncus arteriosus (failure of separation of aorta and pulmonary arteries), and tetralogy of Fallot (malalignment of aorta and pulmonary artery with the ventricles). Comprising 15% of congenital heart defects, outflow tract defects may be caused by the abnormal development of neural crest-derived cells, whose migration into the embryonic heart is required for formation of the outflow tracts of the heart ( Fig. 12-5 ). Considerable progress has been made during the past few years in identifying a region of chromosome 22 that has a major role in development of the conotruncus, the branchial arches, and the face. Chromosome 22q11.2 deletions are seen in 15% to 50% of these disorders, rendering this abnormality a common genetic cause of congenital heart defects (see also Chapter 5 ). This condition includes developmental anomalies of the fourth branchial arch and derivatives of the third and fourth pharyngeal pouches. Hypoplasia of the thymus and parathyroids causes immune deficiency (Di George syndrome, Chapter 5 ) and hypocalcemia.

Other common mechanisms of congenital heart disease include extracellular matrix abnormalities and situs and looping defects. The endocardial cushions have received the most attention as an area where defects in cell-cell and cell-extracellular matrix interactions might produce malformations, as evidenced by a high frequency of endocardial cushion defects and atrioventricular septal defects in Down syndrome. Situs and looping defects may arise from single genes that have a major effect on determining laterality.

#### Clinical Features.

The varied structural anomalies in congenital heart disease fall primarily into three major categories:

- Malformations causing a *left-to-right shunt*
- Malformations causing a *right-to-left shunt*
- Malformations causing an *obstruction*.

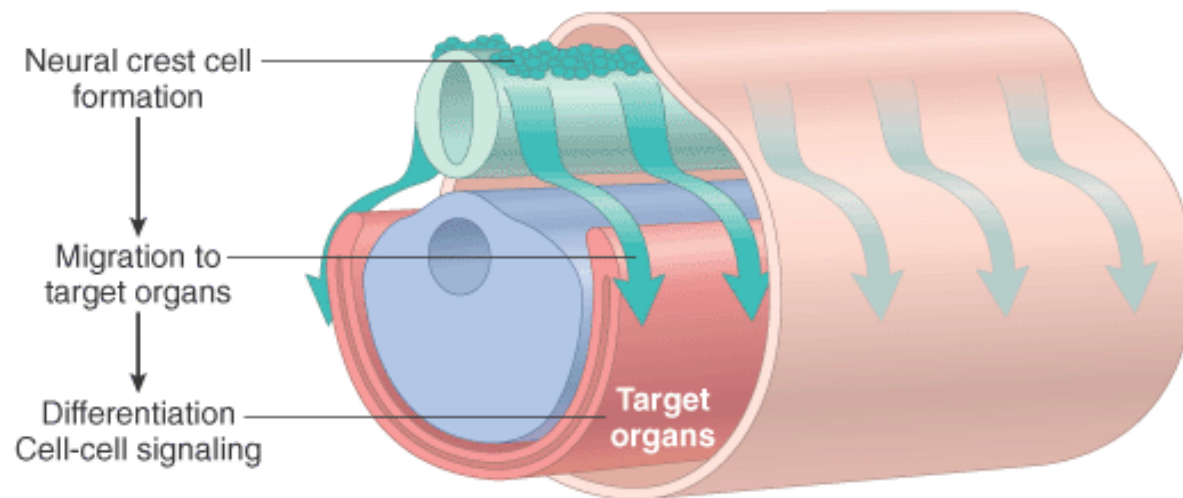
A *shunt* is an abnormal communication between chambers or blood vessels. Abnormal channels permit the flow of blood from left to right or the reverse, depending on pressure relationships. When blood from the right side of the heart enters the left side (*right-to-left shunt*), a dusky blueness of the skin and mucous membranes (*cyanosis*) results because there is diminished pulmonary blood flow, and poorly oxygenated blood enters the systemic circulation (called *cyanotic congenital heart disease*). The most important examples of right-to-left shunts are tetralogy of Fallot, transposition of the great arteries, persistent truncus arteriosus, tricuspid atresia, and total anomalous pulmonary venous connection. Moreover, with right-to-left shunts, bland or septic emboli arising in peripheral veins can bypass the normal filtration action of the lungs and thus directly enter the systemic circulation (*paradoxical embolism*); brain infarction and abscess are potential consequences. Clinical findings frequently associated with severe, long-standing cyanosis include *clubbing of the tips of the fingers and toes* (hypertrophic osteoarthropathy) and polycythemia.

In contrast, *left-to-right shunts* (such as ASD, VSD, and patent ductus arteriosus [PDA]) increase pulmonary blood flow and are not initially associated with cyanosis. However, they expose the postnatal, low-pressure, low-resistance pulmonary circulation to increased pressure and/or volume, which can result in right ventricular hypertrophy and, potentially, failure. Shunts associated with increased pulmonary blood flow include ASDs; shunts associated with both increased pulmonary blood flow and pressure include VSDs and PDA. The muscular pulmonary arteries (<1 mm diameter) first respond to increased pressure by medial hypertrophy

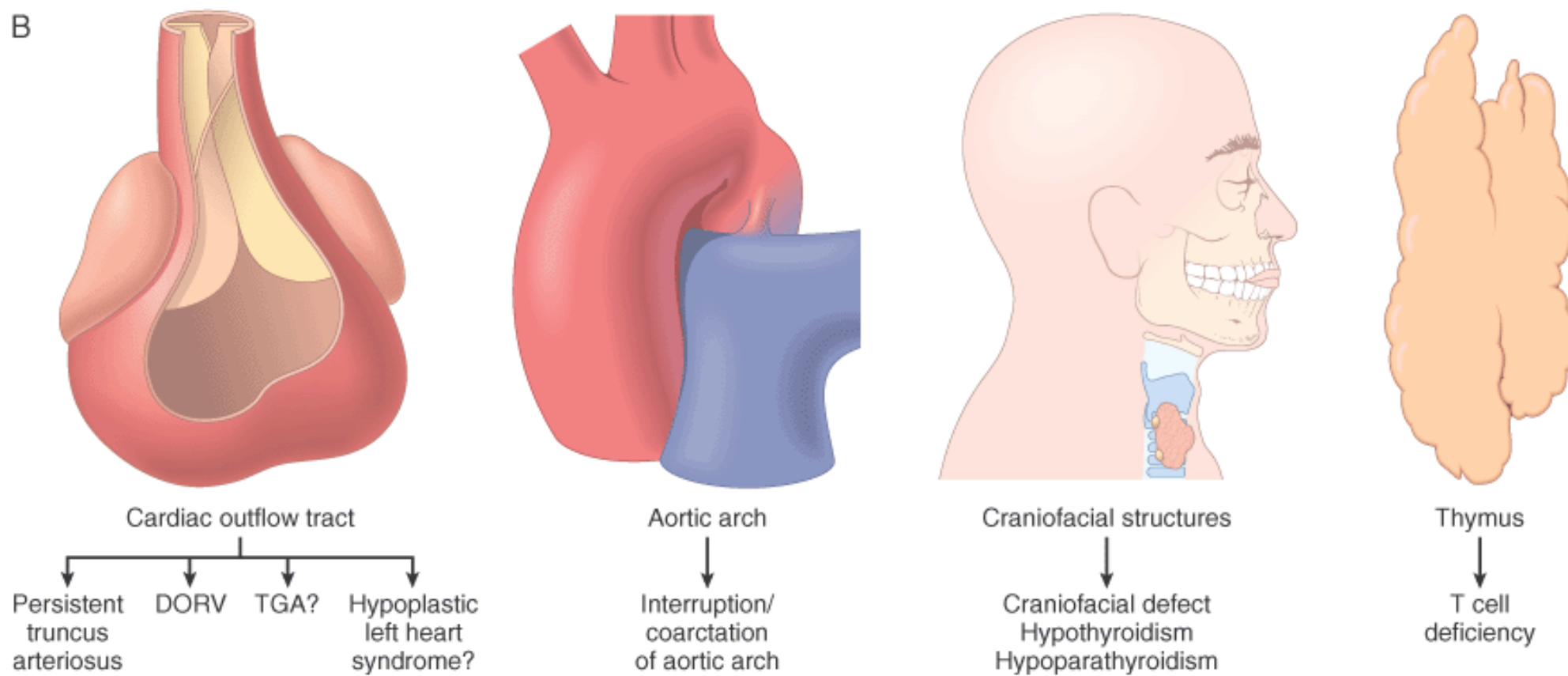
**Figure 12-5** Cardiac defects related to neural crest abnormalities. *A*, Biologic pathways for cardiac neural crest-related defects. *B*, Disease phenotypes. DORV, double-outlet right ventricle; TGA, transposition of the great arteries. (Reproduced by permission from Chien KR: *Genomic circuits and the integrative biology of cardiac diseases*. *Nature* 407:227, 2000.)



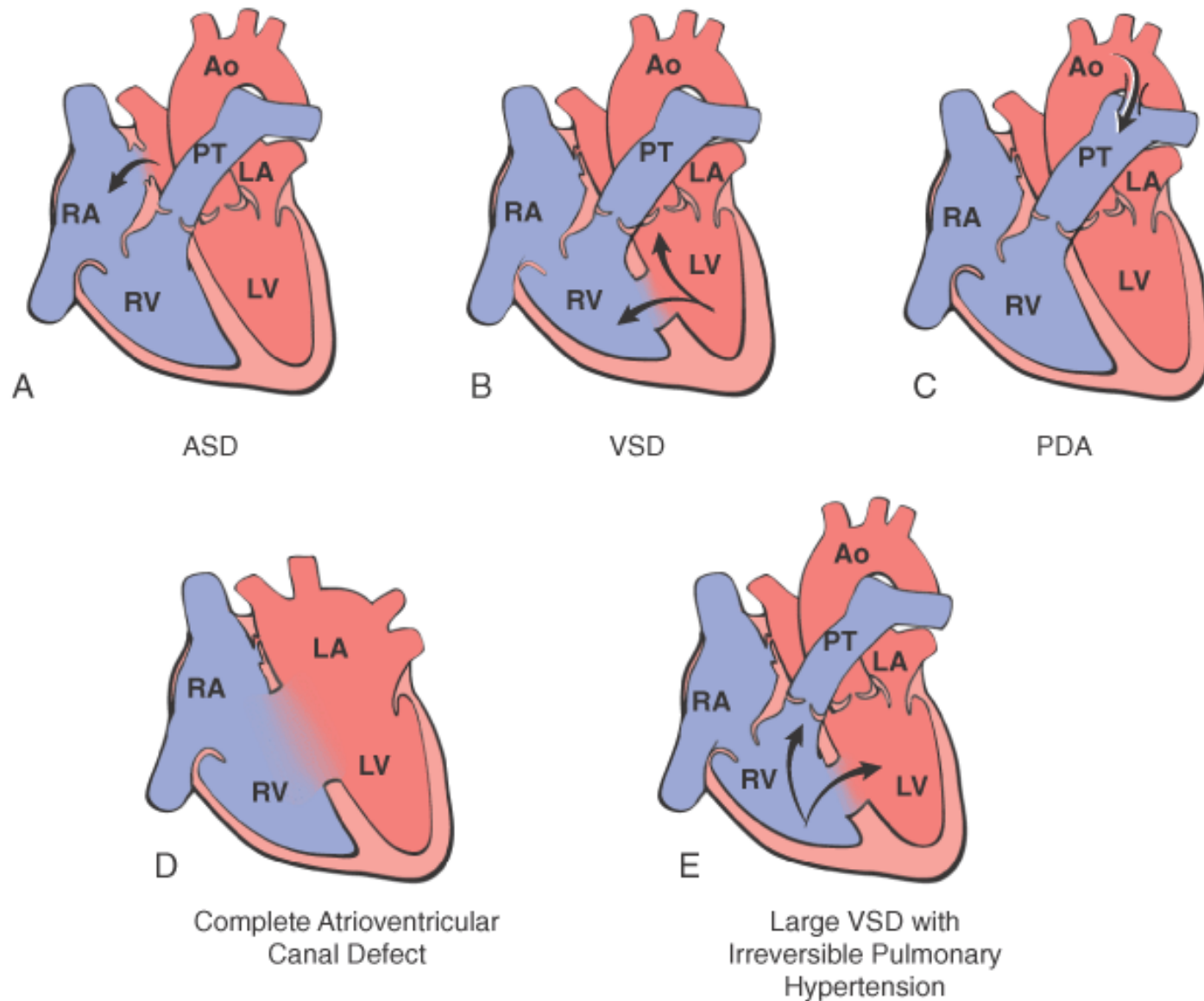
A



B

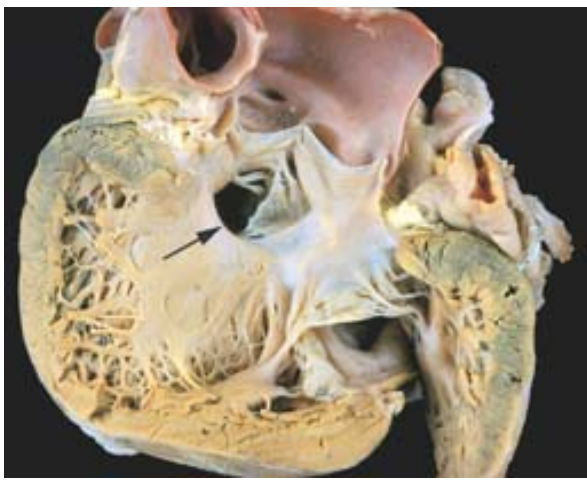


**Figure 12-6** Schematic diagram of congenital left-to-right shunts. *A*, Atrial septal defect (ASD). *B*, Ventricular septal defect (VSD). With VSD the shunt is left-to-right, and the pressures are the same in both ventricles. Pressure hypertrophy of the right ventricle and volume hypertrophy of the left ventricle are generally present. *C*, Patent ductus arteriosus (PDA). *D*, Atrioventricular septal defect (AVSD). *E*, Large VSD with irreversible pulmonary hypertension. The shunt is right-to-left (shunt reversal). Volume hypertrophy and pressure hypertrophy of the right ventricle are present. Arrow indicates the direction of blood flow. The right ventricular pressure is now sufficient to yield a right-to-left shunt (Ao, aorta; LA, left atrium; LV, left ventricle; PT, pulmonary trunk; RA, right atrium; RV, right ventricle.)

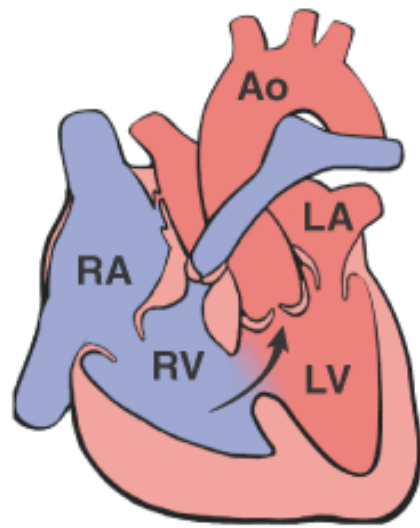


**Figure 12-7** Gross photograph of a ventricular septal defect (membranous type); defect denoted by arrow. (Courtesy of William D. Edwards, M.D., Mayo Clinic, Rochester, MN.)

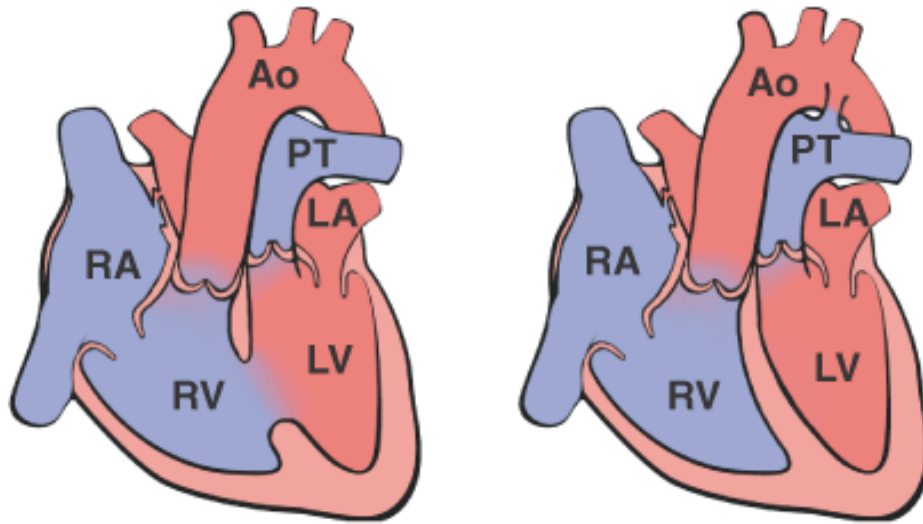




**Figure 12-8** Schematic diagram of the most important right-to-left shunts (*cyanotic congenital heart disease*). *A*, Tetralogy of Fallot. Diagrammatic representation of anatomic variants, indicating that the direction of shunting across the VSD depends on the severity of the subpulmonary stenosis. Arrows indicate the direction of the blood flow. *B*, Transposition of the great vessels with and without VSD. (Ao, aorta; LA, left atrium; LV, left ventricle; PT, pulmonary trunk; RA, right atrium; RV, right ventricle.) (Courtesy of William D. Edwards, M.D., Mayo Clinic, Rochester, MN.)



A Classic Tetralogy of Fallot



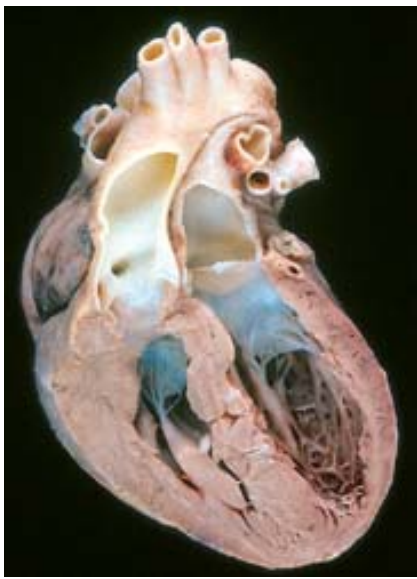
With VSD

Without VSD

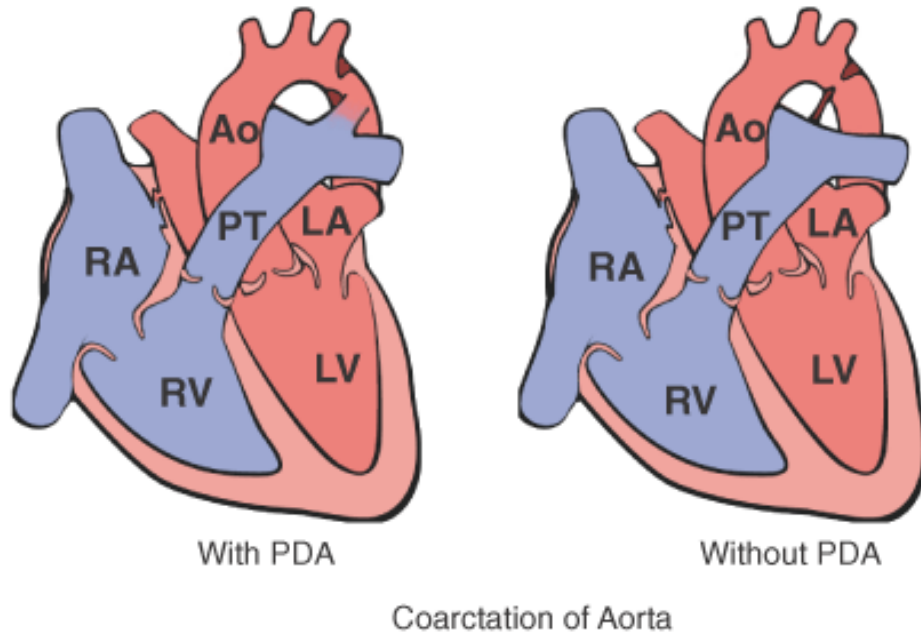
B Complete Transposition

**Figure 12-9** Transposition of the great arteries. (Courtesy of William D. Edwards, M.D., Mayo Clinic, Rochester, MN.)

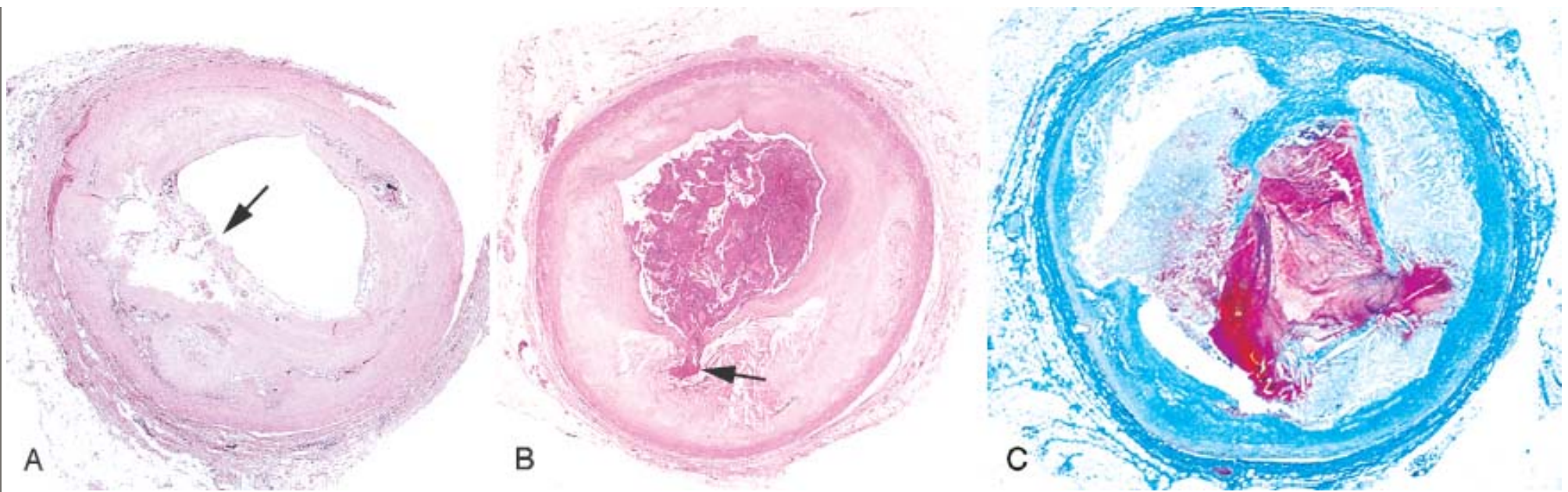




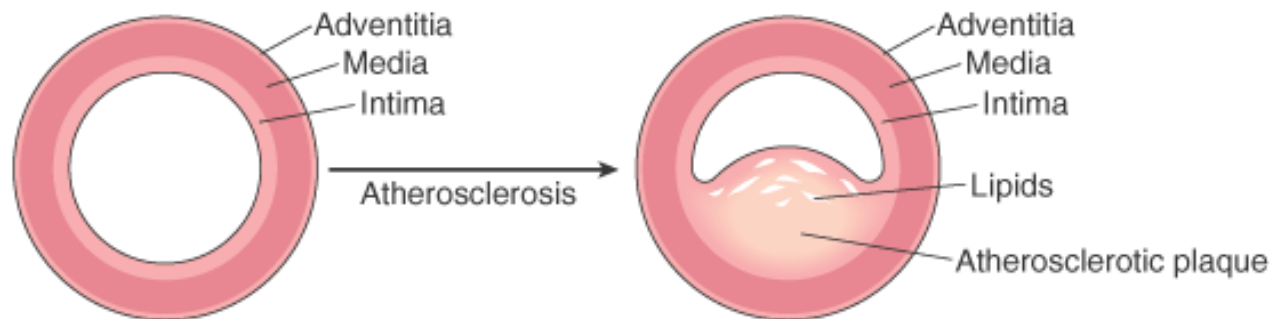
**Figure 12-10** Diagram showing coarctation of the aorta with and without PDA. (Ao, aorta; LA, left atrium; LV, left ventricle; PT, pulmonary trunk; RA, right atrium; RV, right ventricle; PDA, persistent ductus arteriosus.) (Courtesy of William D. Edwards, M.D., Mayo Clinic, Rochester, MN.)



**Figure 12-11** Atherosclerotic plaque rupture. *A*, Plaque rupture without superimposed thrombus, in patient who died suddenly. *B*, Acute coronary thrombosis superimposed on an atherosclerotic plaque with focal disruption of the fibrous cap, triggering fatal myocardial infarction. *C*, Massive plaque rupture with superimposed thrombus, also triggering a fatal myocardial infarction (special stain highlighting fibrin in red). In both *A* and *B*, an arrow points to the site of plaque rupture. (*B*, reproduced from Schoen FJ: *Interventional and Surgical Cardiovascular Pathology: Clinical Correlations and Basic Principles*. Philadelphia, W.B. Saunders, 1989, p. 61.)

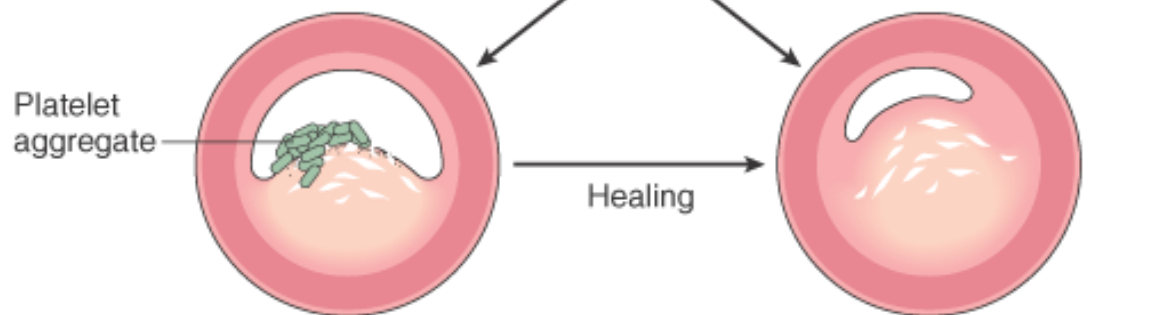


**Figure 12-12** Schematic representation of sequential progression of coronary artery lesion morphology, beginning with stable chronic plaque responsible for typical angina and leading to the various acute coronary syndromes. (*Modified and redrawn from Schoen FJ: Interventional and Surgical Cardiovascular Pathology: Clinical Correlations and Basic Principles. Philadelphia, W.B. Saunders Co., 1989, p. 63.*)



NORMAL

FIXED CORONARY OBSTRUCTION  
(Typical angina)

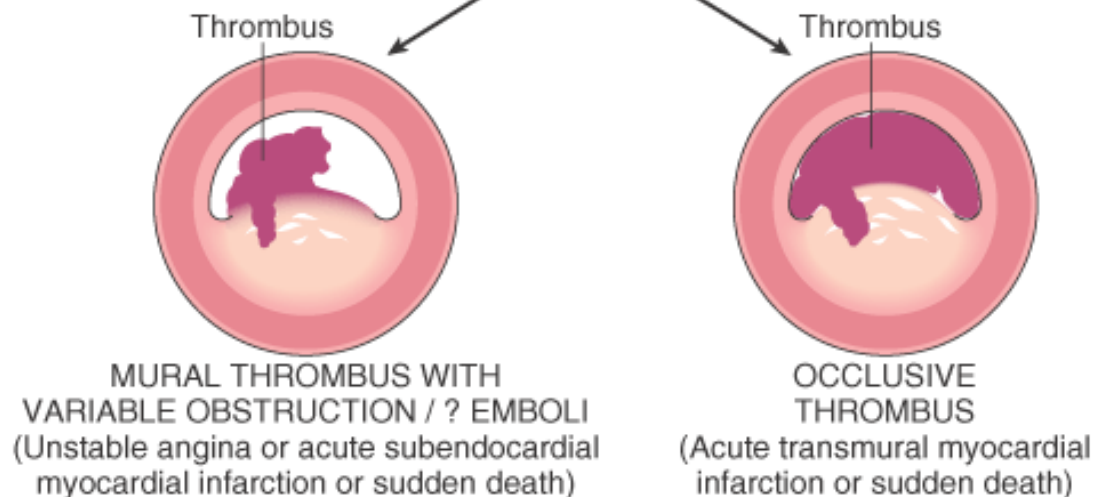


Platelet  
aggregate

Healing

PLAQUE DISRUPTION

SEVERE FIXED CORONARY  
OBSTRUCTION  
(Chronic ischemic heart disease)



Thrombus

Thrombus

MURAL THROMBUS WITH  
VARIABLE OBSTRUCTION / ? EMBOLI  
(Unstable angina or acute subendocardial  
myocardial infarction or sudden death)

OCCLUSIVE  
THROMBUS  
(Acute transmural myocardial  
infarction or sudden death)

ACUTE CORONARY SYNDROMES



**TABLE 12-3 -- Coronary Artery Pathology in Ischemic Heart Disease**

Syndrome	Stenoses	Plaque Disruption	Plaque-Associated Thrombus
Stable angina	>75%	No	No
Unstable angina	Variable	Frequent	Nonocclusive, often with thromboemboli
Transmural myocardial infarction	Variable	Frequent	Occlusive
Subendocardial myocardial infarction	Variable	Variable	Widely variable, may be absent, partial/complete, or lysed
Sudden death	Usually severe	Frequent	Often small platelet aggregates or thrombi and/or thromboemboli

#### ANGINA PECTORIS

*Angina pectoris is a symptom complex of IHD characterized by paroxysmal and usually recurrent attacks of substernal or precordial chest discomfort (variously described as constricting, squeezing, choking, or knifelike) caused by transient (15 seconds to 15 minutes) myocardial ischemia that falls short of inducing the cellular necrosis that defines infarction.* There are three overlapping patterns of angina pectoris: (1) stable or typical angina, (2) Prinzmetal or variant angina, and (3) unstable or crescendo angina. They are caused by varying combinations of increased myocardial demand and decreased myocardial perfusion, owing to fixed stenosing plaques, disrupted plaques, vasospasm, thrombosis, platelet aggregation, and embolization. Moreover, it is being increasingly recognized that not all ischemic events are perceived by patients, even though such events may have adverse prognostic implications (*silent ischemia*).

*Stable angina*, the most common form and therefore called *typical angina pectoris*, appears to be caused by the reduction of coronary perfusion to a critical level by chronic stenosing coronary atherosclerosis; this renders the heart vulnerable to further ischemia whenever there is increased demand, such as that produced by physical activity, emotional excitement, or any other cause of increased cardiac workload. Typical angina pectoris is usually relieved by rest (thereby decreasing demand) or nitroglycerin, a strong vasodilator. Although the coronary arteries are usually maximally dilated by intrinsic regulatory influences, nitroglycerin also decreases cardiac work by dilating the peripheral vasculature. In particular instances, local vasospasm may contribute to the imbalance between supply and demand.

*Prinzmetal variant angina is an uncommon pattern of episodic angina that occurs at rest and is due to coronary artery spasm.* Usually there is an elevated ST segment on the electrocardiogram (ECG), indicative of transmural ischemia. Although individuals with this form of angina may well have significant coronary atherosclerosis, the anginal attacks are unrelated to physical activity, heart rate, or blood pressure. Prinzmetal angina generally responds promptly to vasodilators, such as nitroglycerin and calcium channel blockers.

*Unstable or crescendo angina* refers to a pattern of pain that occurs with progressively increasing frequency, is precipitated with progressively less effort, often occurs at rest, and tends to be of more prolonged duration. *As discussed above, in most patients, unstable angina is induced by disruption of an atherosclerotic plaque with superimposed partial (mural) thrombosis and possibly embolization or vasospasm (or both).* Although the ischemia that occurs in unstable angina falls precariously close to inducing clinically detectable infarction, unstable angina is often the prodrome of subsequent acute MI. Thus this syndrome is sometimes referred to as *preinfarction angina*, and in the spectrum of IHD, unstable angina lies intermediate between stable angina on the one hand and MI on the other.

#### MYOCARDIAL INFARCTION (MI)

*MI, also known as "heart attack," is the death of cardiac muscle resulting from ischemia.* It is by far the most important form of IHD and alone is the leading cause of death in the United States and industrialized nations. About 1.5 million individuals in the United States suffer an acute MI annually and approximately one third of them die. At least 250,000 people a year die of a heart attack before they reach the hospital.

#### Transmural versus Subendocardial Infarction.

Most myocardial infarcts are *transmural*, in which the ischemic necrosis involves the full or nearly full thickness of the ventricular wall in the distribution of a single coronary artery. This pattern of infarction is usually associated with coronary atherosclerosis, acute plaque change, and superimposed thrombosis (as discussed previously). In contrast, a *subendocardial (nontransmural) infarct* constitutes an area of ischemic necrosis limited to the inner one third or at most one half of the ventricular wall; under some circumstances, it may extend laterally beyond the perfusion territory of a single coronary artery. As previously pointed out, the subendocardial zone is normally the least well-perfused region of myocardium and therefore is most vulnerable to any reduction in coronary flow. A subendocardial infarct can occur as a result of a plaque disruption followed by coronary thrombus that becomes lysed before myocardial necrosis extends across the major thickness of the wall; in this case the infarct will be limited to the distribution of one coronary artery with plaque change. However, subendocardial infarcts can also result from sufficiently prolonged and severe reduction in systemic blood pressure, as in shock, often superimposed on chronic, otherwise noncritical, coronary stenoses. In cases of global hypotension, resulting subendocardial infarcts are usually circumferential or nearly so, rather than limited to the distribution of a single major coronary artery.

#### **Incidence and Risk Factors.**

The risk factors for atherosclerosis, the major underlying cause of IHD in general, are discussed in Chapter 11 and are not reiterated here. Suffice it to say that *MI may occur at virtually any age, but the frequency rises progressively with increasing age and when predispositions*

*to atherosclerosis are present*, such as hypertension, cigarette smoking, diabetes mellitus, genetic hypercholesterolemia, and other causes of hyperlipoproteinemia. Nearly 10% of myocardial infarcts occur in people under age 40, and 45% occur in people under age 65. Blacks and whites are equally affected. Throughout life, men are at significantly greater risk of MI than women; the differential progressively declines with advancing age. *Except for those having some predisposing atherogenic condition, women are remarkably protected against MI during the reproductive years.* Nevertheless, the decrease of estrogen following menopause can permit rapid development of coronary artery disease (CAD), and IHD is the overwhelming cause of death in elderly women. Moreover, recent epidemiologic evidence suggests that postmenopausal hormone replacement therapy does not protect women against MI.<sup>[53]</sup>

#### **Pathogenesis.**

We now consider the basis for and subsequent consequences of myocardial ischemia, particularly as they relate to the typical transmural myocardial infarct.

#### **Coronary Arterial Occlusion.**

As discussed above, transmural acute MI results from a dynamic interaction among several or all of the following—coronary atherosclerosis, acute atheromatous plaque change (such as rupture), superimposed platelet activation, thrombosis, and vasospasm—resulting in an occlusive intracoronary thrombus overlying a disrupted plaque. In addition, either increased myocardial demand (as with hypertrophy or tachycardia) or hemodynamic compromise (as with a drop in blood pressure) can worsen the situation. Recall also that collateral circulation may provide perfusion to ischemic zones from a relatively unobstructed branch of the coronary tree, bypassing the point of obstruction and protecting against the effects of an acute coronary occlusion.

In the typical case of MI, the following sequence of events can be proposed:

- *The initial event is a sudden change in the morphology of an atheromatous plaque*, that is, disruption—manifest as intraplaque hemorrhage, erosion or ulceration, or rupture or fissuring.
- Exposed to subendothelial collagen and necrotic plaque contents, *platelets undergo adhesion, aggregation, activation, and release of potent aggregators* including thromboxane

A<sub>2</sub> , serotonin, and platelet factors 3 and 4.

- Vasospasm is stimulated by platelet aggregation and the release of mediators.
- Other mediators activate the extrinsic pathway of coagulation, adding to the bulk of the thrombus.
- *Frequently within minutes, the thrombus evolves to completely occlude the lumen of the coronary vessel.*

The evidence for this sequence is compelling and derives from (1) autopsy studies of patients dying with acute MI, (2) angiographic studies demonstrating a high frequency of thrombotic occlusion early after MI, (3) the high success rate of therapeutic thrombolysis and primary angioplasty, and (4) the demonstration of residual disrupted atherosclerotic lesions by angiography after thrombolysis. Although coronary angiography performed within 4 hours of the onset of apparent MI shows a thrombosed coronary artery in almost 90% of cases, the observation of occlusion is seen in only about 60% when angiography is delayed until 12 to 24 hours after onset. <sup>[54]</sup> Thus with the passage of time, at least some occlusions appear to clear spontaneously owing to lysis of the thrombus or relaxation of spasm or both.

In approximately 10% of cases, transmural acute MI is not associated with atherosclerotic plaque thrombosis stimulated by disruption. In such situations, other mechanisms may be involved:

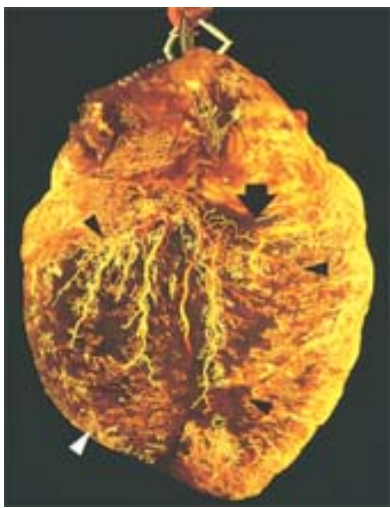- *Vasospasm*: isolated, intense, and relatively prolonged, with or without coronary atherosclerosis, perhaps in association with platelet aggregation (sometimes related to cocaine abuse).
- *Emboli*: from the left atrium in association with atrial fibrillation, a left-sided mural thrombus or vegetative endocarditis; or *paradoxical emboli* from the right side of the heart or the peripheral veins which cross to the systemic circulation, through a patent foramen ovale, causing coronary occlusion.
- *Unexplained*: cases without detectable coronary atherosclerosis and thrombosis may be caused by diseases of small intramural coronary vessels such as vasculitis, hematologic abnormalities such as hemoglobinopathies, amyloid deposition in vascular walls, or other unusual disorders, such as vascular dissection and inadequate protection during cardiac surgery.

#### **Myocardial Response.**

*The consequence of coronary arterial obstruction is the loss of critical blood supply to the myocardium ( Fig. 12-13 ), which induces profound functional, biochemical, and morphologic consequences.* Occlusion of a major coronary artery results in ischemia and, potentially, cell death throughout

**Figure 12-13** Postmortem angiogram showing the posterior aspect of the heart of a patient who died during the evolution of acute myocardial infarction, demonstrating total occlusion of the distal right coronary artery by an acute thrombus (*arrow*) and a large zone of myocardial hypoperfusion involving the posterior left and right ventricles, as indicated by arrowheads, and having almost absent filling of capillaries, that is, less white. The heart has been fixed by coronary arterial perfusion with glutaraldehyde and cleared with methyl salicylate, followed by intracoronary injection of silicone polymer. *Photograph courtesy of Lewis L. Lainey. (Reproduced by permission from Schoen FJ: Interventional and Surgical Cardiovascular Pathology: Clinical Correlations and Basic Principles. Philadelphia, WB Saunders, 1989, p. 60.)*





**TABLE 12-4 -- Approximate Time of Onset of Key Events in Ischemic Cardiac Myocytes**

Feature	Time
Onset of ATP depletion	Seconds
Loss of contractility	<2 min
ATP reduced	
••to 50% of normal	10 min
••to 10% of normal	40 min
Irreversible cell injury	20–40 min
Microvascular injury	>1 hr
ATP, adenosine triphosphate.	

leading cause of mortality in IHD patients, can be caused by massive cell injury with mechanical failure but is most often due to ventricular fibrillation caused by myocardial irritability induced by ischemia or infarction. Interestingly, studies of resuscitated survivors of "sudden death" show that the majority do not develop acute MI; in such cases, myocardial irritability induced by ischemia presumably led directly to the serious arrhythmia.

The progression of ischemic necrosis in the myocardium is summarized in Figure 12-14 . Irreversible injury of ischemic myocytes occurs first in the subendocardial zone. With more extended ischemia, a *wavefront* of cell death moves through the myocardium to involve progressively more of the transmural thickness of the ischemic zone. The precise location, size, and specific morphologic features of an acute myocardial infarct depend on:

- The location, severity, and rate of development of coronary atherosclerotic obstructions
- The size of the vascular bed perfused by the obstructed vessels
- The duration of the occlusion
- The metabolic/oxygen needs of the myocardium at risk
- The extent of collateral blood vessels

- The presence, site, and severity of coronary arterial spasm
- Other factors, such as alterations in blood pressure, heart rate, and cardiac rhythm.

The necrosis is largely complete within 6 hours in experimental models and humans, involving nearly all of the ischemic myocardial bed at risk supplied by the occluded coronary artery. Progression of necrosis, however, may follow a more protracted course in some patients (possibly over 6 to 12 hours or longer) in whom the coronary arterial collateral system, stimulated by chronic ischemia, is better developed and thereby more effective.

#### **Morphology.**

The evolution of the morphologic changes in acute MI and its healing are summarized in Table 12-5 .

Nearly all transmural infarcts involve at least a portion of the left ventricle (including the ventricular septum). About 15% to 30% of those that affect the posterior free wall and posterior portion of the septum transmurally extend into the adjacent right ventricular wall. Isolated infarction of the right ventricle, however, occurs in only 1% to 3% of cases. Associated infarction of atrial tissue accompanies a large posterior left ventricular infarct in some cases. Transmural infarcts usually encompass nearly the entire perfusion zone of the occluded coronary artery. Almost always there is a narrow rim (approximately 0.1 mm) of preserved subendocardial myocardium sustained by diffusion of oxygen and nutrients from the lumen.

The frequencies of critical narrowing (and thrombosis) of each of the three main arterial trunks and the corresponding sites of myocardial lesions resulting in infarction (in the typical right dominant heart) are as follows:

- Left anterior descending coronary artery (40% to 50%): infarct involves anterior wall of left ventricle

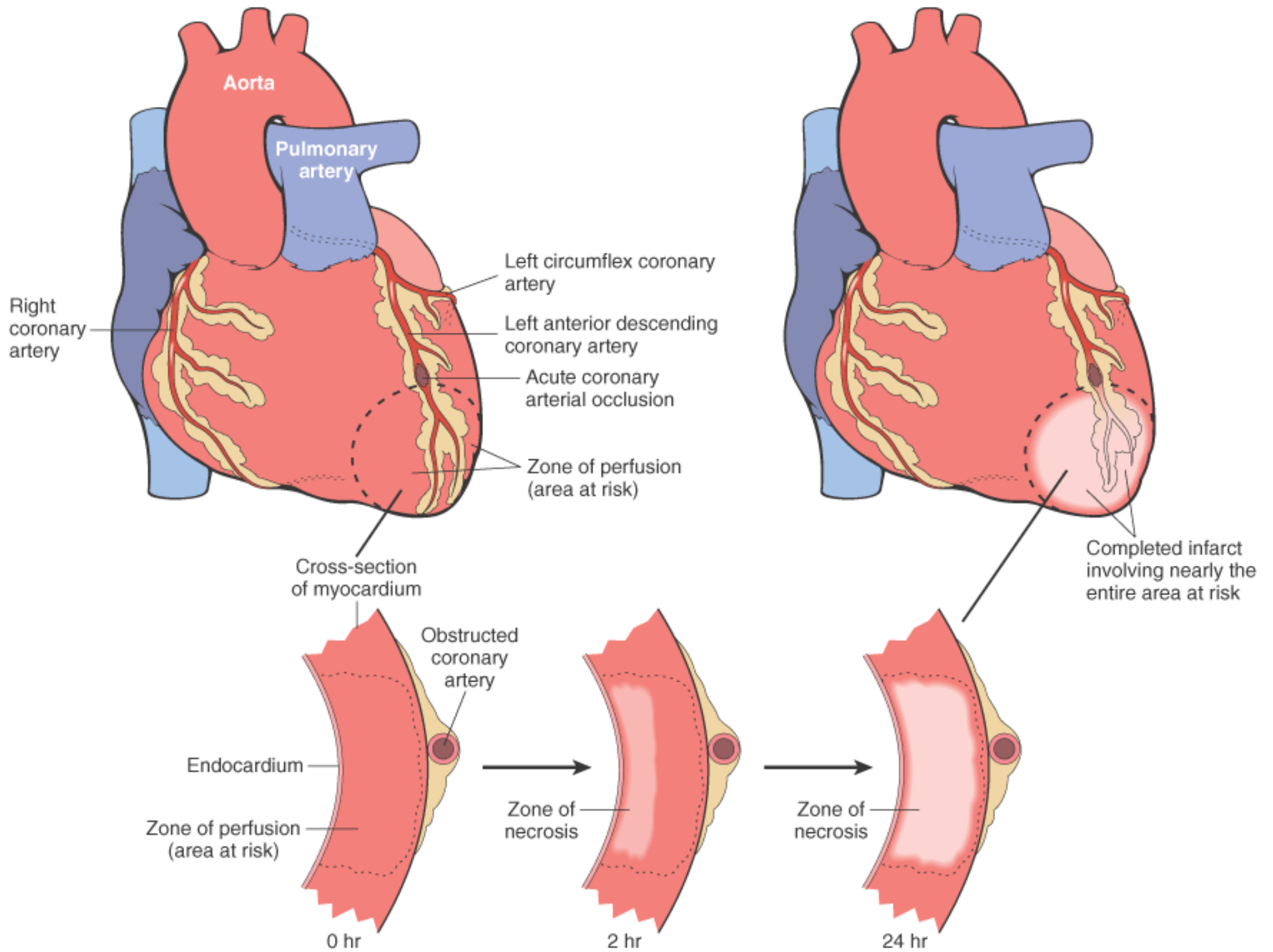
---

578

near apex; anterior portion of ventricular septum; apex circumferentially

- Right coronary artery (30% to 40%): infarct involves inferior/posterior wall of left ventricle; posterior portion of ventricular septum; inferior/posterior right ventricular free wall in some cases
- Left circumflex coronary artery (15% to 20%): infarct involves lateral wall of left ventricle except at apex

**Figure 12-14** Schematic representation of the progression of myocardial necrosis after coronary artery occlusion. Necrosis begins in a small zone of the myocardium beneath the endocardial surface in the center of the ischemic zone. This entire region of myocardium (*shaded*) depends on the occluded vessel for perfusion and is the area at risk. Note that a very narrow zone of myocardium immediately beneath the endocardium is spared from necrosis because it can be oxygenated by diffusion from the ventricle. The end result of the obstruction to blood flow is necrosis of the muscle that was dependent on perfusion from the coronary artery obstructed. Nearly the entire area at risk loses viability. The process is called *myocardial infarction*, and the region of necrotic muscle is a *myocardial infarct*.





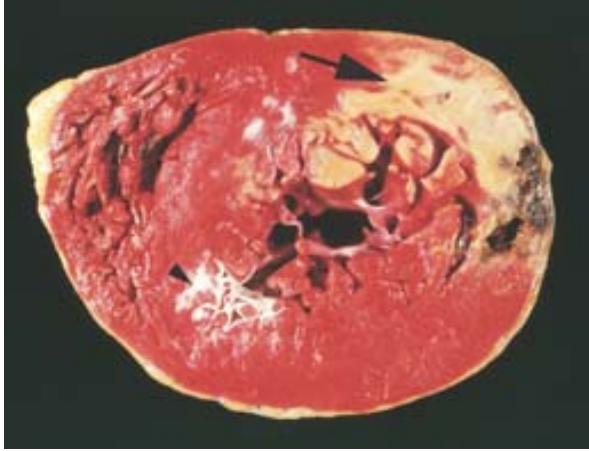
**TABLE 12-5 -- Evolution of Morphologic Changes in Myocardial Infarction**

Time	Gross Features	Light Microscope	Electron Microscope
<b><i>Reversible Injury</i></b>			
0–½ hr	None	None	Relaxation of myofibrils; glycogen loss; mitochondrial swelling
<b><i>Irreversible Injury</i></b>			
½–4 hr	None	Usually none; variable waviness of fibers at border	Sarcolemmal disruption; mitochondrial amorphous densities
4–12 hr	Occasionally dark mottling	Beginning coagulation necrosis; edema; hemorrhage	
12–24 hr	Dark mottling	Ongoing coagulation necrosis; pyknosis of nuclei; myocyte hypereosinophilia; marginal contraction band necrosis; beginning neutrophilic infiltrate	
1–3 days	Mottling with yellow-tan infarct center	Coagulation necrosis, with loss of nuclei and striations; interstitial infiltrate of neutrophils	
3–7 days	Hyperemic border; central yellow-tan softening	Beginning disintegration of dead myofibers, with dying neutrophils; early phagocytosis of dead cells by macrophages at infarct border	
7–10 days	Maximally yellow-tan and soft, with depressed red-tan margins	Well-developed phagocytosis of dead cells; early formation of fibrovascular granulation tissue at margins	
10–14 days	Red-gray depressed infarct borders	Well-established granulation tissue with new blood vessels and collagen deposition	
2–8 wk	Gray-white scar, progressive from border toward core of infarct	Increased collagen deposition, with decreased cellularity	
>2 mo	Scarring complete	Dense collagenous scar	

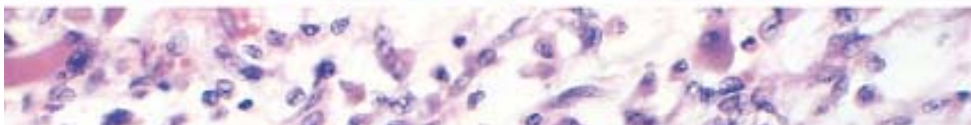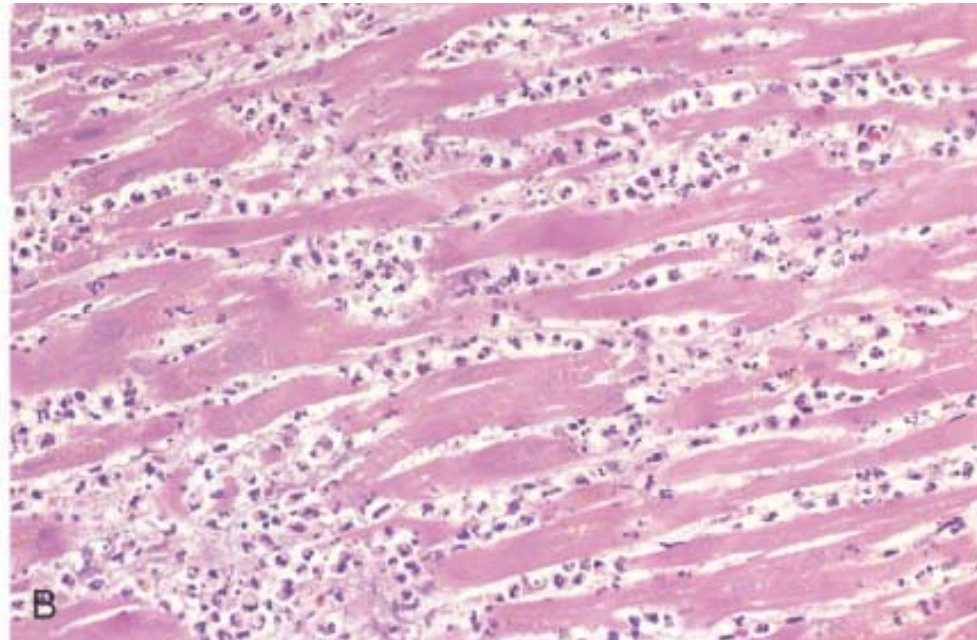
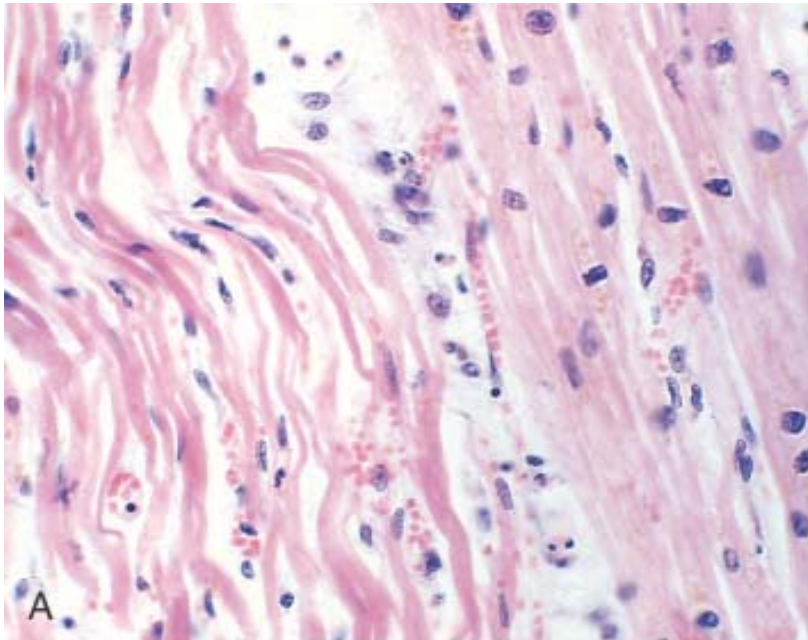
solution of *triphenyltetrazolium chloride* (TTC). This histochemical stain imparts a brick-red color to intact, noninfarcted myocardium where the dehydrogenase enzymes are preserved. Because dehydrogenases are depleted in the area of ischemic necrosis (they leak out through the damaged cell membranes), an infarcted area is revealed as an unstained pale zone (while old scarred infarcts appear white and glistening) ( Fig. 12-15 ). Subsequently, by 12 to 24 hours, an infarct can be identified in routinely fixed gross slices owing to a red-blue hue caused by stagnated, trapped blood. Progressively thereafter, the infarct becomes a more sharply defined, yellow-tan, somewhat softened area that by 10 days to 2 weeks is rimmed by a hyperemic zone of highly vascularized granulation tissue. Over the succeeding weeks, the injured region evolves to a fibrous scar.

The histopathologic changes also have a fairly predictable sequence (summarized in Table 12-5 and Figure 12-16 ). Using light microscopic examination of routinely stained tissue sections, the typical changes of coagulative necrosis become detectable variably in the first 4 to 12 hours. "Wavy fibers" may be present at the periphery of the infarct; these changes probably result from the forceful systolic tugs by the viable fibers immediately adjacent to the noncontractile dead fibers, thereby stretching and buckling them. An additional but sublethal ischemic change may be seen in the margins of infarcts: so-called vacuolar degeneration or **myocytolysis**, involving large vacuolar spaces within cells, probably containing water. This potentially reversible alteration is particularly frequent in the thin zone of viable subendocardial cells. Subendocardial

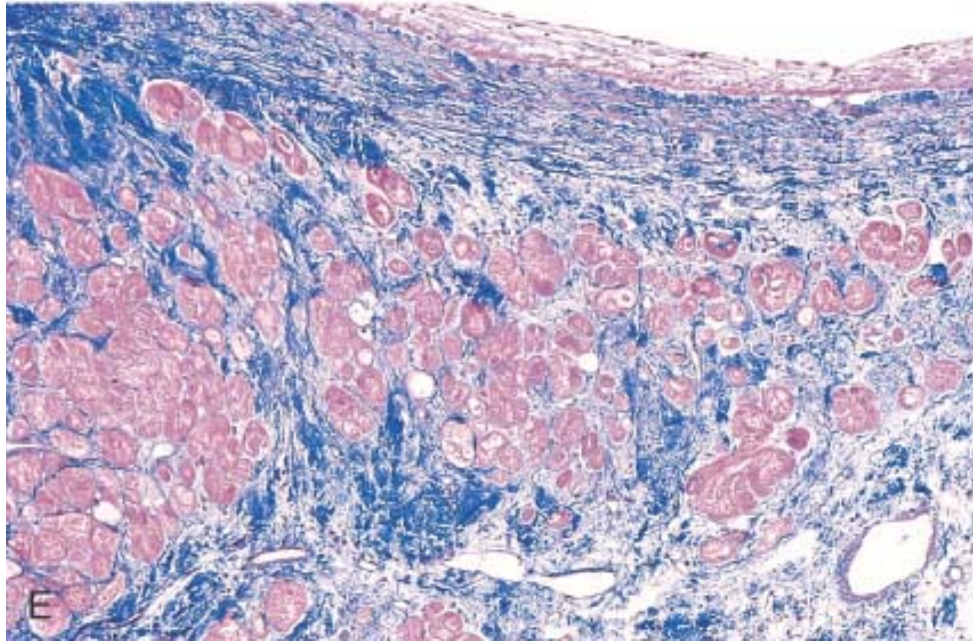
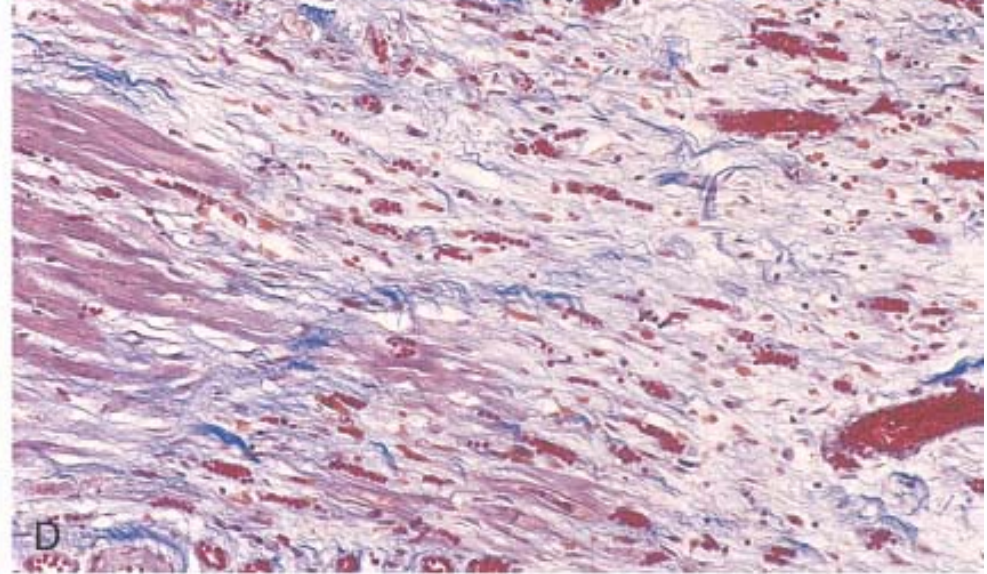
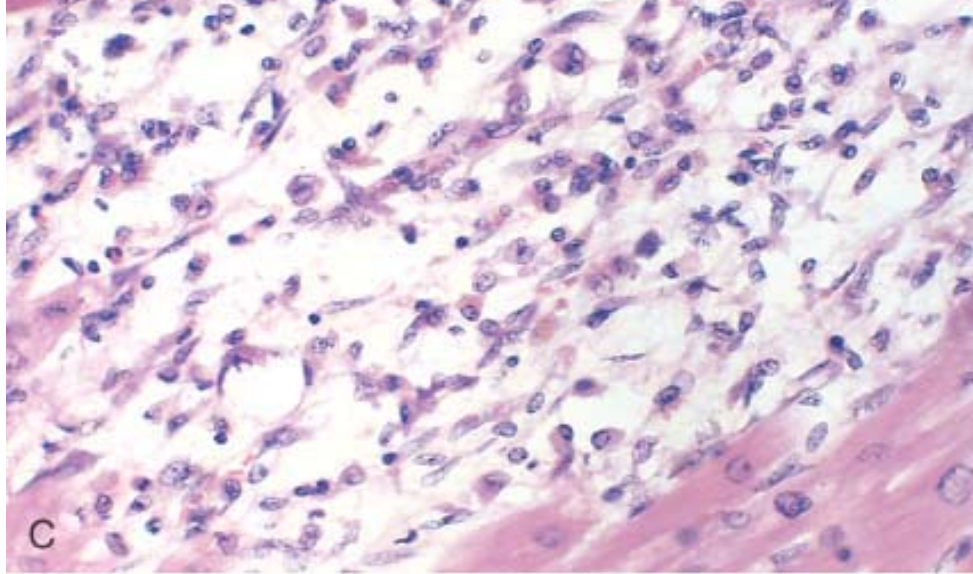
**Figure 12-15** Acute myocardial infarct, predominantly of the posterolateral left ventricle, demonstrated histochemically by a lack of staining by the triphenyltetrazolium chloride (TTC) stain in areas of necrosis (*arrow*). The staining defect is due to the enzyme leakage that follows cell death. Note the myocardial hemorrhage at one edge of the infarct that was associated with cardiac rupture, and the anterior scar (*arrowhead*), indicative of old infarct. (Specimen the oriented with the posterior wall at the top.)



**Figure 12-16** Microscopic features of myocardial infarction and its repair. *A*, One-day-old infarct showing coagulative necrosis along with wavy fibers (elongated and narrow), compared with adjacent normal fibers (at right). Widened spaces between the dead fibers contain edema fluid and scattered neutrophils. *B*, Dense polymorphonuclear leukocytic infiltrate in area of acute myocardial infarction of 3 to 4 days' duration. *C*, Nearly complete removal of necrotic myocytes by phagocytosis (approximately 7 to 10 days). *D*, Granulation tissue characterized by loose collagen and abundant capillaries. *E*, Well-healed myocardial infarct with replacement of the necrotic fibers by dense collagenous scar. A few residual cardiac muscle cells are present.

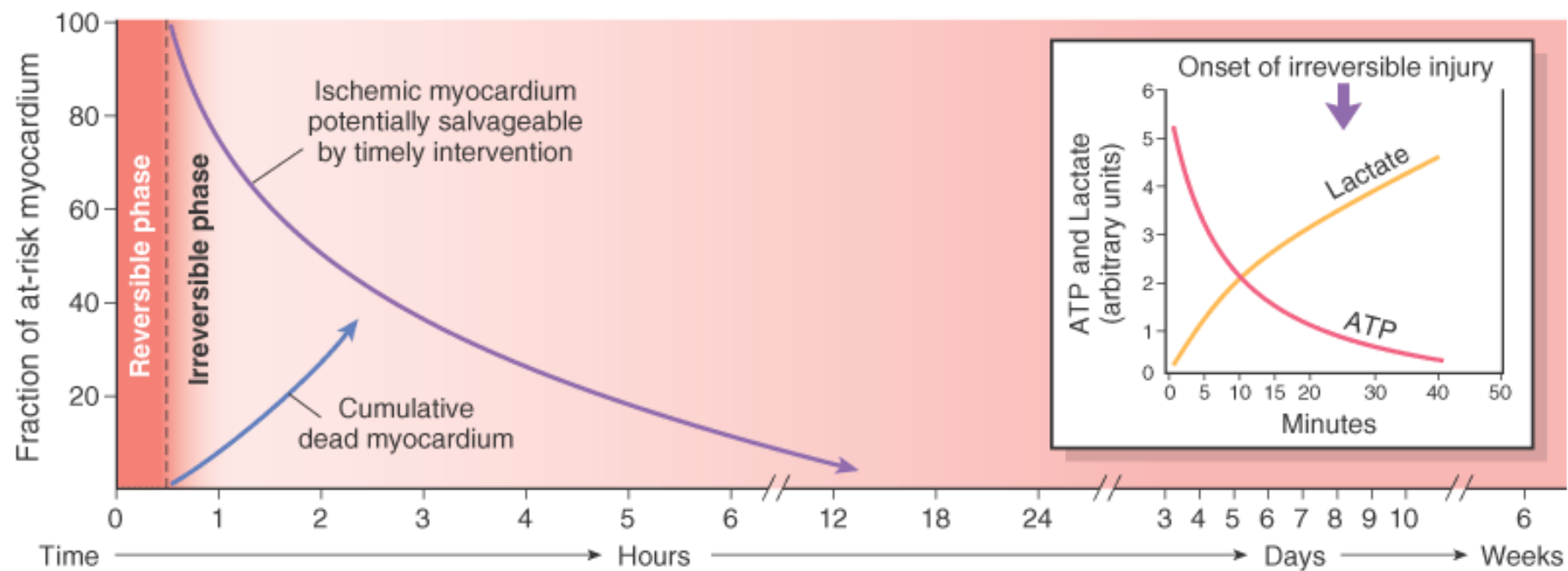






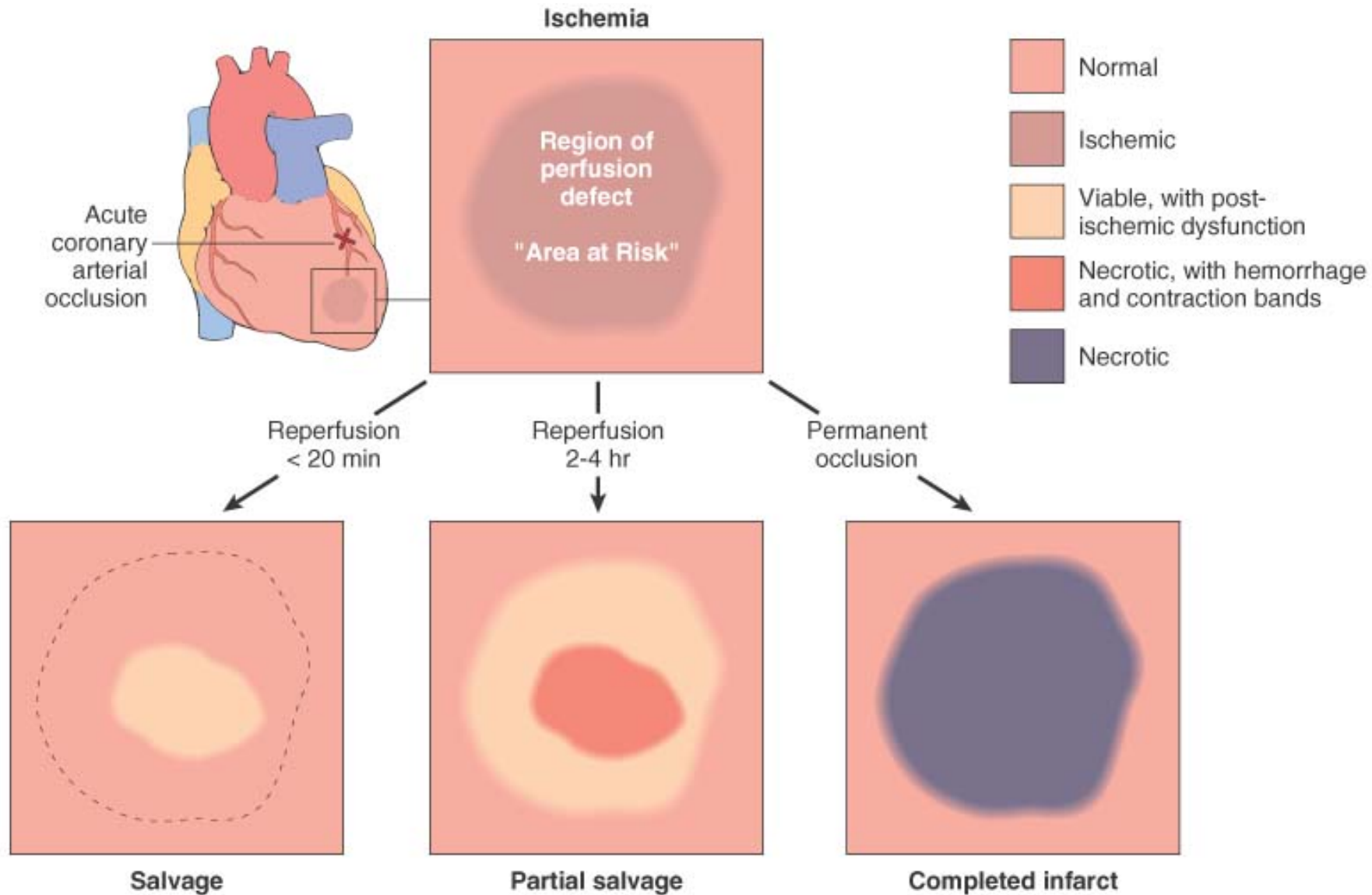
**Figure 12-17** Temporal sequence of early biochemical, ultrastructural, histochemical, and histologic findings after onset of severe myocardial ischemia. For approximately 30 minutes after the onset of even the most severe ischemia, myocardial injury is potentially reversible. Thereafter, progressive loss of viability occurs that is complete by 6 to 12 hours. The benefits of reperfusion are greatest when it is achieved early, with progressively smaller benefit occurring as reperfusion is delayed. (*Modified with permission from Antman E: Acute myocardial infarction. In Braunwald E, Zipes DP, Libby P (eds): Heart Disease: A Textbook of Cardiovascular Medicine, 6th ed. Philadelphia, WB Saunders, 2001, pp. 1114–1231.*)



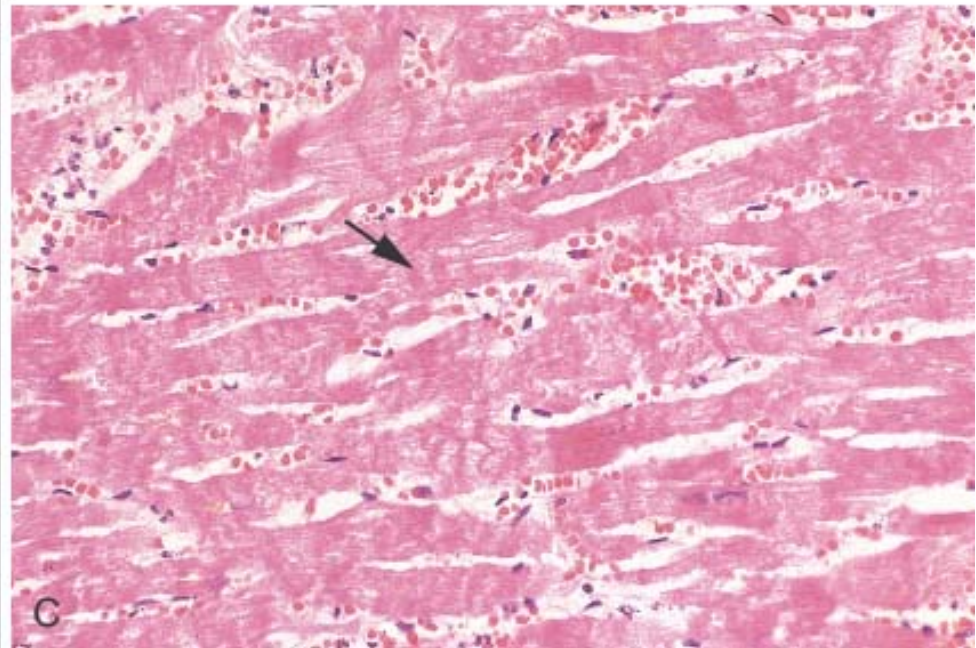
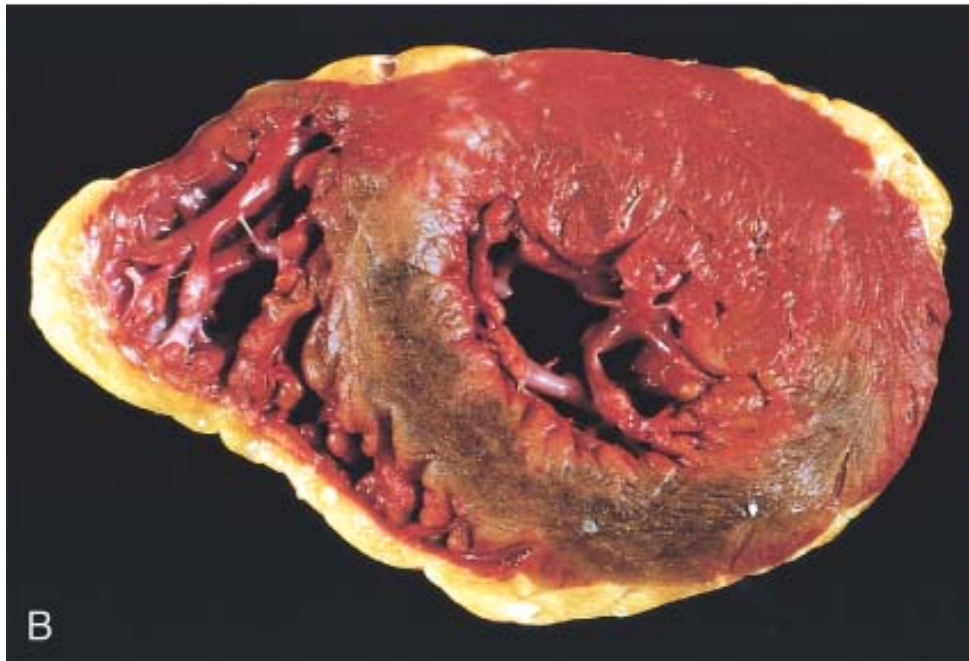

Electron microscopy	<b>Reversible phase:</b> Glycogen depletion; mitochondrial swelling and relaxation of myofibrils <b>Irreversible phase:</b> Sarcolemmal disruption; mitochondrial amorphous densities						
Histochemistry	TTC staining defect						
Light microscopy	Waviness of fibers at border	Beginning coagulation necrosis; edema; focal hemorrhage; beginning neutrophilic infiltrate	Continuing coagulation necrosis; pallor (shrunken nuclei and eosinophilic cytoplasm); myocyte contraction bands	Coagulation necrosis with loss of nuclei and striations; neutrophilic infiltrate	Disintegration of myofibers and phagocytosis by macrophages	Completion of phagocytosis; prominent granulation tissue with neovascularization and fibrovascular reaction	Mature fibrous scar
Gross changes			Pallor	Pallor, sometimes hyperemia; yellowing at periphery	Hyperemic border; central yellow-brown softening	Maximally yellow and soft vascularized edges; red-brown and depressed	

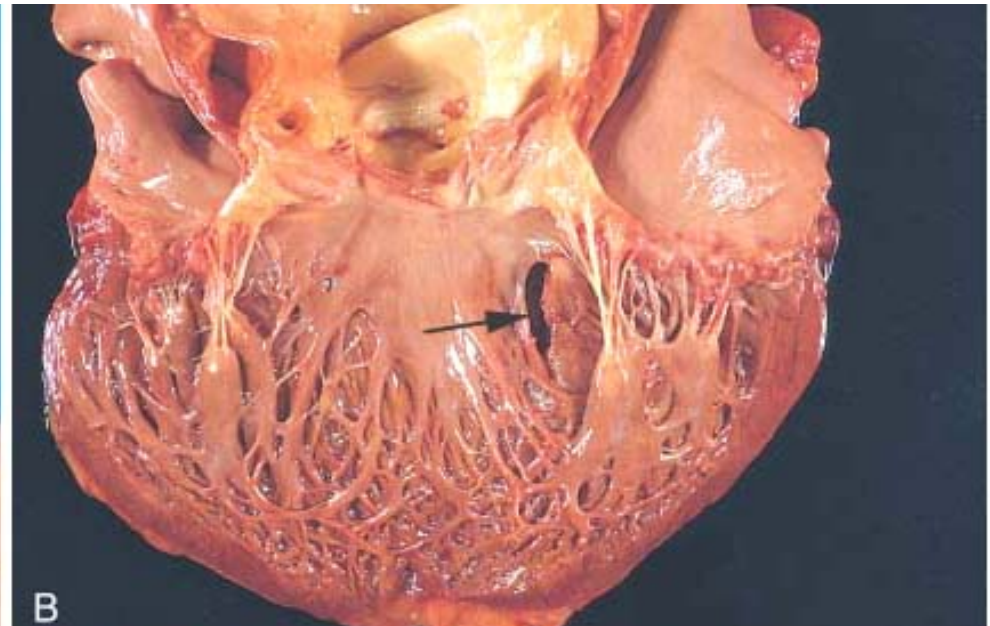
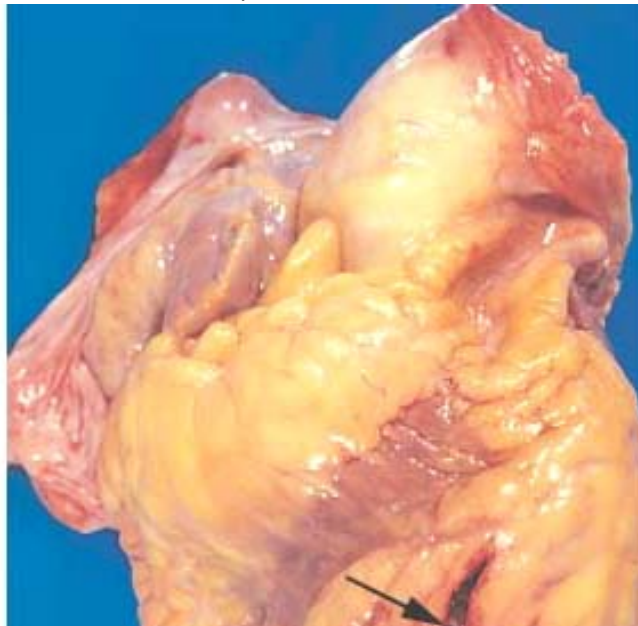
**Figure 12-18** Consequences of myocardial ischemia followed by reperfusion. *A*, Schematic illustration of the progression of myocardial ischemic injury and its modification by restoration of flow (reperfusion). Hearts suffering brief periods of ischemia of <20 minutes followed by reperfusion do not develop necrosis (reversible injury). Brief ischemia followed by reperfusion results in stunning. If coronary occlusion is extended beyond 20 minutes' duration, a wavefront of necrosis progresses from subendocardium to subepicardium over time. Reperfusion before 3 to 6 hours of ischemia salvages ischemic but viable tissue. (This salvaged tissue may demonstrate stunning.) Reperfusion beyond 6 hours does not appreciably reduce myocardial infarct size. Late reperfusion may still have a beneficial effect on reducing or preventing myocardial infarct expansion and left ventricular remodeling. *B*, Gross and *C*, microscopic appearance of myocardium modified by reperfusion. *B*, Large, densely hemorrhagic, anterior wall acute myocardial infarction from patient with left anterior descending artery thrombus treated with streptokinase intracoronary thrombolysis (triphenyl tetrazolium chloride-stained heart slice). (Specimen oriented with posterior wall at top.) *C*, Myocardial necrosis with hemorrhage and contraction bands, visible as dark bands spanning some myofibers (arrow). This is the characteristic appearance of markedly ischemic myocardium that has been reperfused.



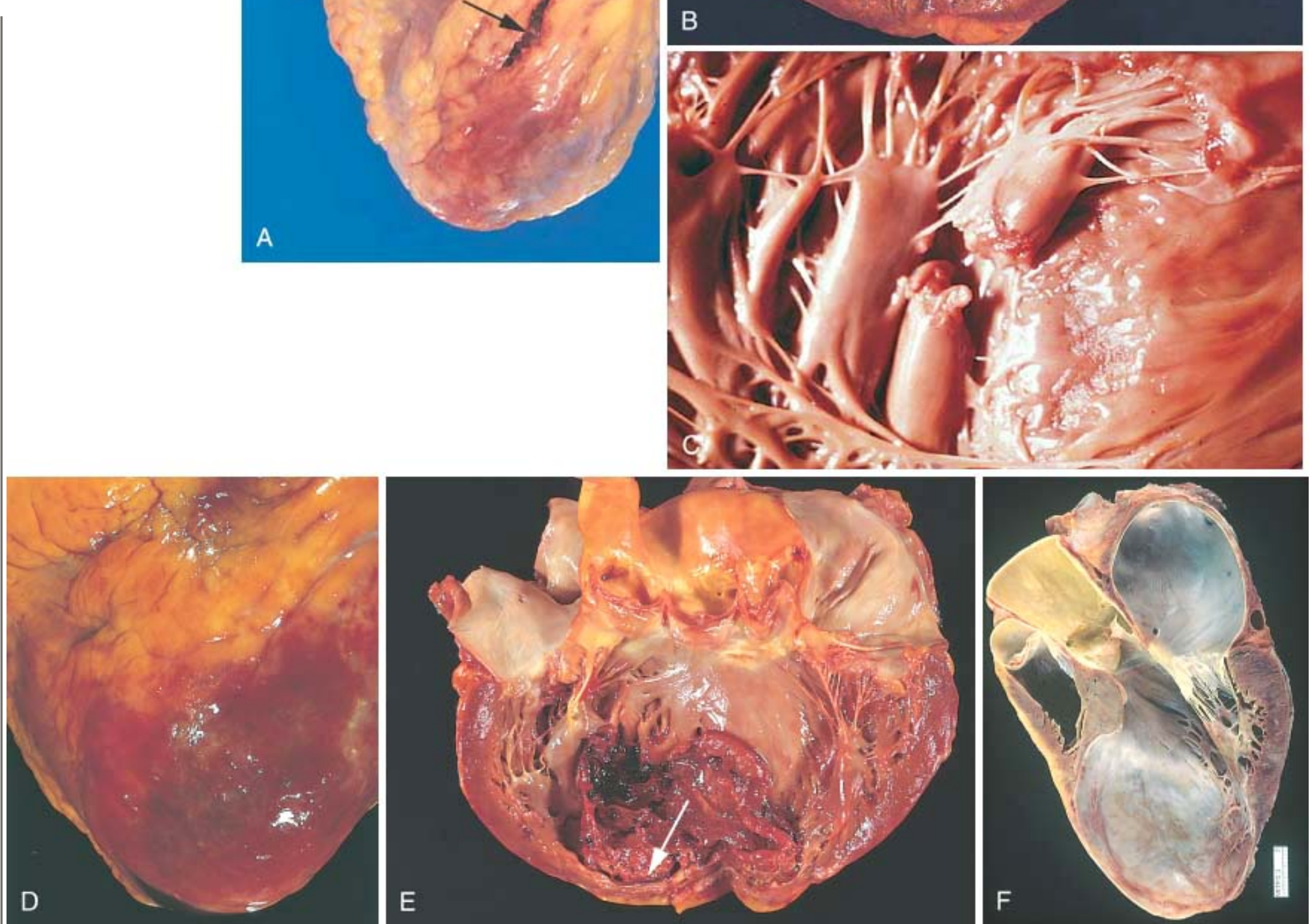
A



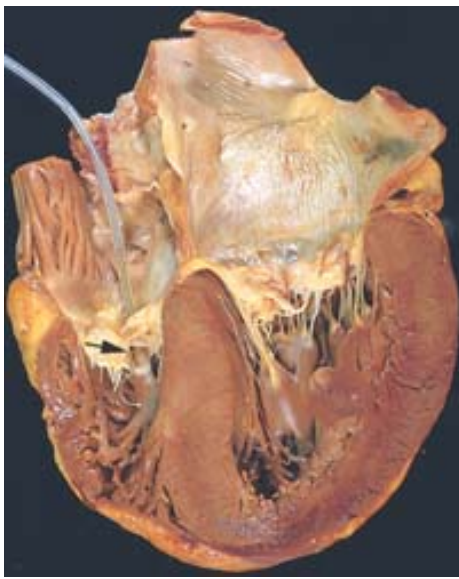**Figure 12-19** Complications of myocardial infarction. Cardiac rupture syndromes (A, B, and C). A, Anterior myocardial rupture in an acute infarct (*arrow*). B, Rupture of the ventricular septum (*arrow*). C, Complete rupture of a necrotic papillary muscle. D, Fibrinous pericarditis, showing a dark, roughened epicardial surface overlying an acute infarct. E, Early expansion of anteroapical infarct with wall thinning (*arrow*) and mural thrombus. F, Large apical left ventricular aneurysm. The left ventricle is on the right in this apical four-chamber view of the heart. (A–E, Reproduced by permission from Schoen FJ: *Interventional and Surgical Cardiovascular Pathology: Clinical Correlations and Basic Principles*, Philadelphia, WB Saunders, 1989.) (F, Courtesy of William D. Edwards, M.D., Mayo Clinic, Rochester, MN.)







**Figure 12-20** Hypertensive heart disease with marked concentric thickening of the left ventricular wall causing reduction in lumen size. The left ventricle is on the right in this apical four-chamber view of the heart. A pacemaker is incidentally present in the right ventricle (*arrow*).

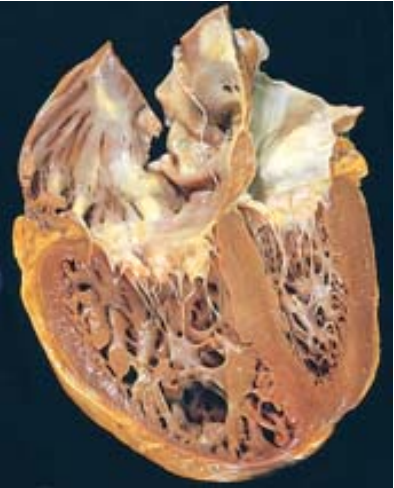

**TABLE 12-6 -- Disorders Predisposing to Cor Pulmonale**

<b><i>Diseases of the Pulmonary Parenchyma</i></b>
Chronic obstructive pulmonary disease
Diffuse pulmonary interstitial fibrosis
Pneumoconioses
Cystic fibrosis
Bronchiectasis
<b><i>Diseases of the Pulmonary Vessels</i></b>
Recurrent pulmonary thromboembolism
Primary pulmonary hypertension
Extensive pulmonary arteritis (e.g., Wegener granulomatosis)
Drug-, toxin-, or radiation-induced vascular obstruction
Extensive pulmonary tumor microembolism
<b><i>Disorders Affecting Chest Movement</i></b>
Kyphoscoliosis
Marked obesity (pickwickian syndrome)
Neuromuscular diseases
<b><i>Disorders Inducing Pulmonary Arterial Constriction</i></b>

Metabolic acidosis
Hypoxemia
Chronic altitude sickness
Obstruction to major airways
Idiopathic alveolar hypoventilation

**Figure 12-21** Chronic cor pulmonale, characterized by a markedly dilated and hypertrophied right ventricle, with thickened free wall and hypertrophied trabeculae (apical four-chamber view of heart, right ventricle on left). The shape of the left ventricle (to the right) has been distorted by the right ventricular enlargement. Compare with Figure 12-20 .



**TABLE 12-7 -- Major Etiologies of Acquired Heart Valve Disease**

Mitral Valve Disease	Aortic Valve Disease
<i>Mitral Stenosis</i>	<i>Aortic Stenosis</i>
Postinflammatory scarring (rheumatic heart disease)	Postinflammatory scarring (rheumatic heart disease)
	Senile calcific aortic stenosis
	Calcification of congenitally deformed valve
<i>Mitral Regurgitation</i>	<i>Aortic Regurgitation</i>
<i>Abnormalities of Leaflets and Commissures</i>	<i>Intrinsic Valvular Disease</i>
Postinflammatory scarring	Postinflammatory scarring (rheumatic heart disease)
Infective endocarditis	Infective endocarditis
Mitral valve prolapse	



Fen-phen-induced valvular fibrosis	
<b><i>Abnormalities of Tensor Apparatus</i></b>	<b><i>Aortic Disease</i></b>
Rupture of papillary muscle	Degenerative aortic dilation
Papillary muscle dysfunction (fibrosis)	Syphilitic aortitis
Rupture of chordae tendineae	Ankylosing spondylitis
	Rheumatoid arthritis
	Marfan syndrome
<b><i>Abnormalities of Left Ventricular Cavity and/or Annulus</i></b>	
LV enlargement (myocarditis, dilated cardiomyopathy)	
Calcification of mitral ring	
LV, Left ventricular.	
<i>Modified from Schoen, FJ: Surgical pathology of removed natural and prosthetic valves. Hum Pathol 18:558, 1987.</i>	

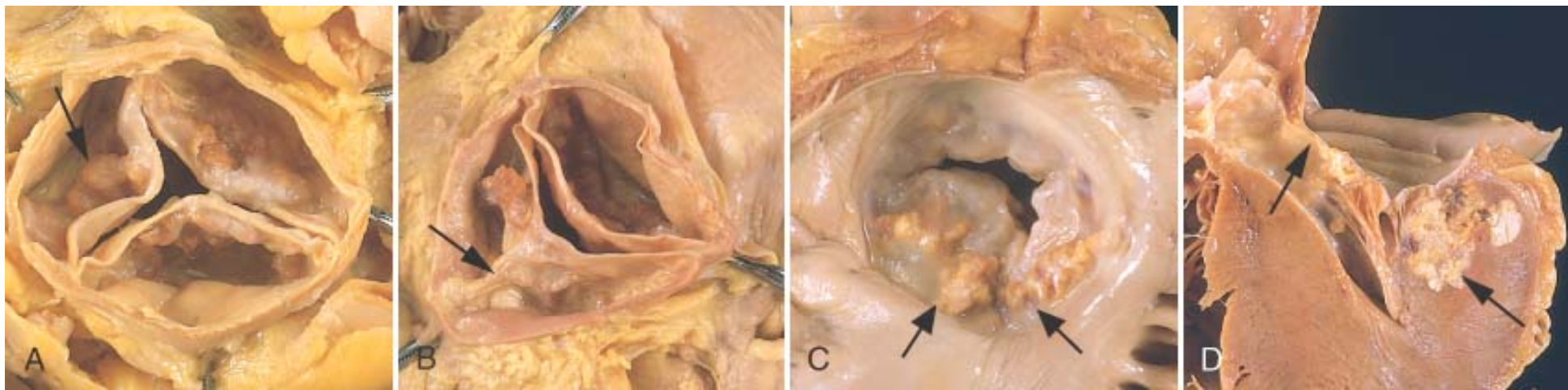
valvular insufficiency, only a relatively few mechanisms produce acquired valvular stenosis. The most frequent causes of the major functional valvular lesions are as follows:

- Aortic stenosis: calcification of anatomically normal and congenitally bicuspid aortic valves
- Aortic insufficiency: dilation of the ascending aorta, related to hypertension and aging.
- Mitral stenosis: rheumatic heart disease
- Mitral insufficiency: myxomatous degeneration (mitral valve prolapse)

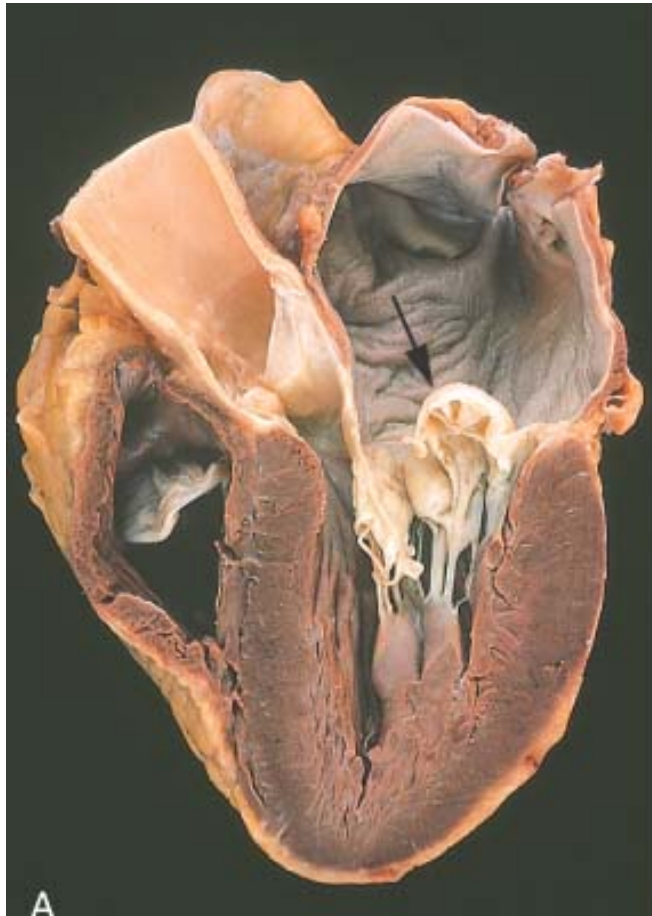
**VALVULAR DEGENERATION CAUSED BY CALCIFICATION**

The heart valves are subjected to high repetitive mechanical stresses, particularly at the hinge points of the cusps and leaflets owing to (1) 40 million or more cardiac cycles per year, (2) substantial tissue deformations at each cycle, and (3) transvalvular pressure gradients in the closed phase of approximately 120 mm for the mitral and 80 mm for the aortic valve. It is therefore not surprising that these normally delicate structures suffer cumulative damage complicated by formation of calcific deposits (composed of calcium phosphate mineral), which may lead to clinically important disease (see Chapter 1 ). The most frequent calcific valvular diseases, illustrated in Figure 12-22 , are calcific aortic stenosis, calcification of a congenitally bicuspid aortic valve, and mitral annular calcification. Each comprises primarily dystrophic calcification without significant lipid deposition or cellular proliferation, a process distinct from but with some features of atherosclerosis.

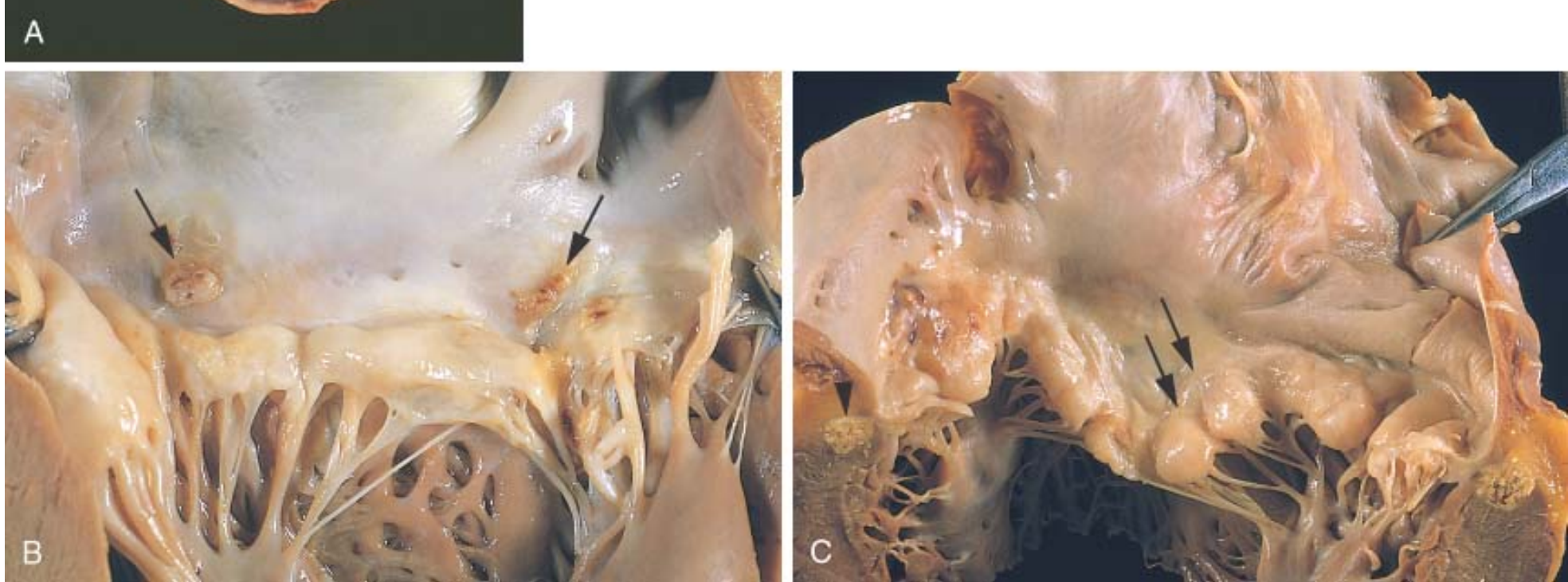
**Figure 12-22** Calcific valvular degeneration. *A*, Calcific aortic stenosis of a previously normal valve having three cusps (viewed from aortic aspect). Nodular masses of calcium are heaped-up within the sinuses of Valsalva (*arrow*). Note that the commissures are not fused, as in post-rheumatic aortic valve stenosis (see Fig. 12-24*E* ). *B*, Calcific aortic stenosis occurring on a congenitally bicuspid valve. One cusp has a partial fusion at its center, called a *raphe* (*arrow*). *C and D*, Mitral annular calcification, with calcific nodules at the base (attachment margin) of the anterior mitral leaflet (*arrows*). *C*, Left atrial view. *D*, Cut section of myocardium.



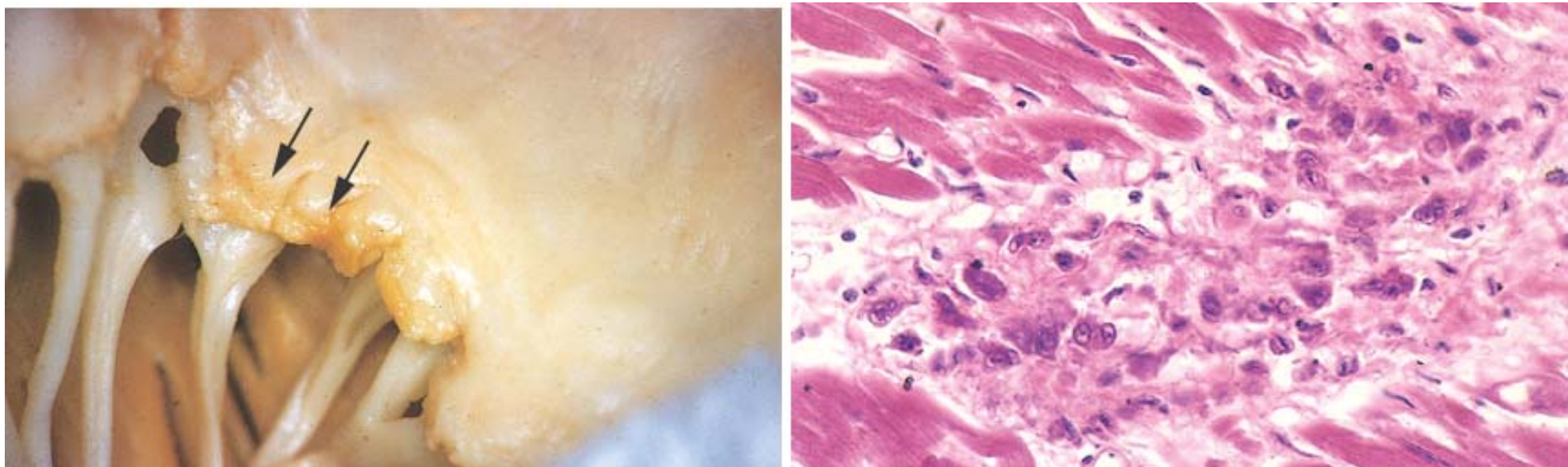
**Figure 12-23** Myxomatous degeneration of the mitral valve. *A*, Long axis of left ventricle demonstrating hooding with prolapse of the posterior mitral leaflet into the left atrium (*arrow*). The left ventricle is on right in this apical four-chamber view. (*Courtesy of William D. Edwards, M.D., Mayo Clinic, Rochester, MN.*) *B*, Opened valve, showing pronounced hooding of the posterior mitral leaflet with thrombotic plaques at sites of leaflet-left atrium contact (*arrows*). *C*, Opened valve with pronounced hooding from patient who died suddenly (*double arrows*). Note also mitral annular calcification (*arrowhead*).



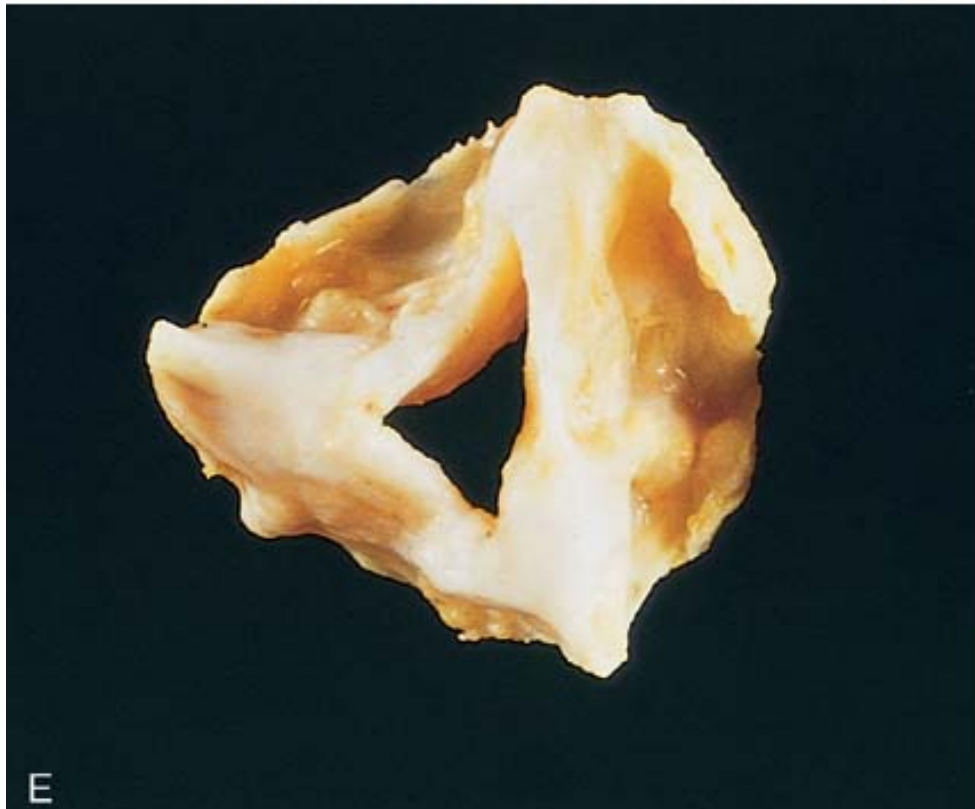
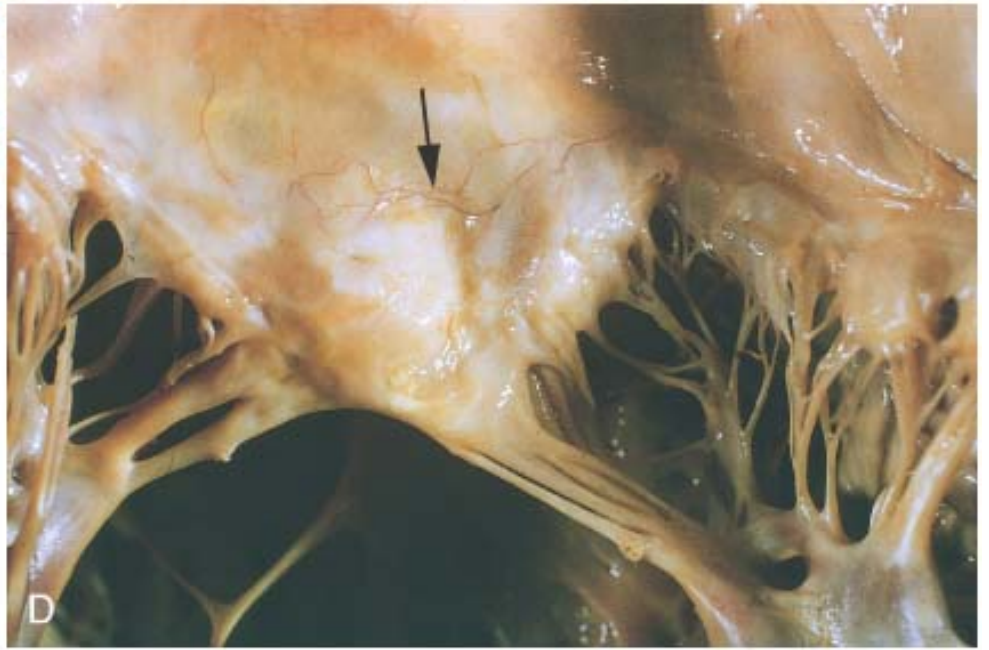
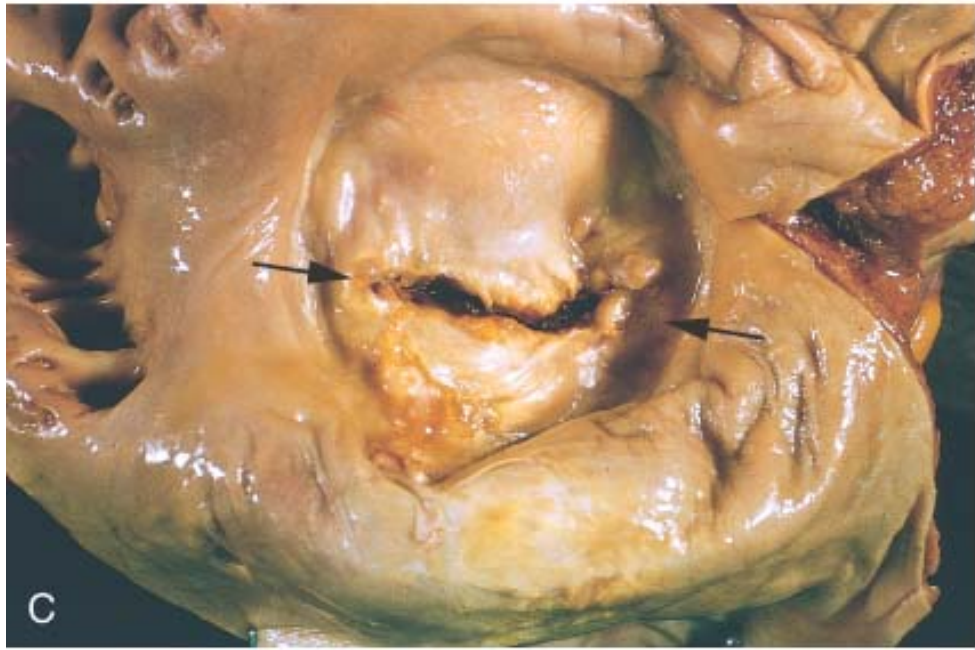




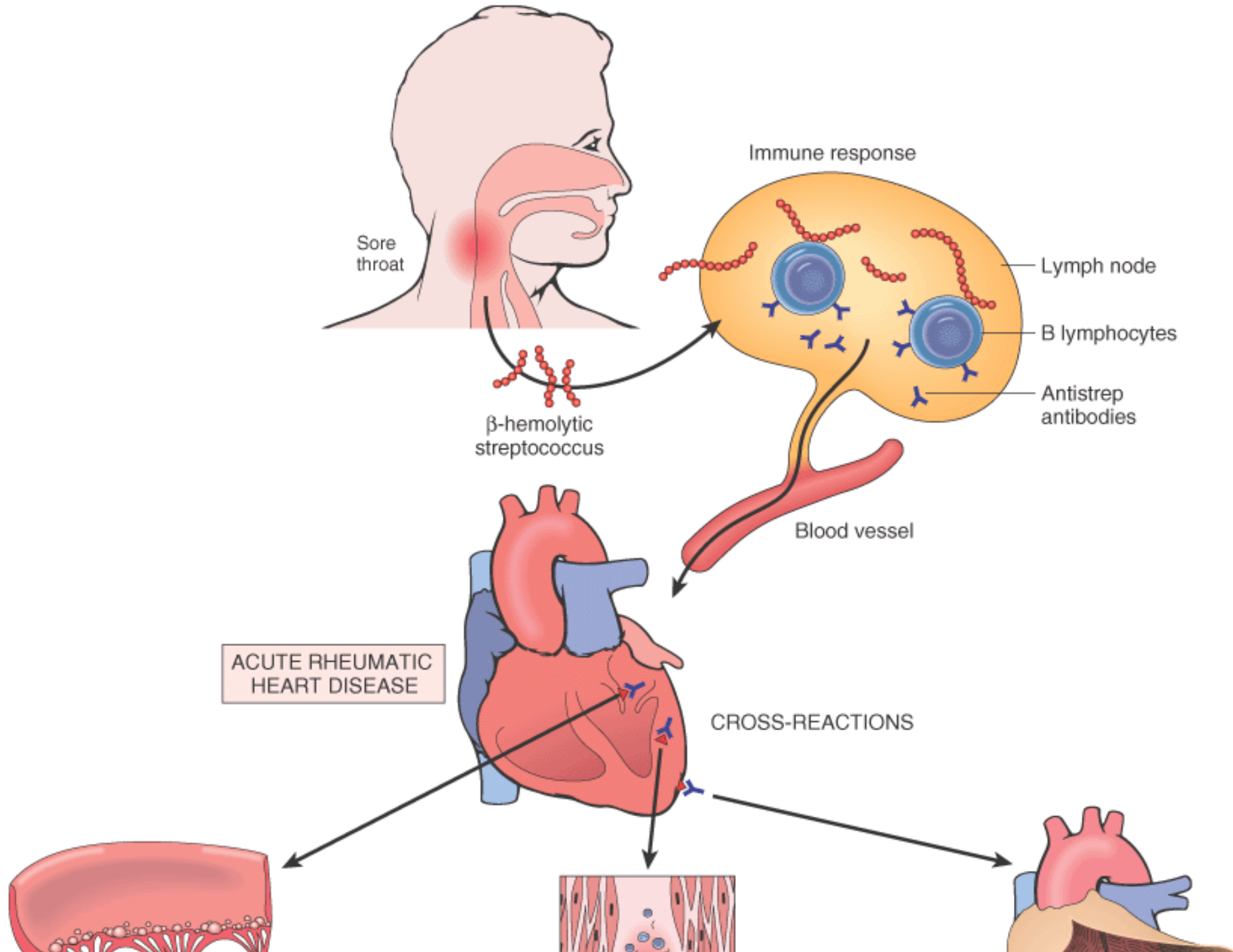
**Figure 12-24** Acute and chronic rheumatic heart disease. *A*, Acute rheumatic mitral valvulitis superimposed on chronic rheumatic heart disease. Small vegetations (verrucae) are visible along the line of closure of the mitral valve leaflet (*arrows*). Previous episodes of rheumatic valvulitis have caused fibrous thickening and fusion of the chordae tendineae. *B*, Microscopic appearance of Aschoff body in a patient with acute rheumatic carditis. The myocardial interstitium has a circumscribed collection of mononuclear inflammatory cells, including some large histiocytes with prominent nucleoli and a prominent binuclear histiocyte, and central necrosis. *C and D*, Mitral stenosis with diffuse fibrous thickening and distortion of the valve leaflets, commissural fusion (*arrows*), and thickening and shortening of the chordae tendineae. Marked dilation of the left atrium is noted in the left atrial view (*C*). *D*, Opened valve. Note neovascularization of anterior mitral leaflet (*arrow*). *E*, Surgically removed specimen of rheumatic aortic stenosis, demonstrating thickening and distortion of the cusps with commissural fusion (*E*, reproduced from Schoen FJ, St. John-Sutton M: *Contemporary issues in the pathology of valvular heart disease. Human Pathol* 18:568, 1967.)

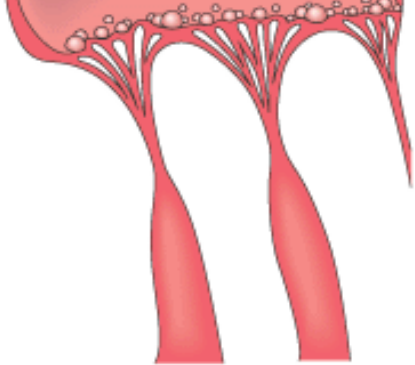




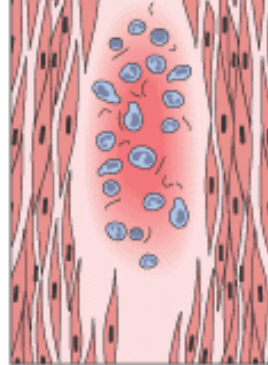


**Figure 12-25** The pathogenetic sequence and key morphologic features of acute rheumatic heart disease.

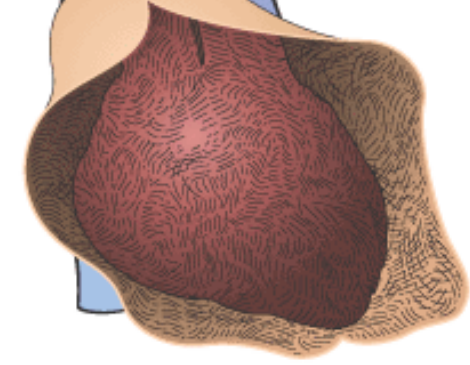




Vegetations



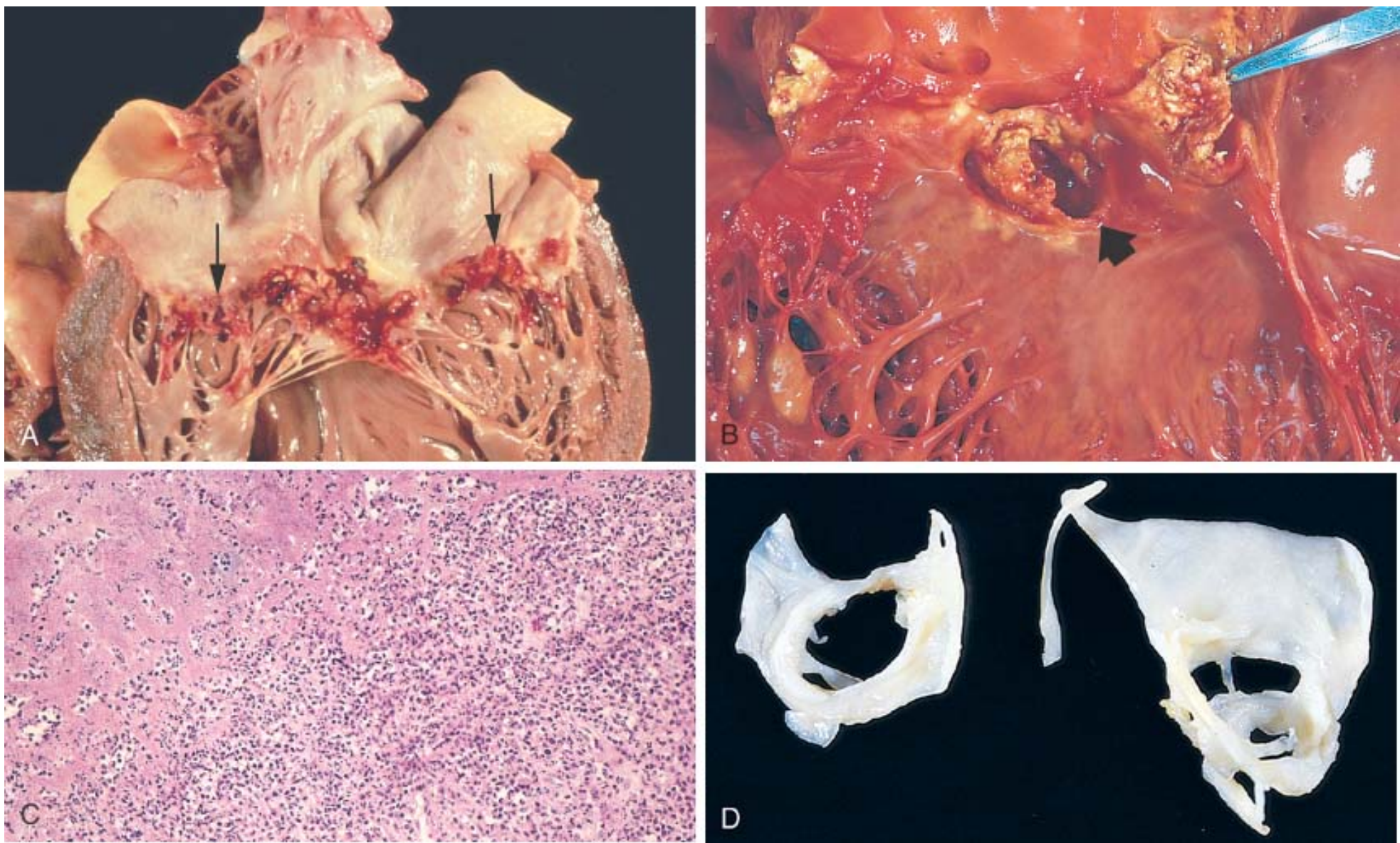
Myocardial Aschoff body



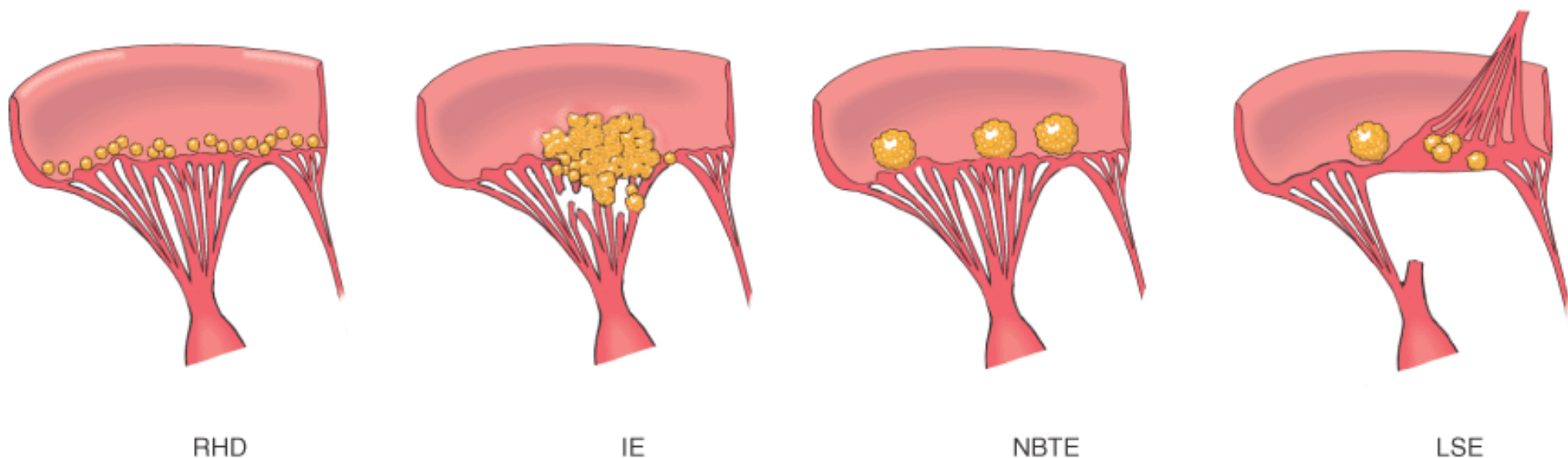
Fibrinous pericarditis

**Figure 12-26** Infective (bacterial) endocarditis. *A*, Endocarditis of mitral valve (subacute, caused by *Strep. viridans*). The large, friable vegetations are denoted by arrows. *B*, Acute endocarditis of congenitally bicuspid aortic valve (caused by *Staph. aureus*) with extensive cuspal destruction and ring abscess (*arrow*). *C*, Histologic appearance of vegetation of endocarditis with extensive acute inflammatory cells and fibrin. Bacterial organisms were demonstrated by tissue Gram stain. (*C*, reproduced from Schoen FJ: *Surgical pathology of removed natural and prosthetic heart valves. Human Pathol* 18:558, 1987.) *D*, Healed endocarditis, demonstrating mitral valvular destruction but no active vegetations.





**Figure 12-27** Diagrammatic comparison of the lesions in the four major forms of vegetative endocarditis. The rheumatic fever phase of RHD (rheumatic heart disease) is marked by a row of small, warty vegetations along the lines of closure of the valve leaflets. IE (infective endocarditis) is characterized by large, irregular masses on the valve cusps that can extend onto the chordae (see Fig. 12-26 ). NBTE (nonbacterial thrombotic endocarditis) typically exhibits small, bland vegetations, usually attached at the line of closure. One or many may be present (see Fig. 12-28 ). LSE (Libman-Sacks endocarditis) has small or medium-sized vegetations on either or both sides of the valve leaflets.



**TABLE 12-8** -- Diagnostic Criteria for Infective Endocarditis \*

***Pathologic Criteria***

Microorganisms, demonstrated by culture or histologic examination, in a vegetation, embolus from a vegetation, or intracardiac abscess

Histologic confirmation of active endocarditis in vegetation or intracardiac abscess

***Clinical Criteria***

**Major**

Positive blood culture(s) indicating characteristic organism or persistence of unusual organism

Echocardiographic findings, including valve-related or implant-related mass or abscess, or partial separation of artificial valve

New valvular regurgitation

**Minor**

Predisposing heart lesion or intravenous drug use

Fever

Vascular lesions, including arterial petechiae, subungual/splinter hemorrhages, emboli, septic infarcts, mycotic aneurysm, intracranial hemorrhage, Janeway lesions <sup>†</sup>

Immunologic phenomena, including glomerulonephritis, Osler nodes, <sup>‡</sup> Roth spots, <sup>§</sup> rheumatoid factor

Microbiologic evidence, including single culture showing uncharacteristic organism

Echocardiographic findings consistent with but not diagnostic of endocarditis, including new valvular regurgitation, pericarditis

\*Diagnosis by these guidelines, often called the Duke Criteria, requires either pathologic or clinical criteria; if clinical criteria are used, 2 major, 1 major + 3 minor, or 5 minor criteria are required for diagnosis. Modified from Durack DT, et al: *Am J Med*, 96:200, 1994 and Karchmer AW, In Braunwald E, Zipes DP, Libby P (eds): *Heart Disease. A Textbook of*

*Cardiovascular Medicine, 6th ed. Philadelphia, WB Saunders Co., 2001, p. 1723.*

†Janeway lesions are small erythematous or hemorrhagic, macular, nontender lesions on the palms and soles and are the consequence of septic embolic events.

‡Osler nodes are small, tender subcutaneous nodules that develop in the pulp of the digits or occasionally more proximally in the fingers and persist for hours to several days.

§Roth spots are oval retinal hemorrhages with pale centers.

## NONINFECTED VEGETATIONS

### Nonbacterial Thrombotic Endocarditis (NBTE)

*NBTE is characterized by the deposition of small masses of fibrin, platelets, and other blood components on the leaflets of the cardiac valves.* In contrast to the vegetations of IE, discussed previously, *the valvular lesions of NBTE are sterile and do not contain microorganisms.* NBTE is often encountered in debilitated patients, such as those with cancer or sepsis—hence the previously used term *marantic endocarditis*. Although the local effect on the valves is usually unimportant, NBTE may achieve clinical significance by producing emboli and resultant infarcts in the brain, heart, or elsewhere.

#### Morphology.

In contrast to IE, the vegetations of NBTE are sterile, nondestructive, and small (1 to 5 mm), and occur singly or multiply along the line of closure of the leaflets or cusps ( Fig. 12-28 ). Histologically, they are composed of bland thrombus without accompanying inflammatory reaction or induced valve damage. Should the patient survive the underlying disease, organization may occur, leaving delicate strands of fibrous tissue.

#### Pathogenesis.

NBTE frequently occurs concomitantly with venous thromboses or pulmonary embolism, suggesting *a common origin in a hypercoagulable state with systemic activation of blood coagulation such as disseminated intravascular coagulation* ( Chapter 4 ). *This may be related to some underlying disease, such as a cancer,* and, in particular, mucinous adenocarcinomas of the pancreas. The striking association with mucinous adenocarcinomas in general may relate to the procoagulant effect of circulating mucin, and thus NBTE can be a part of the Trousseau syndrome ( Chapter 7 ). Lesions of NBTE, however, are also seen occasionally in association with nonmucin-producing malignancy, such as acute promyelocytic leukemia, and in other debilitating diseases or conditions (e.g., hyperestrogenic states, extensive burns, or sepsis) promoting hypercoagulability. Endocardial trauma, as from an indwelling catheter, is also a well-recognized predisposing condition, and one frequently notes right-sided valvular and endocardial thrombotic lesions along the track of a Swan-Ganz pulmonary artery catheter.

### Endocarditis of Systemic Lupus Erythematosus (Libman-Sacks Disease)

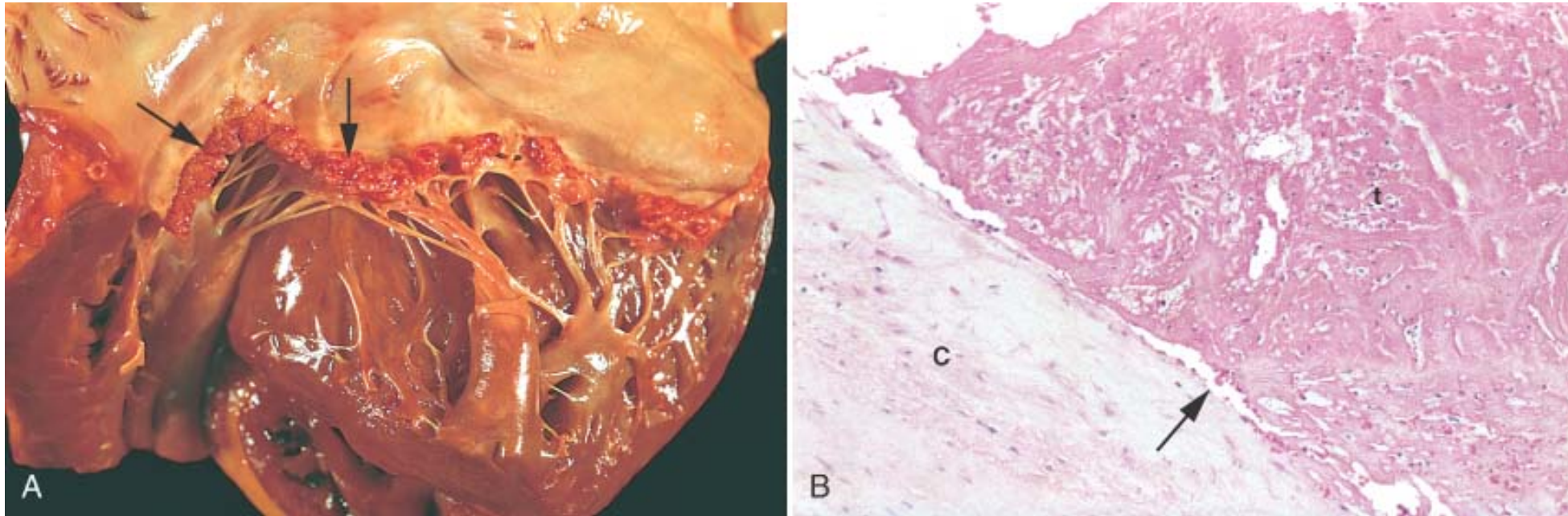
In SLE, mitral and tricuspid valvulitis with small, sterile vegetations, called *Libman-Sacks endocarditis* is occasionally encountered.

#### Morphology.

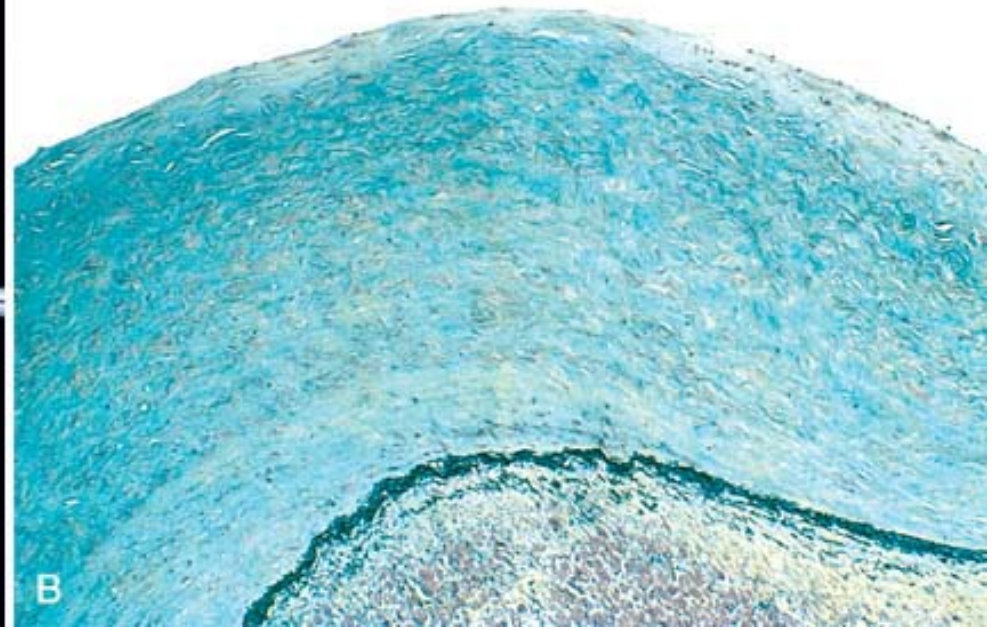
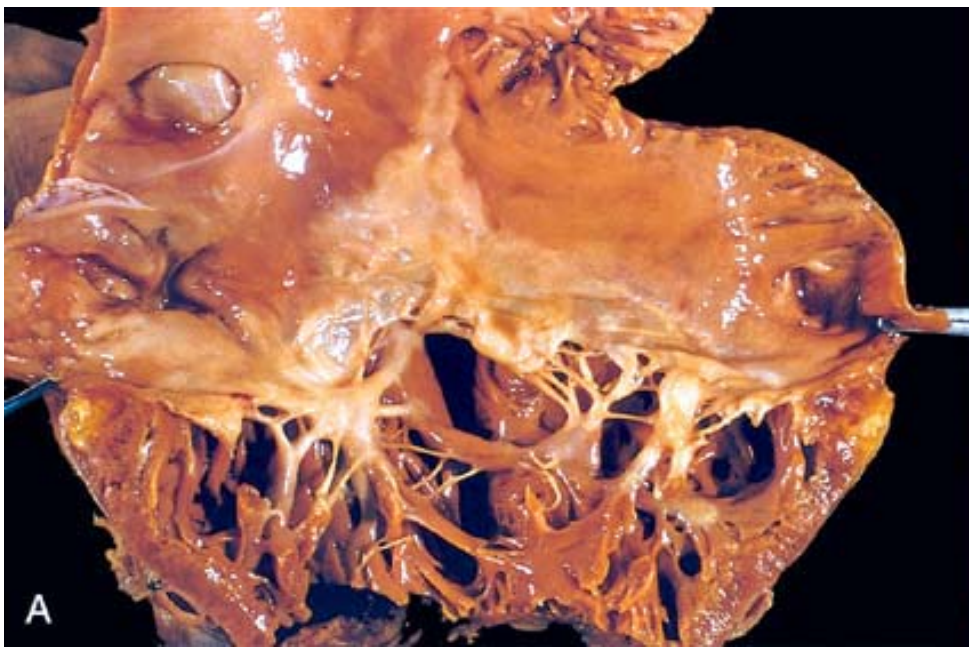
The lesions are small single or multiple, sterile, granular pink vegetations ranging from 1 to 4 mm in diameter. The lesions may be located on the undersurfaces of the atrioventricular valves, on the valvular endocardium, on the cords, or on the mural endocardium of atria or ventricles. Histologically the verrucae consist of a finely granular, fibrinous eosinophilic material that may contain hematoxylin bodies (the tissue equivalent of the lupus erythematosus cell of the blood and bone marrow, see Chapter 6 ). An intense valvulitis may be present, characterized by fibrinoid necrosis of the valve substance that is often contiguous with the vegetation. Leaflet vegetations can be difficult in some cases to distinguish from those of IE or NBTE (see Fig. 12-27 ). Subsequent fibrosis and serious deformity can result that resemble chronic RHD and require surgery.



**Figure 12-28** Nonbacterial thrombotic endocarditis (NBTE). *A*, Nearly complete row of thrombotic vegetations along the line of closure of the mitral valve leaflets (*arrows*). *B*, Photomicrograph of NBTE, showing bland thrombus, with virtually no inflammation in the valve cusp (*c*) or the thrombotic deposit (*t*). The thrombus is only loosely attached to the cusp (*arrow*).

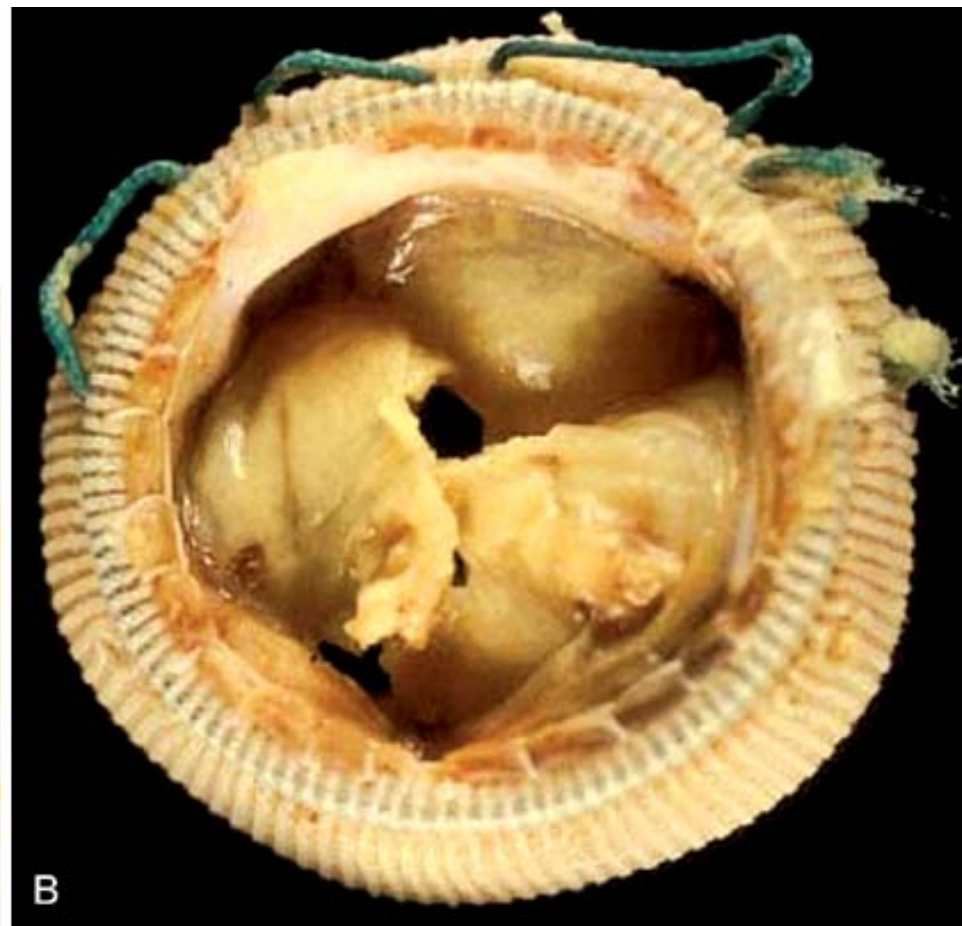
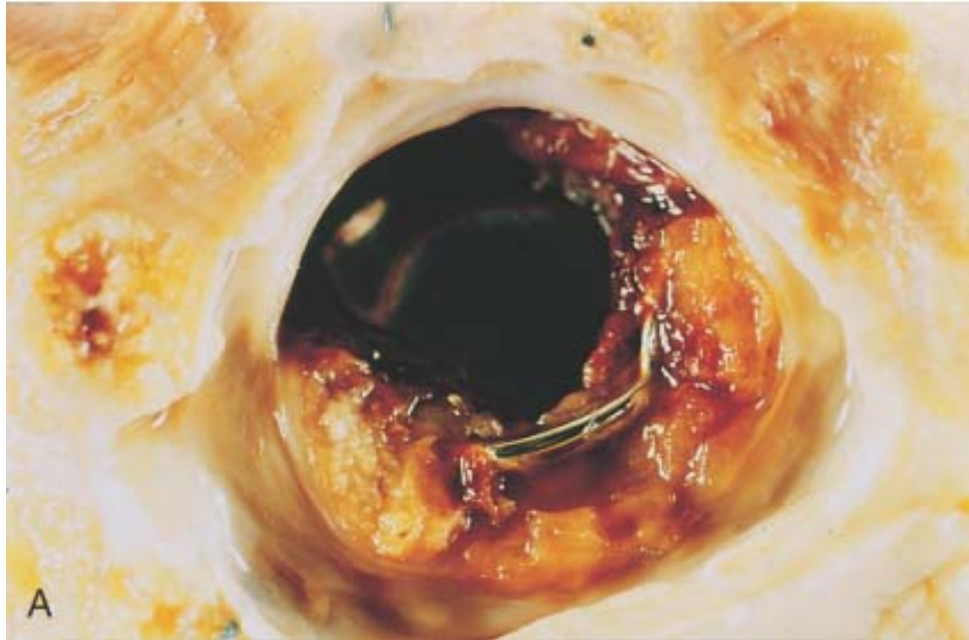


**Figure 12-29** Carcinoid heart disease. *A*, Characteristic endocardial fibrotic lesion involving the right ventricle and tricuspid valve. *B*, Microscopic appearance of carcinoid heart disease with intimal thickening. Movat stain shows underlying myocardial elastic tissue black and acid mucopolysaccharides blue-green.



**Figure 12-30** Complications of artificial heart valves. *A*, Thrombosis of a mechanical prosthetic valve. *B*, Calcification with secondary tearing of a porcine bioprosthesis heart valve, viewed from the inflow aspect.





**TABLE 12-9 -- Causes of Failure of Cardiac Valve Prostheses**

Thrombosis/thromboembolism
Anticoagulant-related hemorrhage
Prosthetic valve endocarditis
Structural deterioration (intrinsic)
••Wear, fracture, poppet failure in ball valves, cuspal tear, calcification
Nonstructural dysfunction
••Granulation tissue, suture, tissue entrapment, paravalvular leak, disproportion, hemolytic anemia, noise

### Cardiomyopathies

The previous sections emphasize that myocardial dysfunction occurs commonly but secondarily in a number of different conditions such as ischemic heart disease, hypertension, and



valvular heart disease. Far less frequently observed is disease whose cause is intrinsic to the myocardium. Myocardial diseases are a diverse group that includes inflammatory disorders (*myocarditis*), immunologic diseases, systemic metabolic disorders, muscular dystrophies, genetic abnormalities in cardiac muscle cells, and an additional group of diseases of unknown etiology.

The term *cardiomyopathy* (literally, heart muscle disease) is used to describe *heart disease resulting from a primary abnormality in the myocardium*.<sup>[95]</sup> Although chronic myocardial dysfunction due to ischemia should be excluded from the cardiomyopathy rubric, the term *ischemic cardiomyopathy* has gained some popularity among clinicians to describe CHF caused by CAD (as discussed in the section "Chronic Ischemic Heart Disease").

In many cases cardiomyopathies are *idiopathic* (i.e., of unknown cause). However, a major advance in our understanding of myocardial diseases, previously considered idiopathic, has been the demonstration that specific genetic abnormalities in cardiac energy metabolism or structural and contractile proteins underlie myocardial dysfunction in many patients.<sup>[96]</sup> <sup>[97]</sup> <sup>[98]</sup> Thus, etiologic distinctions have become somewhat blurred in recent years. Moreover, myocardial disease of diverse and even unknown etiologies may have a similar morphologic appearance. Therefore, our discussion avoids the controversies associated with classification schemes and emphasizes clinicopathologic, etiologic, and mechanistic concepts.

Without additional data, the clinician encountering a patient with myocardial disease is usually unaware of the etiology. Hence the clinical approach is largely determined by one of the following three clinical, functional, and pathologic patterns ( Fig. 12-31 and Table 12-10 ):

- Dilated cardiomyopathy
- Hypertrophic cardiomyopathy
- Restrictive cardiomyopathy

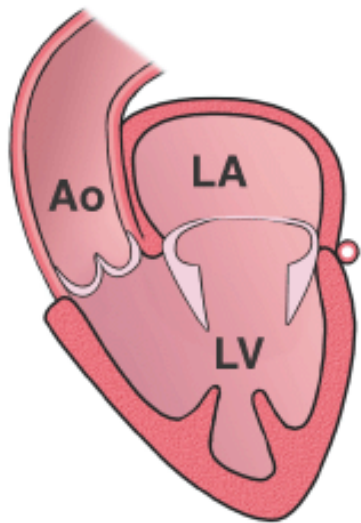
Among these three categories, the dilated form is most common (90% of cases), and the restrictive is least prevalent. Within the hemodynamic patterns of myocardial dysfunction, there is a spectrum of clinical severity, and overlap of clinical features often occurs between groups. Moreover, each of these patterns can be either idiopathic or due to a specific identifiable cause ( Table 12-11 ) or secondary to primary extramyocardial disease.

*Endomyocardial biopsies* are used in the diagnosis and management of patients with myocardial disease and in cardiac transplant recipients. Endomyocardial biopsy involves inserting a device (called a *biopsy*) transvenously into the right side of the heart and snipping a small piece of septal myocardium in its jaws, which is then analyzed by a pathologist.<sup>[99]</sup>

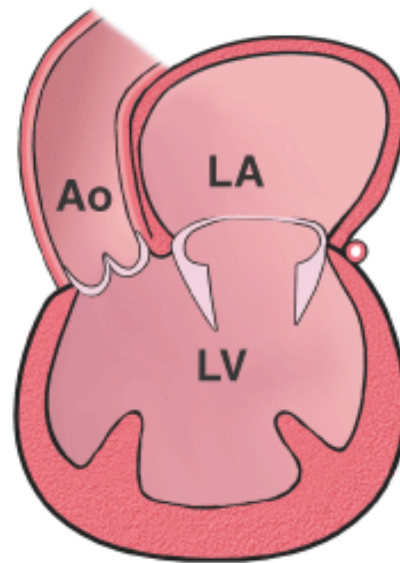
#### DILATED CARDIOMYOPATHY

The term *dilated cardiomyopathy* (DCM) is applied to a form of cardiomyopathy characterized by *progressive cardiac dilation and contractile (systolic) dysfunction*, usually with concomitant hypertrophy. It is sometimes called congestive cardiomyopathy.

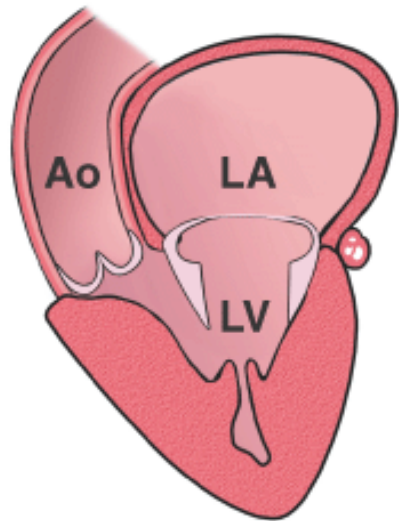
**Figure 12-31** Graphic representation of the three distinctive and predominant clinical-pathologic-functional forms of myocardial disease.



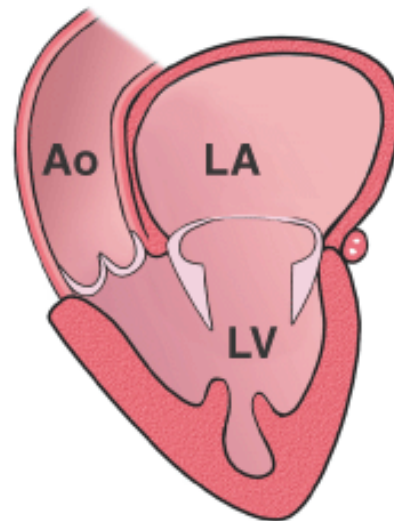
Normal



Dilated  
cardiomyopathy



Hypertrophic  
cardiomyopathy



Restrictive  
cardiomyopathy

**TABLE 12-10 -- Cardiomyopathy and Indirect Myocardial Dysfunction: Functional Patterns and Causes**

Functional Pattern	Left Ventricular Ejection Fraction *	Mechanisms of Heart Failure	Causes	Indirect Myocardial Dysfunction (Not Cardiomyopathy)
--------------------	--------------------------------------	-----------------------------	--------	--

Dilated	<40%	Impairment of contractility (systolic dysfunction)	Idiopathic; alcohol; peripartum; genetic; myocarditis; hemochromatosis; chronic anemia; doxorubicin (Adriamycin); sarcoidosis	Ischemic heart disease; valvular heart disease; hypertensive heart disease; congenital heart disease
Hypertrophic	50–80%	Impairment of compliance (diastolic dysfunction)	Genetic; Friedreich ataxia; storage diseases; infants of diabetic mothers	Hypertensive heart disease; aortic stenosis
Restrictive	45–90%	Impairment of compliance (diastolic dysfunction)	Idiopathic; amyloidosis; radiation-induced fibrosis	Pericardial constriction

\*Normal, approximately 50–65%.

**TABLE 12-11** -- Conditions Associated with Heart Muscle Diseases

<i><b>Cardiac Infections</b></i>
Viruses
Chlamydia
Rickettsia
Bacteria
Fungi
Protozoa
<i><b>Toxins</b></i>
Alcohol
Cobalt
Catecholamines
Carbon monoxide
Lithium
Hydrocarbons
Arsenic
Cyclophosphamide
Doxorubicin (Adriamycin) and daunorubicin
<i><b>Metabolic</b></i>
Hyperthyroidism
Hypothyroidism



Hyperkalemia
Hypokalemia
Nutritional deficiency (protein, thiamine, other avitaminoses)
Hemochromatosis
<b><i>Neuromuscular Disease</i></b>
Friedreich ataxia
Muscular dystrophy
Congenital atrophies
<b><i>Storage Disorders and Other Depositions</i></b>
Hunter-Hurler syndrome
Glycogen storage disease
Fabry disease
Amyloidosis
<b><i>Infiltrative</i></b>
Leukemia
Carcinomatosis
Sarcoidosis
Radiation-induced fibrosis
<b><i>Immunologic</i></b>
Myocarditis (several forms)
Post-transplant rejection

Although it is recognized that approximately 25% to 35% of individuals with DCM have a familial (genetic) form, DCM can result from a number of acquired myocardial insults that ultimately yield a similar clinicopathologic pattern. These include toxicities (including chronic alcoholism, a history of which can be elicited in 10% to 20% of patients), myocarditis (an inflammatory disorder that precedes the development of cardiomyopathy in at least some cases, as documented by endomyocardial biopsy), and pregnancy-associated nutritional deficiency or immunologic reaction. In some patients, the cause of DCM is unknown; such cases are appropriately designated as *idiopathic dilated cardiomyopathy*.

#### **Morphology.**

In DCM, the heart is usually heavy, often weighing two to three times normal, and large and flabby, with dilation of all chambers ( Fig. 12-32 ). Nevertheless, because of the wall thinning that accompanies dilation, the ventricular thickness may be less than, equal to, or greater than normal. Mural thrombi are common and may be a source of thromboemboli. There are no primary valvular alterations, and mitral or tricuspid regurgitation, when present, results from left ventricular chamber dilation (functional regurgitation). The coronary arteries are usually free of significant narrowing, but any coronary artery obstructions present are insufficient to explain the degree of cardiac dysfunction.

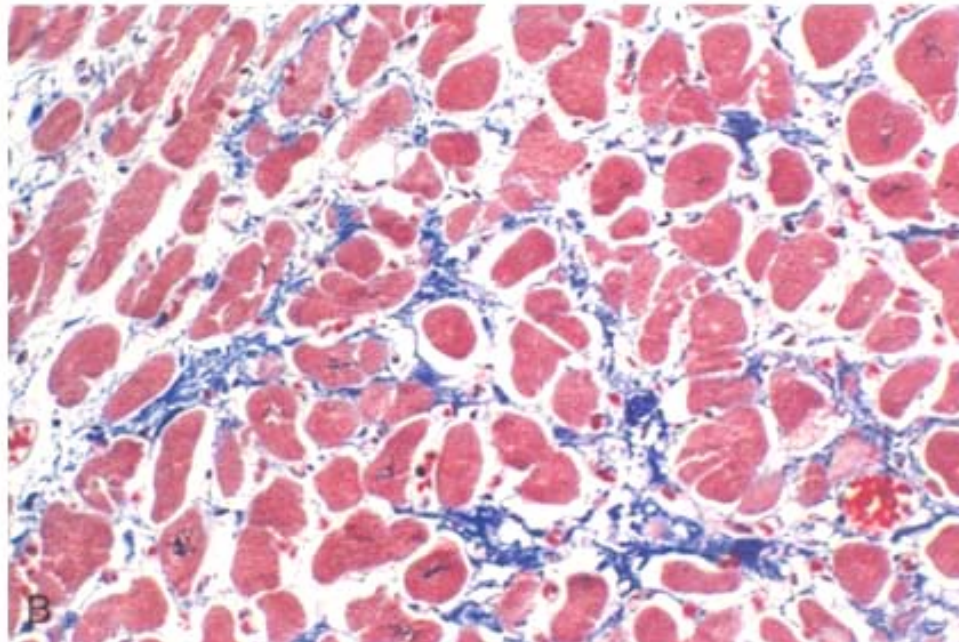
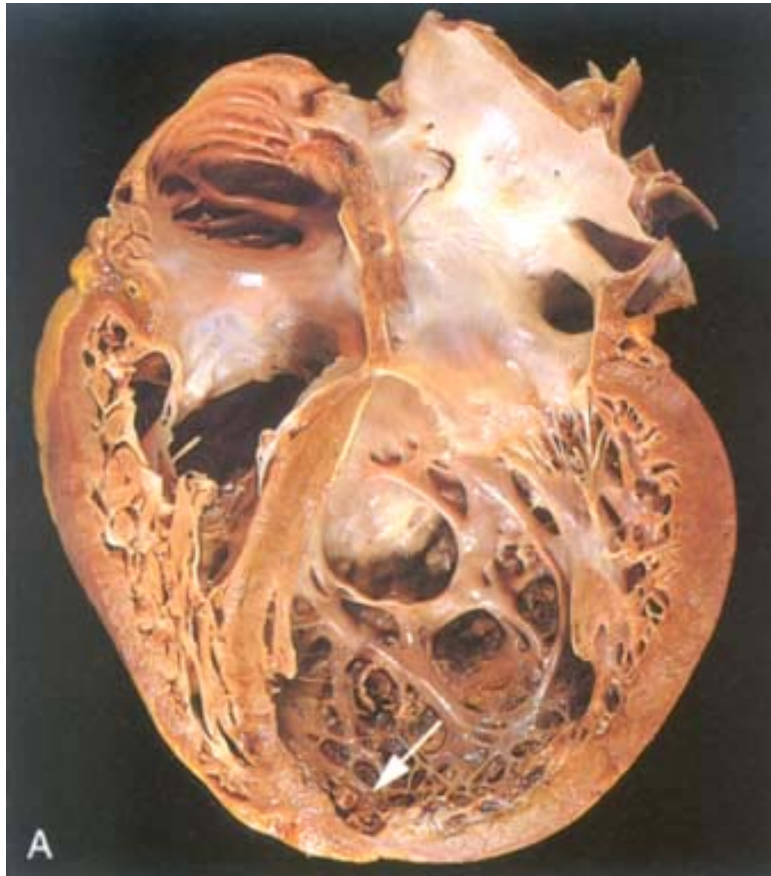**The histologic abnormalities in idiopathic DCM also are nonspecific and usually do not reflect a specific etiologic agent.** Moreover, their severity does not necessarily reflect the degree of dysfunction or the patient's prognosis. Most muscle cells are hypertrophied with enlarged nuclei, but many are attenuated, stretched, and irregular. Interstitial and endocardial fibrosis of variable degree is present, and small subendocardial scars may replace individual cells or groups of cells, probably reflecting healing of previous secondary myocyte ischemic necrosis caused by hypertrophy-induced imbalance between perfusion, supply and demand.

#### Pathogenesis.

Historically, the etiologic associations in dilated cardiomyopathy have included myocardial inflammatory

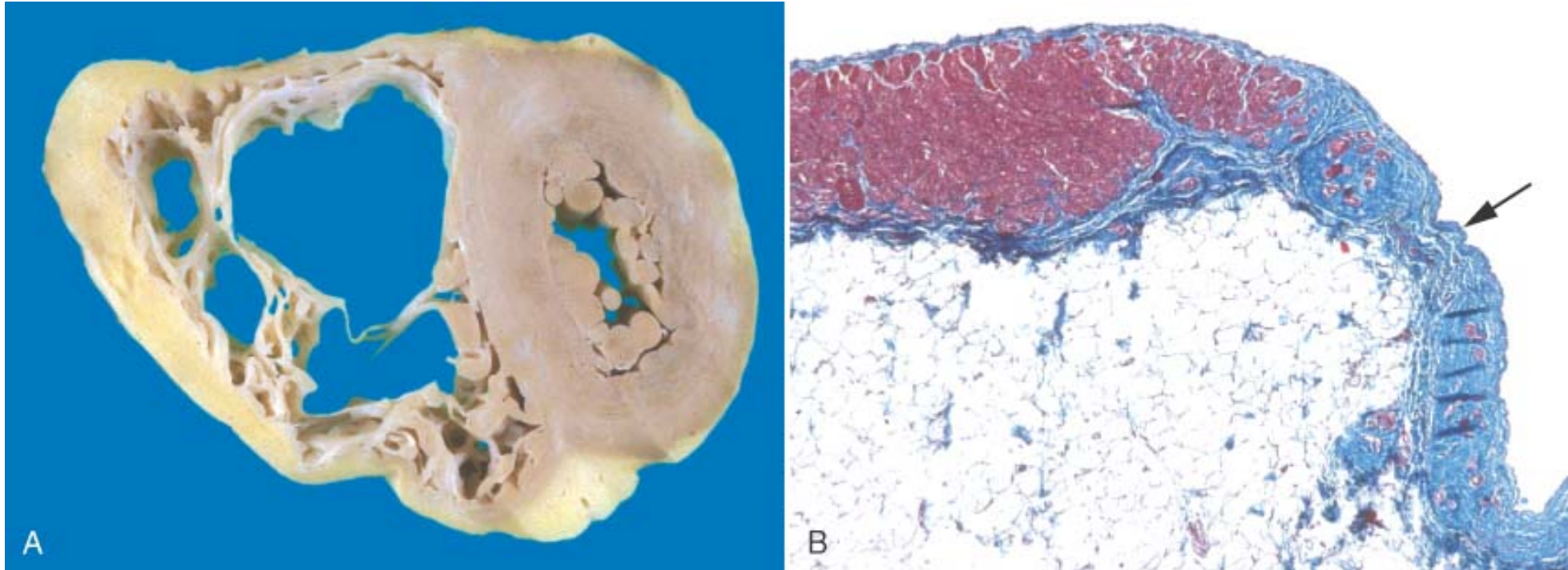
603

**Figure 12-32** Dilated cardiomyopathy. *A*, Gross photograph. Four-chamber dilatation and hypertrophy are evident. There is granular mural thrombus at the apex of the left ventricle (on the right in this apical four-chamber view). The coronary arteries were unobstructed. *B*, Histology demonstrating variable myocyte hypertrophy and interstitial fibrosis (collagen is highlighted as blue in this Masson trichrome stain).

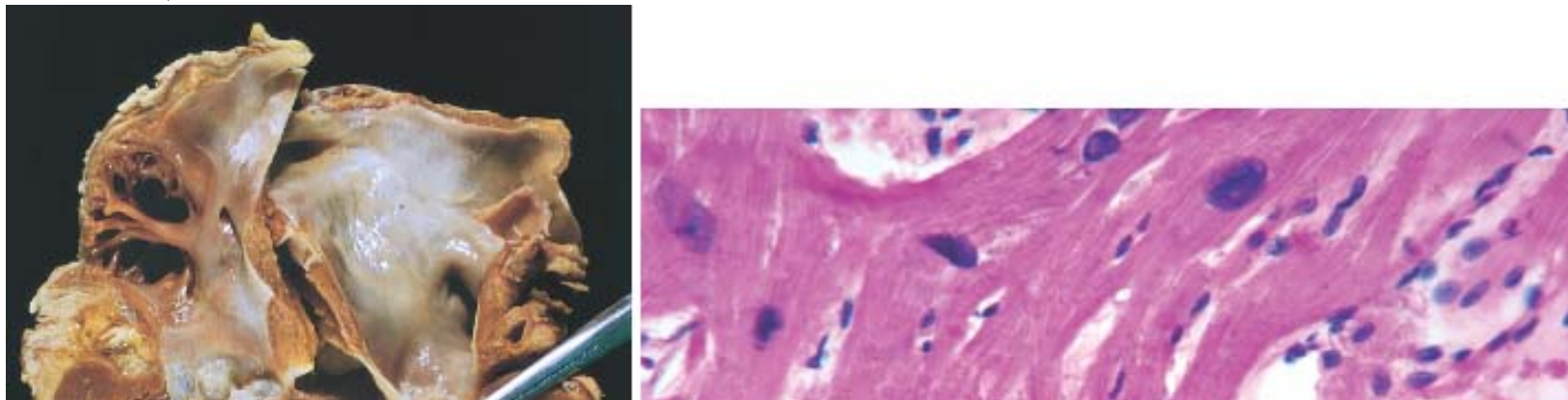




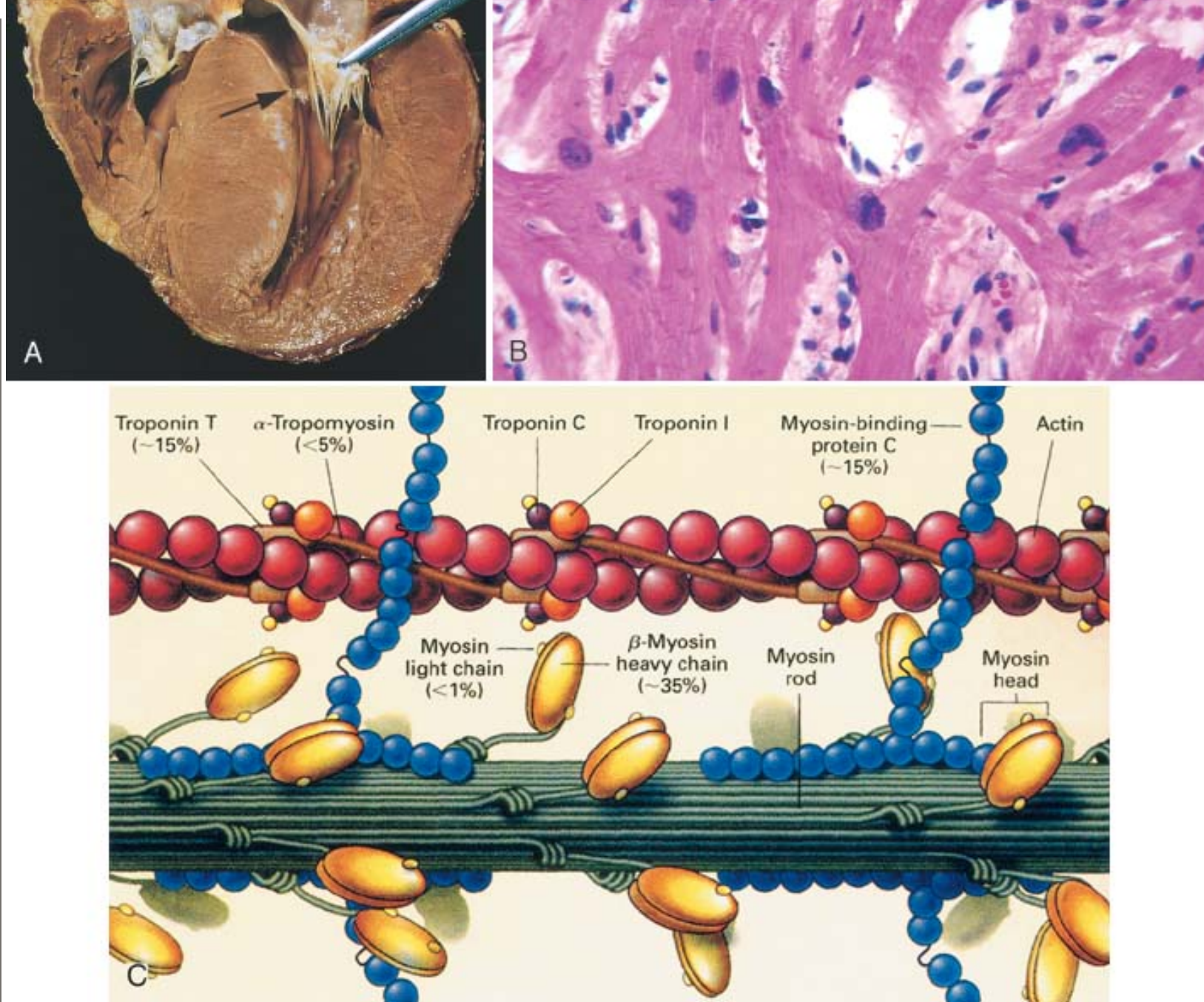
**Figure 12-33** Arrhythmogenic right ventricular cardiomyopathy. *A*, Gross photograph, showing dilation of the right ventricle and near transmural replacement of the right ventricular free-wall myocardium by fat and fibrosis. The left ventricle has a virtually normal configuration. *B*, Histologic section of the right ventricular free wall, demonstrating replacement of myocardium (red) by fibrosis (blue, arrow) and fat (collagen is blue in this Masson trichrome stain).



**Figure 12-34** Hypertrophic cardiomyopathy with asymmetric septal hypertrophy. *A*, The septal muscle bulges into the left ventricular outflow tract, and the left atrium is enlarged. The anterior mitral leaflet has been moved away from the septum to reveal a fibrous endocardial plaque (arrow) (see text). *B*, Histologic appearance demonstrating disarray, extreme hypertrophy, and characteristic branching of myocytes as well as the interstitial fibrosis characteristic of hypertrophic cardiomyopathy (collagen is blue in this Masson trichrome stain). *C*, Schematic structure of the sarcomere of cardiac muscle, highlighting proteins in which mutations cause defective contraction, hypertrophy, and myocyte disarray in hypertrophic cardiomyopathy. The frequency of a particular gene mutation is indicated as a percentage of all cases of HCM; most common are mutations in  $\beta$ -myosin heavy chain. Normal contraction of the sarcomere involves myosin-actin interaction initiated by calcium binding to troponin C, I, and T and  $\alpha$ -tropomyosin. Actin stimulates ATPase activity in the myosin head and produces force along the actin filaments. Myocyte-binding protein C modulates contraction. (*A*, reproduced by permission from Schoen FJ: *Interventional and Surgical Cardiovascular Pathology: Clinical Correlations and Basic Principles*. Philadelphia, W.B. Saunders, 1989. *C*, from Spirito P, et al: *The management of hypertrophic cardiomyopathy*. *N Engl J Med* 336:775, 1997.)







**Figure 12-35** Pathways of dilated and hypertrophic cardiomyopathy, emphasizing several important concepts. Some forms of dilated cardiomyopathy (others are caused by myocarditis, alcohol, and other toxic injury or the peripartum state) and virtually all forms of hypertrophic cardiomyopathy are genetic in origin. The genetic causes of dilated cardiomyopathy involve mutations in any of a wide variety of proteins, predominantly of the cytoskeleton, but also the sarcomere, mitochondria, and nuclear envelope. In contrast, the mutated genes that cause hypertrophic cardiomyopathy encode proteins of the sarcomere. Although these two forms of cardiomyopathy differ greatly in subcellular basis and morphologic phenotypes, they share a common pathway of clinical complications.

## DILATED CARDIOMYOPATHY

### Non-genetic causes

- myocarditis
- peri partum
- toxic (e.g., alcohol)
- idiopathic

### 30-40% genetic causes

#### Mutations in sarcomere

- actin
- $\beta$ -myosin heavy chain
- $\alpha$ -tropomyosin
- troponin T

#### Mutations in cytoskeleton

- $\delta$ -sarcoglycan
- $\beta$ -sarcoglycan
- dystrophin
- desmin

#### Mutations in nuclear envelope

- lamin A/C

#### Mutations in mitochondria

- medium long chain Acyl-6A
- dehydrogenase
- carnitine transporter translocase

Defect in either force generation or transmission

#### Dilated cardiomyopathy phenotype

- hypertrophy
- dilation
- fibrosis, interstitial
- intracardiac thrombi

### Clinical

- heart failure
- sudden death
- atrial fibrillation
- stroke

## HYPERTROPHIC CARDIOMYOPATHY

### 100% genetic causes

#### Mutations in sarcomere

- actin
- $\beta$ -myosin heavy chain
- $\alpha$ -tropomyosin
- troponin T
- myosin light chain
- troponin I
- MYBPC
- titin

Defect in force generation

#### Hypertrophic cardiomyopathy phenotype

- hypertrophy, marked
- asymmetrical septal hypertrophy
- myofiber disarray
- fibrosis, interstitial and replacement
- LV outflow tract plaque
- thickened septal vessels

TABLE 12-12 -- Major Causes of Myocarditis

<b><i>Infections</i></b>
Viruses (e.g., coxsackievirus, ECHO, influenza, HIV, cytomegalovirus)
Chlamydiae (e.g., <i>C. psittaci</i> )
Rickettsiae (e.g., <i>R. typhi</i> , typhus fever)
Bacteria (e.g., <i>Corynebacterium diphtheriae</i> , <i>Neisseria meningococcus</i> , <i>Borrelia</i> (Lyme disease))
Fungi (e.g., <i>Candida</i> )
Protozoa (e.g., <i>Trypanosoma</i> Chagas disease, toxoplasmosis)
Helminths (e.g., trichinosis)
<b><i>Immune-Mediated Reactions</i></b>
Postviral
Poststreptococcal (rheumatic fever)
Systemic lupus erythematosus
Drug hypersensitivity (e.g., methyldopa, sulfonamides)
Transplant rejection
<b><i>Unknown</i></b>
Sarcoidosis
Giant cell myocarditis
HIV, human immunodeficiency virus.

inflammation and myocyte damage without a clear etiologic agent and (2) myocarditis caused directly by HIV or by an opportunistic pathogen.

*There are also noninfectious causes of myocarditis.* Myocarditis can be related to allergic reactions (*hypersensitivity myocarditis*), often to a particular drug such as antibiotics, diuretics, and antihypertensive agents. Myocarditis can also be associated with systemic diseases of immune origin, such as RF, SLE, and polymyositis. Cardiac sarcoidosis and rejection of a transplanted heart are also considered forms of myocarditis.

Against this background we can turn to the anatomic changes seen in the major forms of myocarditis.

#### **Morphology.**

During the active phase of myocarditis, the heart may appear normal or dilated; some hypertrophy may be present. The lesions may be diffuse or patchy. The ventricular myocardium is typically flabby and often mottled by either pale foci or minute hemorrhagic lesions. Mural thrombi may be present in any chamber.

During active disease, myocarditis is most frequently characterized by an interstitial inflammatory infiltrate and focal necrosis of myocytes adjacent to the inflammatory cells ( Fig. 12-36 ).

[<sup>74</sup>] Myocarditis in which the infiltrate is mononuclear and predominantly lymphocytic is most common (see Fig. 12-36A ). Although endomyocardial biopsies are diagnostic in some cases,



they can be spuriously negative because inflammatory involvement may be focal or patchy. If the patient survives the acute phase of myocarditis, the inflammatory lesions either resolve, leaving no residual changes, or heal by progressive fibrosis, as mentioned earlier.

**Hypersensitivity myocarditis** has interstitial infiltrates, principally perivascular, composed of lymphocytes, macrophages, and a high proportion of eosinophils (see Fig. 12-36*B* ).

A morphologically distinctive form of myocarditis of uncertain cause, called **giant cell myocarditis**, is characterized by a widespread inflammatory cellular infiltrate containing multinucleate giant cells interspersed with lymphocytes, eosinophils, plasma cells, and macrophages and having at least focal but frequently extensive necrosis ( Fig. 12-36*C* ). The giant cells are of either macrophage or myocyte origin. This variant carries a poor prognosis.<sup>[117]</sup>

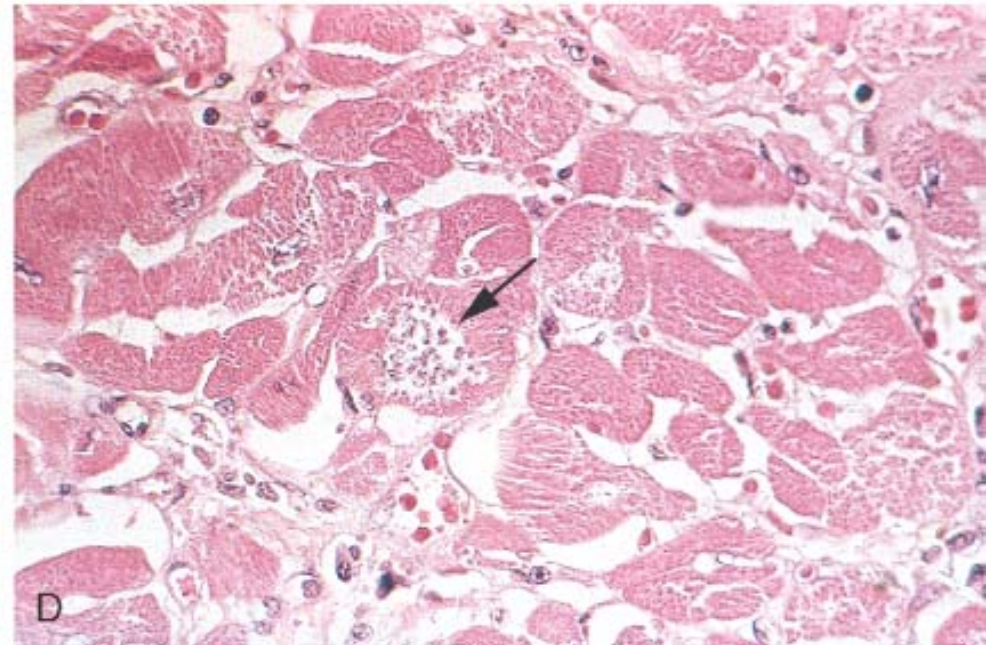
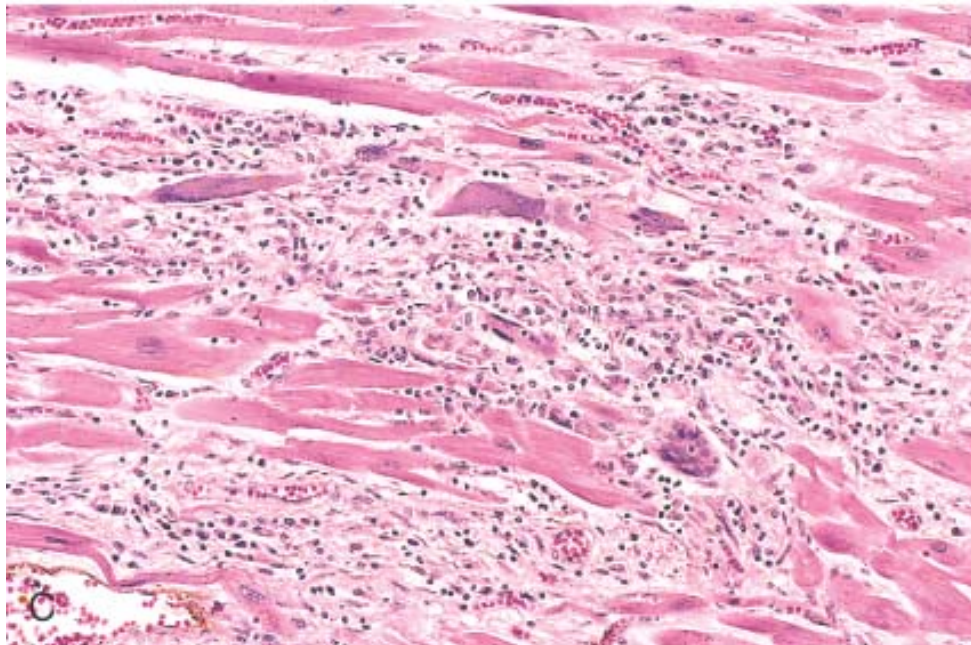
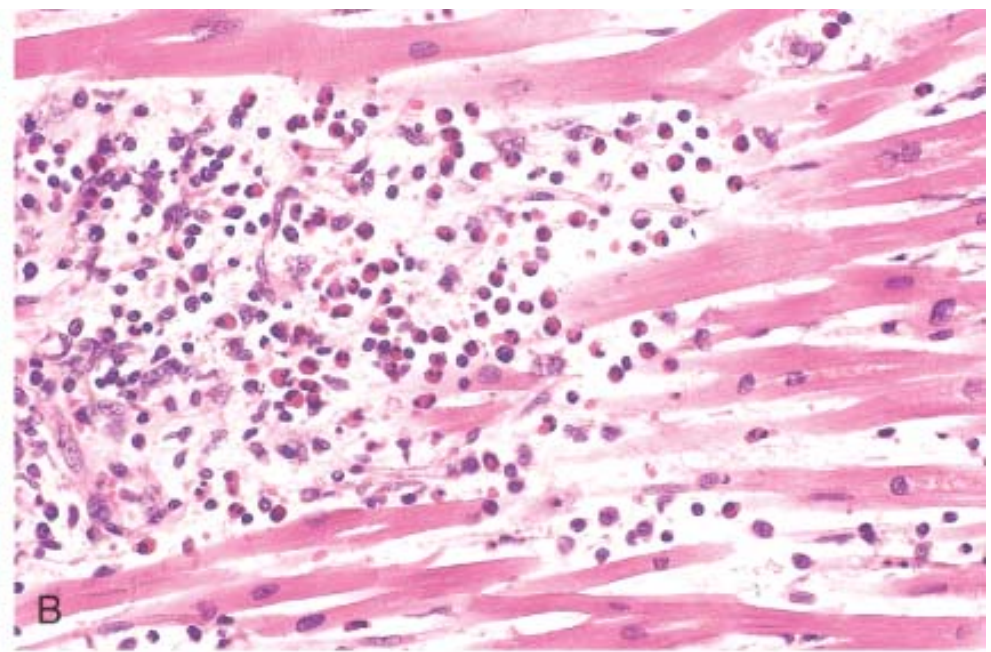
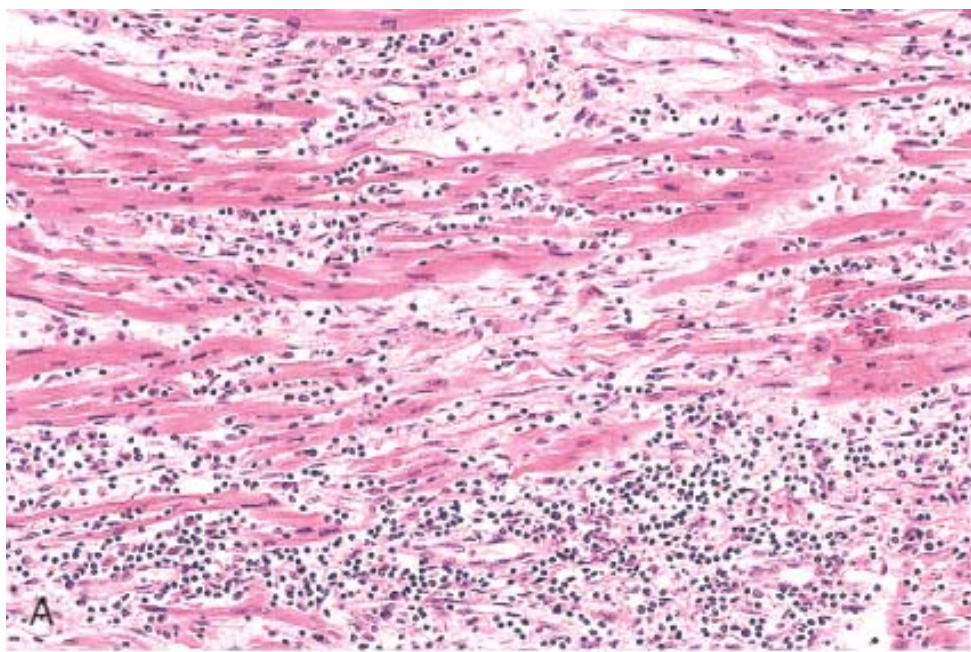
The myocarditis of **Chagas disease** is rendered distinctive by parasitization of scattered myofibers by trypanosomes accompanied by an inflammatory infiltrate of neutrophils, lymphocytes, macrophages, and occasional eosinophils ( Fig. 12-36*D* ).

#### **Clinical Features.**

The clinical spectrum of myocarditis is broad; at one end the disease is entirely asymptomatic, and such patients recover completely without sequelae. At the other extreme is the precipitous onset of heart failure or arrhythmias, occasionally with sudden death. A systolic murmur may appear, indicating functional mitral regurgitation related to dilation of the left ventricle. Between these extremes are the many levels of involvement associated with such symptoms as fatigue, dyspnea, palpitations, precordial discomfort, and fever. The clinical features of myocarditis can

**Figure 12-36** Myocarditis. *A*, Lymphocytic myocarditis, with mononuclear inflammatory cell infiltrate and associated myocyte injury. *B*, Hypersensitivity myocarditis, characterized by interstitial inflammatory infiltrate composed largely of eosinophils and mononuclear inflammatory cells, predominantly localized to perivascular and large interstitial spaces. This form of myocarditis is associated with drug hypersensitivity. *C*, Giant cell myocarditis, with mononuclear inflammatory infiltrate containing lymphocytes and macrophages, extensive loss of muscle, and multinucleated giant cells. *D*, The myocarditis of Chagas disease. A myofiber is distended with trypanosomes (*arrow*). There is a surrounding inflammatory reaction and individual myofiber necrosis.





**TABLE 12-13 -- Causes of Pericarditis**

***Infectious Agents***

Viruses



Pyogenic bacteria
Tuberculosis
Fungi
Other parasites
<b><i>Presumably Immunologically Mediated</i></b>
Rheumatic fever
Systemic lupus erythematosus
Scleroderma
Postcardiotomy
Postmyocardial infarction (Dressler) syndrome
Drug hypersensitivity reaction
<b><i>Miscellaneous</i></b>
Myocardial infarction
Uremia
Following cardiac surgery
Neoplasia
Trauma
Radiation

in the tissues contiguous to the pericardium, for example, a bacterial pleuritis, may cause sufficient irritation of the parietal pericardial serosa to cause a sterile serous effusion that may progress to serofibrinous pericarditis and ultimately to a frank suppurative reaction. In some instances, a well-defined viral infection elsewhere—upper respiratory tract infection, pneumonia, parotitis—antedates the pericarditis and serves as the primary focus of infection. Infrequently, usually in young adults, a viral pericarditis occurs as an apparent primary involvement that may accompany myocarditis (*myopericarditis*).

#### **Morphology.**

Whatever the cause, there is an inflammatory reaction in the epicardial and pericardial surfaces with scant numbers of polymorphonuclear leukocytes, lymphocytes, and macrophages. Usually the volume of fluid is not large (50 to 200 mL) and accumulates slowly. Dilation and increased permeability of the vessels due to inflammation produces a fluid of high specific gravity and rich protein content. A mild inflammatory infiltrate in the epipericardial fat consisting predominantly of lymphocytes is frequently termed chronic pericarditis. Organization into fibrous adhesions rarely occurs.

#### **Fibrinous and Serofibrinous Pericarditis.**

These two anatomic forms are *the most frequent type of pericarditis* and are composed of serous fluid mixed with a fibrinous exudate. Common causes include acute MI (recall Fig. 12-19D ), the postinfarction (Dressler) syndrome (likely an autoimmune condition appearing several weeks after a MI), uremia, chest radiation, RF, SLE, and trauma. A fibrinous reaction also



follows routine cardiac surgery.

#### **Morphology.**

In fibrinous pericarditis, the surface is dry, with a fine granular roughening. In serofibrinous pericarditis, an increased inflammatory process induces more and thicker fluid, which is yellow and cloudy owing to leukocytes and erythrocytes (which may be sufficient to give a visibly bloody appearance), and often fibrin. As with all inflammatory exudates, **fibrin may be digested with resolution of the exudate or it may become organized** (see Chapter 3 ).

From the clinical standpoint, *the development of a loud pericardial friction rub is the most striking characteristic of fibrinous pericarditis*, and pain, systemic febrile reactions, and signs suggestive of cardiac failure may be present. However, a collection of serous fluid may obliterate the rub by separating the two layers of the pericardium.

#### **Purulent or Suppurative Pericarditis.**

This almost invariably denotes the invasion of the pericardial space by infective organisms, which may reach the pericardial cavity by several routes: (1) direct extension from neighboring inflammation, such as an empyema of the pleural cavity, lobar pneumonia, mediastinal infections, or extension of a ring abscess through the myocardium or aortic root in infective endocarditis; (2) seeding from the blood; (3) lymphatic extension; or (4) direct introduction during cardiotomy. Immunosuppression predisposes to infection by all of these pathways.

#### **Morphology.**

The exudate ranges from a thin to a creamy pus of up to 400 to 500 mL in volume. The serosal surfaces are reddened, granular, and coated with the exudate ( Fig. 12-37 ). Microscopically there is an acute inflammatory reaction. Sometimes the inflammatory process extends into surrounding structures to induce a so-called **mediastinopericarditis**. Organization is the usual outcome; resolution is infrequent. Because of the great intensity of the inflammatory response, the organization frequently produces **constrictive pericarditis**, a serious consequence (see later).

The clinical findings in the active phase are essentially the same as those present in fibrinous pericarditis, but signs of systemic infection are usually marked: for example, spiking temperatures, chills, and fever.

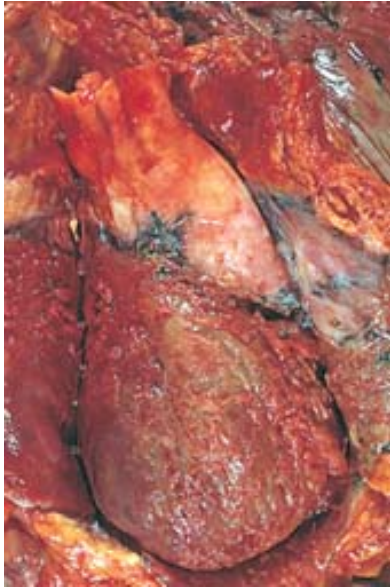#### **Hemorrhagic Pericarditis.**

An exudate composed of blood mixed with a fibrinous or suppurative effusion is most commonly caused by malignant neoplastic involvement of the pericardial space; in such cases, cytologic examination of fluid removed through a pericardial tap may yield neoplastic cells. Hemorrhagic pericarditis may also be found in bacterial infections, in patients with an underlying bleeding diathesis, and in tuberculosis. Hemorrhagic pericarditis often follows cardiac surgery and sometimes is responsible for significant blood loss or even tamponade, requiring a "second-look" operation. The clinical significance is similar to that of the spectrum of fibrinous or suppurative pericarditis.

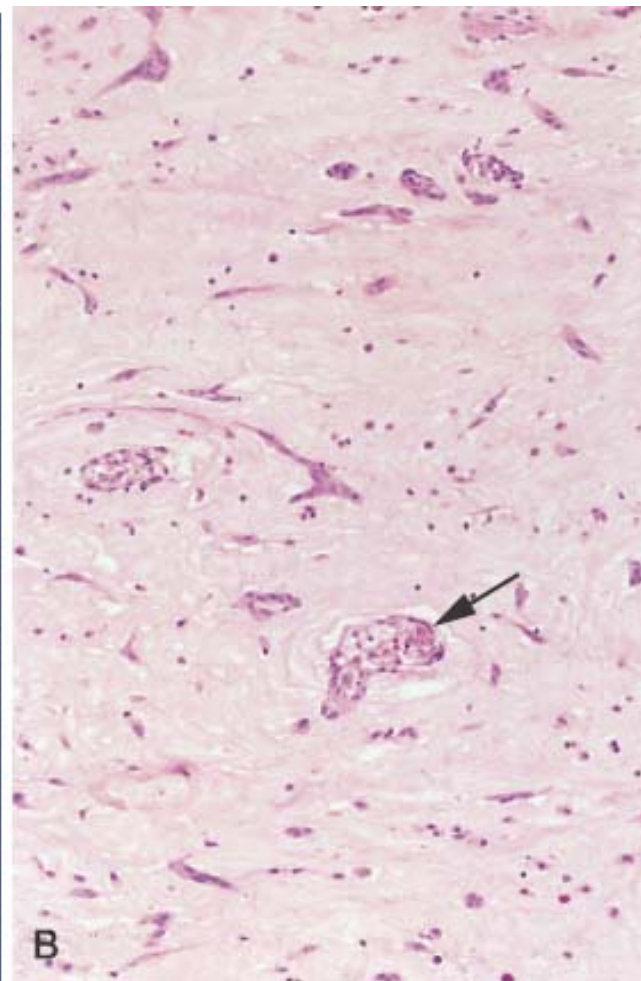
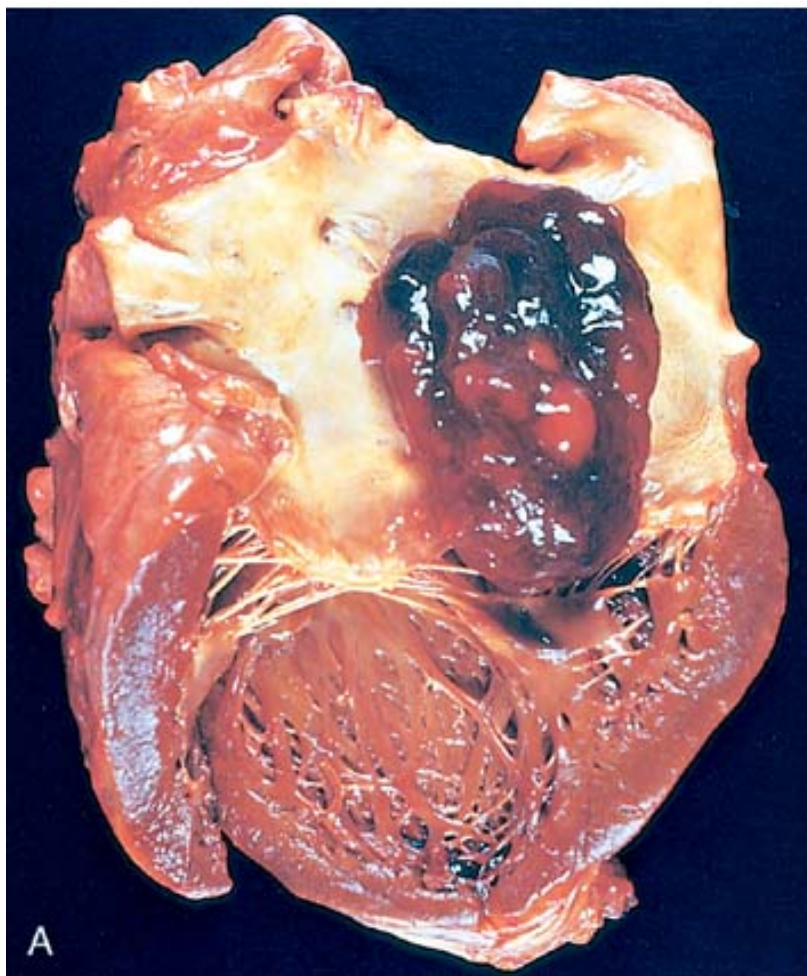
#### **Caseous Pericarditis.**

Caseation within the pericardial sac is, until proved otherwise, tuberculous in origin; infrequently, fungal infections evoke a similar reaction. Pericardial involvement

**Figure 12-37** Acute suppurative pericarditis as an extension from a pneumonia. Extensive purulent exudate is evident in this in situ photograph.



**Figure 12-38** Left atrial myxoma. *A*, Gross photograph showing large pedunculated lesion arising from the region of the fossa ovalis and extending into the mitral valve orifice. *B*, Microscopic appearance, with abundant amorphous extracellular matrix in which are scattered collections of myxoma cells in various groupings, including abnormal vascular formations (*arrow*).



**TABLE 12-14 -- Cardiovascular Effects of Noncardiac Neoplasms**

<b><i>Direct Consequences of Tumor</i></b>
Pericardial and myocardial metastases
Large vessel obstruction
Pulmonary tumor emboli
<b><i>Indirect Consequences of Tumor (Complications of Circulating Mediators)</i></b>
Nonbacterial thrombotic endocarditis (NBTE)
Carcinoid heart disease
Pheochromocytoma-associated heart disease
Myeloma-associated amyloidosis



## Effects of Tumor Therapy

Chemotherapy

Radiation therapy

*Modified from Schoen, FJ, et al: Cardiac effects of non-cardiac neoplasms. Cardiol Clin 2:657, 1984.*

615

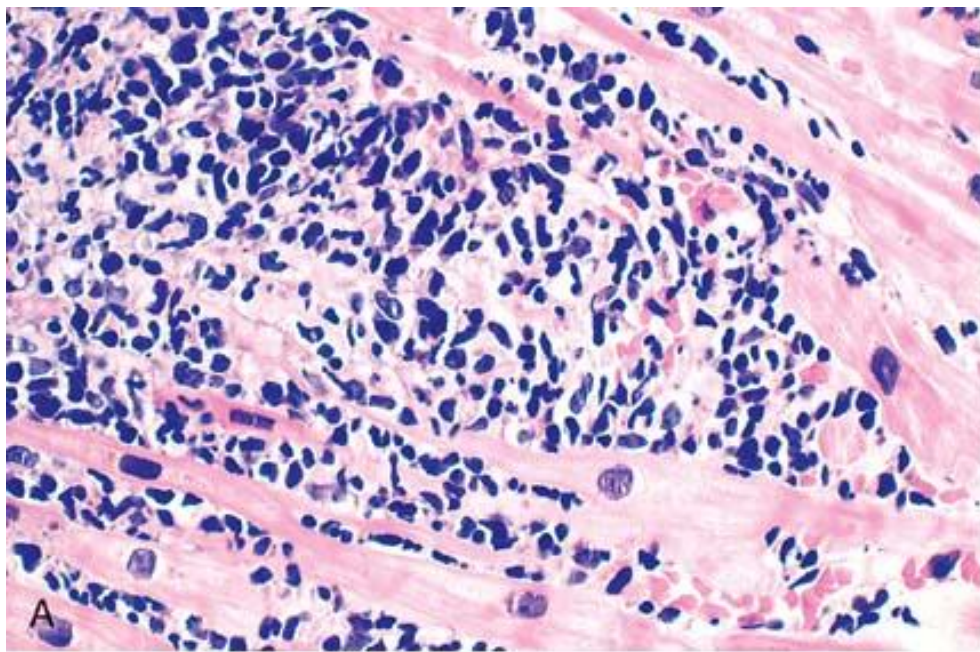
compliance. Bronchogenic carcinoma or malignant lymphoma may infiltrate the mediastinum extensively, causing encasement, compression, or invasion of the superior vena cava with resultant obstruction to blood coming from the head and upper extremities (*superior vena cava syndrome*). Renal cell carcinoma, because of its high propensity to invade the renal vein, can grow in the lumen of the renal vein into and along the inferior vena cava and can, occasionally, extend into the right atrium, blocking venous return to the heart.

Noncardiac tumors cause indirect cardiac effects, sometimes via circulating tumor-derived substances (e.g., NBTE [see earlier], carcinoid heart disease, pheochromocytoma-associated myocardial damage, multiple myeloma-derived immunoglobulin-causing amyloidosis). Complications of chemotherapy were discussed earlier in this chapter. Radiation used to treat breast, lung, or mediastinal neoplasms can cause pericarditis, pericardial effusion, myocardial fibrosis, and chronic pericardial disorders. Other cardiac effects of radiotherapy include accelerated coronary artery disease and mural and valvular endocardial fibrosis.

### Cardiac Transplantation

Transplantation of cardiac allografts is now frequently performed (approximately 3000 per year worldwide) for severe, intractable heart failure of diverse causes, the two most common of which are DCM and IHD. Three major factors contribute to the widespread success of cardiac transplantation since the first successful human to human transplant in 1967: (1) careful selection of candidates, (2) improved

**Figure 12-39** Complications of heart transplantation. *A*, Cardiac allograft rejection typified by lymphocytic infiltrate, with associated damage to cardiac myocytes. *B*, Graft coronary arteriosclerosis, demonstrating severe diffuse concentric intimal thickening producing critical stenosis. The internal elastic lamina (*arrow*) and media are intact (Movat pentachrome stain, elastin black). (*B*, reproduced by permission from Salomon RN, et al: Human coronary transplantation-associated arteriosclerosis. Evidence for chronic immune reaction to activated graft endothelial cells. *Am J Pathol* 138:791, 1991.)



## References

1. Sagnella GA: Practical implications of current natriuretic peptide research. *J Renin Angioten Aldost Syst* 1:304, 2000.
2. Maisel AS, et al: Rapid measurement of B-type natriuretic peptide in the emergency diagnosis of heart failure. *N Engl J Med* 347:161, 2002.
3. Lerner DL, et al: The role of altered intercellular coupling in arrhythmias induced by acute myocardial ischemia. *Cardiovasc Res* 50:263, 2001.
4. Schoen FJ: Aortic valve structure-function correlations: role of elastic fibers no longer a stretch of the imagination. *J Heart Valve Dis* 6:1, 1997.
5. Duncan AK, et al: Cardiovascular disease in elderly patients. *Mayo Clin Proc* 71:184, 1996.
6. Braunwald E, Zipes DP, Libby P (eds): *Heart Disease. A Textbook of Cardiovascular Medicine*, 6th ed. Philadelphia, WB Saunders Co., 2001.
7. Silver, MD, Gotlieb AI, Schoen FJ (eds): *Cardiovascular Pathology*, 3rd ed. New York, Churchill Livingstone, 2001.
8. Chien KR: Genomic circuits and the integrative biology of cardiac diseases. *Nature* 407:227, 2000.
9. Hoshijima M, Chien KR: Mixed signals in heart failure: cancer rules. *J Clin Invest* 109:849, 2002.
10. Cohn JN, et al: Report of the National Heart, Lung, and Blood Institute Special Emphasis Panel on Heart Research. *Circulation* 95:766, 1997.
11. Lorell BH, Carabello BA: Left ventricular hypertrophy: pathogenesis, detection, and prognosis. *Circulation* 102:470, 2000.
12. Zile MR, Brutsaert DL: New concepts in diastolic dysfunction and diastolic heart failure. Parts I and II. *Circulation* 105:1387, 1503, 2002.
13. Francis GS: Pathophysiology of chronic heart failure. *Am J Med* 110:37S, 2001.

14. Rose EA, et al: Long-term mechanical left ventricular assistance for end-stage heart failure. *N Engl J Med* 345:1435, 2001.
15. Pasumarthi KBS, Field LJ: Cardiomyocyte cell cycle regulation. *Circ Res* 90:1044, 2002.
16. Johnatty SE, et al: Identification of genes regulated during mechanical load-induced cardiac hypertrophy. *J Mol Cell Cardiol* 32:805, 2000.
17. Razeghi P, et al: Metabolic gene expression in fetal and failing human heart. *Circulation* 104:2923, 2001.
18. MacLellan WR: Advances in the molecular mechanisms of heart failure. *Curr Opin Cardiol* 15:128, 2000.
19. Frey N, et al: Decoding calcium signals involved in cardiac growth and function. *Nature Med* 6:1221, 2000.
20. Kang PM, Izumo S: Apoptosis and heart failure: a critical review of the literature. *Circ Res* 86:1107, 2000.
21. Levy D, et al: Prognostic implications of echocardiographically determined left ventricular mass in the Framingham Heart Study. *N Engl J Med* 322:1561, 1990.
22. Hart RG, Halperin JL: Atrial fibrillation and stroke: concepts and controversies. *Stroke* 32:803, 2001.
23. Webb CL, et al: Collaborative care for adults with congenital heart disease. *Circulation* 105:2318, 2002.
24. Schoen FJ, Edwards WD: Pathology of cardiovascular interventions, including endovascular therapies, revascularization, vascular replacement, cardiac assist/replacement, arrhythmia control and repaired congenital heart disease. In Silver MD, Gotlieb AI, Schoen FJ (eds): *Cardiovascular Pathology*. Philadelphia, Churchill Livingstone, 2001, p 678–721.
25. Fleming A, Copp AJ: Embryonic folate metabolism and mouse neural tube defects. *Science* 280:2107, 1998.
26. Olson EN, Schneider MD: Sizing up the heart: development REDUX in disease. *Genes Dev* 17: 1937, 2003.
27. Yelon D: Cardiac patterning and morphogenesis in zebrafish. *Dev Dyn* 222:552, 2001.
28. Chen J-N, Fishman MC: Genetics of heart development. *Trends Genetics* 16:383, 2000.
29. Srivastava D: Genetic assembly of the heart: implications for congenital heart disease. *Ann Rev Physiol* 63:452, 2001.
30. Vaughn CJ, Basson CT: Molecular determinants of atrial and ventricular septal defects and patent ductus arteriosus. *Am J Med Genetics (Sem Med Genet)* 97:304, 2001.
31. Cripps RM, Olson EN: Control of cardiac development by an evolutionarily conserved transcriptional network. *Dev Biol* 246:14, 2002.
32. Milewicz DM, Seidman CE: Genetics of cardiovascular disease. *Circulation* 102:IV–103, 2000.
33. Manson JE, et al: The primary prevention of myocardial infarction. *N Engl J Med* 326:1406, 1992.
34. Rich Edwards JW, et al: The primary prevention of coronary heart disease in women. *N Engl J Med* 332:1758, 1995.
35. Braunwald E: Cardiovascular medicine at the turn of the millennium: triumphs, concerns, and opportunities. *N Engl J Med* 337:1360, 1997.
36. Hunink MG, et al: The recent decline in mortality from coronary heart disease, 1980–1990. The effect of secular trends in risk factors and treatment. *J Am Med Assoc* 277:535, 1997.
37. Lauer MS: Aspirin for primary prevention of coronary events. *New Engl J Med* 346:1468, 2002.
38. Libby P: Current concepts of the pathogenesis of the acute coronary syndromes. *Circulation* 104:365, 2001.



39. Fuster V, et al: 27th Bethesda Conference: Matching the intensity of risk factor management with the hazard for coronary disease events. Task Force 1. Pathogenesis of coronary disease: the biologic role of risk factors. J Am Coll Cardiol 27:964, 1996.
40. Yeghiazarians Y, et al: Unstable angina pectoris. New Engl J Med 342:101, 2000.
41. Willich SN: Circadian variation and triggering of cardiovascular events. Vasc Med 4:41, 1999.
42. Muller JE: Circadian variation in cardiovascular events. Am J Hyperten 12:35S, 1999.
43. Ambrose JA, Martinez EE: A new paradigm for plaque stabilization. Circulation 105:2000, 2002.
44. Leor J, et al: Sudden cardiac death triggered by an earthquake. N Engl J Med 334:413, 1996.
45. Falk E, et al: Coronary plaque disruption. Circulation 92:657, 1995.
46. Ross R: Atherosclerosis: an inflammatory disease. N Engl J Med 340:115, 1999.
47. Libby P, Ridker PM, Maseri A: Inflammation and atherosclerosis. Circulation 105:1135, 2002.
48. Plutzky J: Inflammatory pathways in atherosclerosis and acute coronary syndromes. Am J Cardiol 88:10K, 2001.
49. Blake GJ, Ridker P: C-reactive protein: a surrogate risk marker or mediator of atherothrombosis? Am J Physiol Reg Integr Comp Physiol 285:R1252, 2003.
50. Ridker PM, Morrow DA: C-reactive protein, inflammation and coronary risk. Cardiol Clin 21:315, 2003.
51. Ridker PM, Rifai N, Rose L, Buring JE, Cook NR: Comparison of C-reactive protein and low-density lipoprotein cholesterol levels in the prediction of first cardiovascular events. N Engl J Med 348:1059, 2002.
52. Torres JL, Ridker PM: Clinical use of high sensitivity C-reactive protein for the prediction of adverse cardiovascular events. Curr Opin Cardiol 18:471, 2003.
- 52A. Tall AR: C-reactive protein reassessed. N Engl J Med 350:1450, 2004.
53. Manson JE, Martin KA: Postmenopausal hormone-replacement therapy. N Engl J Med 345:34, 2001.
54. DeWood MA, et al: Prevalence of total coronary occlusion during the early hours of transmural myocardial infarction. N Engl J Med 303:897, 1980.
55. Jennings RB, et al: Development of cell injury in sustained acute ischemia. Circulation 82:II-2, 1990.
56. Huikuri HV, et al: Sudden death due to cardiac arrhythmias. N Engl J Med 345:1473, 2001.
57. Vargas SO, et al: Pathologic detection of early myocardial infarction: a critical review of the evolution and usefulness of modern techniques. Mod Pathol 12:635, 1999.
58. Huber K, Maurer G: Thrombolytic therapy in acute myocardial infarction. Semin Thromb Hemost 22:15, 1996.
59. Bittl JA: Advances in coronary angioplasty. N Engl J Med 335:1290, 1996.
60. Hansen PR: Role of neutrophils in myocardial ischemia and reperfusion. Circulation 91:1872, 1995.
61. Verma S, et al: Fundamentals of reperfusion injury for the clinical cardiologist. Circulation 105:2332, 2002.

62. Yellon DM, Baxter GF: Protecting the ischemic and reperfused myocardium in acute myocardial infarction: distant dream or near reality? *Heart* 83:381, 2000.

63. Kloner RA, Jennings RB: Consequences of brief ischemia: stunning, preconditioning, and their clinical implications. Parts I and II. *Circulation* 104:2981, 3158, 2001.

64. Wijns W, et al: Hibernating myocardium. *N Engl J Med* 339:173, 1998.

65. Wagner GS, et al: Moving toward a new definition of acute myocardial infarction for the 21st century: status of the ESC/ACC consensus conference. European Society of Cardiology and American College of Cardiology. *J Electrocardiol* 33:57, 2000.

66. Birnbaum, Y, et al: Ventricular septal rupture after acute myocardial infarction. *N Engl J Med* 347:1426, 2002.

67. St. John Sutton MG, Sharpe N: Left ventricular remodeling after myocardial infarction. Pathophysiology and therapy. *Circulation* 101:2981, 2000.

68. Cohn JN, et al: Cardiac remodeling—Concepts and clinical implications: a consensus paper from an international forum on cardiac remodeling. *J Am Coll Cardiol* 35:569, 2000.

69. Anversa P, Nadal-Ginard B: Myocyte renewal and ventricular remodelling. *Nature* 415:240, 2002.

70. Liberthson RR: Sudden death from cardiac causes in children and young adults. *N Engl J Med* 334:1039, 1996.

71. Futterman LG, Myerburg R: Sudden death in athletes: an update. *Sports Med* 26:335, 1998.

72. Bigger JT: Expanding indications for implantable cardiac defibrillators. *N Engl J Med* 346:931, 2002.

73. Roberts R, Brugada R: Genetic aspects of arrhythmias. *Am J Med Gen* 97:310, 2000.

74. Varagic J, Susic D, Frohlich E: Heart, aging, and hypertension. *Curr Opin Cardiol* 16:336, 2001.

75. Kannel WB: Blood pressure as a cardiovascular risk factor. Prevention and treatment. *JAMA* 275:1571, 1996.

76. Bonow RO, et al: ACC/AHA Guidelines for the Management of Patients with Valvular Heart Disease. Executive Summary. A report of the American College of Cardiology/American Heart Association Task Force on Practice Guidelines (Committee on Management of Patients with Valvular Disease). *J Heart Valve Dis* 7:672, 1998.

77. Carabello BA: Aortic stenosis. *N Engl J Med* 346:677, 2002.

78. Hoffman JIE, Kaplan S: The incidence of congenital heart disease. *J Am Coll Cardiol* 39:1890, 2002.

79. Sabet HY, et al: Congenitally bicuspid aortic valves: a surgical pathology study of 542 cases (1991 through 1996) and a literature review of 2,715 additional cases. *Mayo Clin Proc* 74:14, 1999.

80. Rabkin E, et al: Activated interstitial myofibroblasts express catabolic enzymes and mediate matrix remodeling in myxomatous heart valves. *Circulation* 104:2525, 2001.

81. Zuppiroli A, et al: Natural history of mitral valve prolapse. *Am J Cardiol* 75:1028, 1995.

82. Stollerman GH: Rheumatic fever in the 21st century. *Clin Infect Dis* 33:806, 2001.
83. Veasy LG, Hill HR: Immunologic and clinical correlations in rheumatic fever and rheumatic heart disease. *Pediatr Infect Dis J* 16:400, 1997.
84. Mylonakis E, Calderwood SB: Infective endocarditis in adults. *N Engl J Med* 345:1318, 2001.
85. Dajani AS, et al: Prevention of bacterial endocarditis. Recommendations by the American Heart Association. *Circulation* 96:358, 1997.
86. Durack DT, et al: New criteria for diagnosis of infective endocarditis: utilization of specific echocardiographic findings. *Am J Med* 96:200, 1994.
87. Hojnik M, et al: Heart valve involvement (Libman-Sacks endocarditis) in the antiphospholipid syndrome. *Circulation* 93:1579, 1996.
88. Levine JS, et al: The antiphospholipid syndrome. *N Engl J Med* 346:752, 2002.
89. Simula DV, et al: Surgical pathology of carcinoid heart disease: a study of 139 valves from 75 patients spanning 20 years. *Mayo Clin Proc* 77:139, 2002.
90. Robiolio PA, et al: Carcinoid heart disease: correlation of high serotonin levels with valvular abnormalities detected by cardiac catheterization and echocardiography. *Circulation* 92:790, 1995.
91. Connolly HM, et al: Fenfluramine-phentermine associated valvular heart disease: a new observation. *N Engl J Med* 337:581, 1997.
92. Vongpatanasin W, et al: Prosthetic heart valves. *N Engl J Med* 355:407, 1996.
93. Schoen FJ: Pathology of heart valve substitution with mechanical and tissue prostheses. In Silver MD, Gotlieb AI, Schoen FJ (eds), *Cardiovascular Pathology*, 3rd ed. Philadelphia, Churchill Livingstone, 2001, p 629–677.
94. Hammermeister K, et al: Outcomes 15 years after valve replacement with a mechanical versus a bioprosthetic valve: final report of the Veterans Affairs randomized trial. *J Am Coll Cardiol* 36:1152, 2000.
95. Richardson P, et al: Report of the 1995 World Health Organization/International Society and Federation of Cardiology Task Force on the definition and classification of cardiomyopathies. *Circulation* 93:841, 1996.
96. Roberts R, Schwartz K: Myocardial disease. *Circulation* 102:IV–34, 2000.
97. Franz WM, et al: Cardiomyopathies: from genetics to the prospect of treatment. *Lancet* 358:1627, 2001.
98. Towbin JA, Bowles NE: The failing heart. *Nature* 415:227, 2002.
99. Veinot JP: Diagnostic endomyocardial biopsy pathology—general biopsy considerations, and its use for myocarditis and cardiomyopathy: a review. *Can J Cardiol* 18:55, 2002.
100. Badorff C, et al: Enteroviral protease 2A cleaves dystrophin: evidence of cytoskeletal disruption in an acquired cardiomyopathy. *Nature Med* 5:320, 1999.
101. Vatta M, et al: Molecular remodelling of dystrophin in patients with end-stage cardiomyopathies and reversal on assistance-device therapy. *Lancet* 359:936, 2002.
102. Gemayel C, et al: Arrhythmogenic right ventricular cardiomyopathy. *J Am Coll Cardiol* 38:1773, 2001.
103. Thienne G, Basso C: Arrhythmogenic right ventricular cardiomyopathy: an update. *Cardiovasc Pathol* 10:109, 2001.
104. McKoy G, et al: Identification of a detection of phakaglobin in arrhythmic right ventricular cardiomyopathy with palm plantar keratoderma and wooly hair (Naxos disease). *Lancet*



355:2119, 2000.

105. Seidman JG, Seidman C: The genetic basis for cardiomyopathy: from mutation identification to mechanistic paradigms. *Cell* 104:557, 2001.
106. Roberts R, Sigwart U: New concepts in hypertrophic cardiomyopathies. Parts I and II. *Circulation* 104:2113, 2249, 2001.
107. Maron BJ: Hypertrophic cardiomyopathy. *JAMA* 287:1308, 2002.
108. Marian AJ: Pathogenesis of diverse clinical and pathological phenotypes in hypertrophic cardiomyopathy. *Lancet* 355:58, 2000.
109. Kushwaha SS, et al: Restrictive cardiomyopathy. *N Engl J Med* 335:267, 1997.
110. Feldman AM, McNamara D: Myocarditis. *N Engl J Med* 343:1388, 2000.
111. Winters GL, McManus BM: Myocarditis. In Silver MD, Gotlieb AI, Schoen FJ, (eds): *Cardiovascular Pathology*, 3rd ed. Philadelphia, Churchill Livingstone, 2001, p 256–284.
112. Huber SA: Autoimmunity in myocarditis: relevance of animal models. *Clin Immunol Immunopathol* 83:93, 1997.
113. Morris SA, et al: Pathophysiological insights into the cardiomyopathy of Chagas' disease. *Circulation* 82:1900, 1990.
114. Pinto DS: Cardiac manifestations of Lyme disease. *Med Clin North Am* 86:285, 2002.
115. Lewis W: Cardiomyopathy in AIDS: A pathophysiological perspective. *Prog Cardiovasc Dis* 43:151, 2000.
116. Rerkpattanapipat P, et al: Cardiac manifestations of acquired immunodeficiency syndrome. *Arch Intern Med* 160:602, 2000.
117. Cooper LT Jr, et al: Idiopathic giant cell myocarditis in natural history and treatment. Multicenter Giant Cell Myocarditis Study Group Investigators. *N Engl J Med* 336:1860, 1997.
118. Shan K, et al: Anthracycline-induced cardiotoxicity. *Ann Intern Med* 125:47, 1996.
119. Kloner RA, et al: The effects of acute and chronic cocaine use on the heart. *Circulation* 85:407, 1992.
120. Samuels MA: Neurally induced cardiac damage. Definition of the problem. *Neurol Clin* 11:273, 1993.
121. Falk RH, et al: The systemic amyloidoses. *N Engl J Med* 337:898, 1997.
122. McCarthy RE III, Kasper EK: A review of the amyloidoses that infiltrate the heart. *Clin Cardiol* 21:547, 1998.
123. Kyle RA, et al: The premortem recognition of systemic senile amyloidosis with cardiac involvement. *Am J Med* 171:395, 1996.
124. Jacobson DR, et al: Variant-sequence transthyretin (isoleucine 122) in late-onset cardiac amyloidosis in black Americans. *N Engl J Med* 336:466, 1997.
125. Tazelaar HD, et al: Pathology of surgically excised primary cardiac tumors. *Mayo Clin Proc* 67:957, 1992.

127. Vaughan CJ, et al: Tumors of the heart: molecular genetic advances. *Curr Opin Cardiol* 16:195, 2001.
128. Smith M, Sperling D: Novel 23-base-pair duplication mutation in TSCI exon 15 in an infant presenting with cardiac rhabdomyomas. *Am J Med Gen* 84:346, 1999.
129. Winters GL, Schoen FJ: Pathology of cardiac transplantation. In Silver MD, Gotlieb AI, Schoen FJ (eds): *Cardiovascular Pathology*. 3rd ed. Philadelphia, Churchill Livingstone, 2001, p 725–762.
130. Libby P, Pober JS: Chronic rejection. *Immunity* 14:387, 2001.

---

619

## Chapter 13 - Red Blood Cell and Bleeding Disorders

---

**Jon C. Aster MD, PhD**

---

---

620

---

The organs and tissues involved in hematopoiesis have been traditionally divided into *myeloid tissue*, which includes the bone marrow and the cells derived from it (e.g., erythrocytes, platelets, granulocytes, and monocytes), and *lymphoid tissue*, consisting of thymus, lymph nodes, and spleen. This subdivision is artificial with respect to both the normal physiology of hematopoietic cells and the diseases affecting them. For example, although bone marrow is not where most mature lymphoid cells are found, it is the source of lymphoid stem cells. Similarly, myeloid leukemias, neoplastic disorders of myeloid stem cells, originate in the bone marrow but secondarily involve the spleen and (to a lesser degree) lymph nodes. Some red cell disorders (hemolytic anemias) result from the formation of autoantibodies, signifying a primary disorder of lymphocytes. Thus, it is not possible to draw neat lines between diseases involving the myeloid and lymphoid tissues. Recognizing this difficulty, we somewhat arbitrarily divide diseases of the hematopoietic tissues into two chapters. In the first, we consider diseases of red cells and those affecting hemostasis. In the second, we discuss white cell diseases and disorders affecting primarily the spleen and thymus.

### Normal

A complete discussion of normal hematopoiesis is beyond our scope, but certain features are helpful to an understanding of the diseases of blood.

### Normal Development of Blood Cells

Blood cells first appear during the third week of fetal embryonic development in the yolk sac, but these cells are generated from a primitive stem cell population restricted to the production of myeloid cells. The origin of definitive hematopoietic stem cells that give rise to lymphoid and myeloid cells is still unsettled. Most studies suggest they arise in the mesoderm of the intraembryonic aorta/gonad/mesonephros (AGM) region,<sup>[1]</sup> but evidence also exists for an origin within a small subset of yolk sac-derived cells. By the third month of embryogenesis, stem cells derived from the AGM and/or yolk sac migrate to the liver, which is the chief site of blood cell formation until shortly before birth. Beginning in the fourth month of development, stem cells migrate to the bone marrow to commence hematopoiesis at this site. By birth, marrow throughout the skeleton is hematopoietically active and virtually the sole source of blood cells. In fullterm infants, hepatic hematopoiesis dwindles to a trickle, persisting only in widely scattered small foci that become inactive soon after birth. Up to the age of puberty, marrow throughout the skeleton remains red and hematopoietically active. By age 18 only the vertebrae, ribs, sternum, skull, pelvis, and proximal epiphyseal regions of the humerus and femur retain red marrow, the remaining marrow becoming yellow, fatty, and inactive. Thus, in adults, only about half of the marrow space is active in hematopoiesis.

Several features of this normal sequence should be emphasized. By birth, the bone marrow is virtually the sole source of all forms of blood cells, including lymphocyte precursors. In the premature infant, foci of hematopoiesis are frequently evident in the liver and, rarely, in the spleen, lymph nodes, or thymus. Significant postembryonic extramedullary hematopoiesis is abnormal in the full-term infant. With an increased demand for blood cells in the adult, the fatty marrow can transform to red, active marrow. For example, in the face of red cell deficiency (anemia), the marrow can increase red cell production (erythropoiesis) as much as eight-fold. If the marrow stem cells and microenvironment are normal and the necessary nutrients are available (e.g., adequate amounts of iron, protein, requisite vitamins), premature loss of red cells (as occurs in hemolytic disorders) produces anemia only when marrow compensatory mechanisms are outstripped. Under these circumstances, extramedullary hematopoiesis can reappear within the spleen, liver, and even lymph nodes.

#### ORIGIN AND DIFFERENTIATION OF HEMATOPOIETIC CELLS

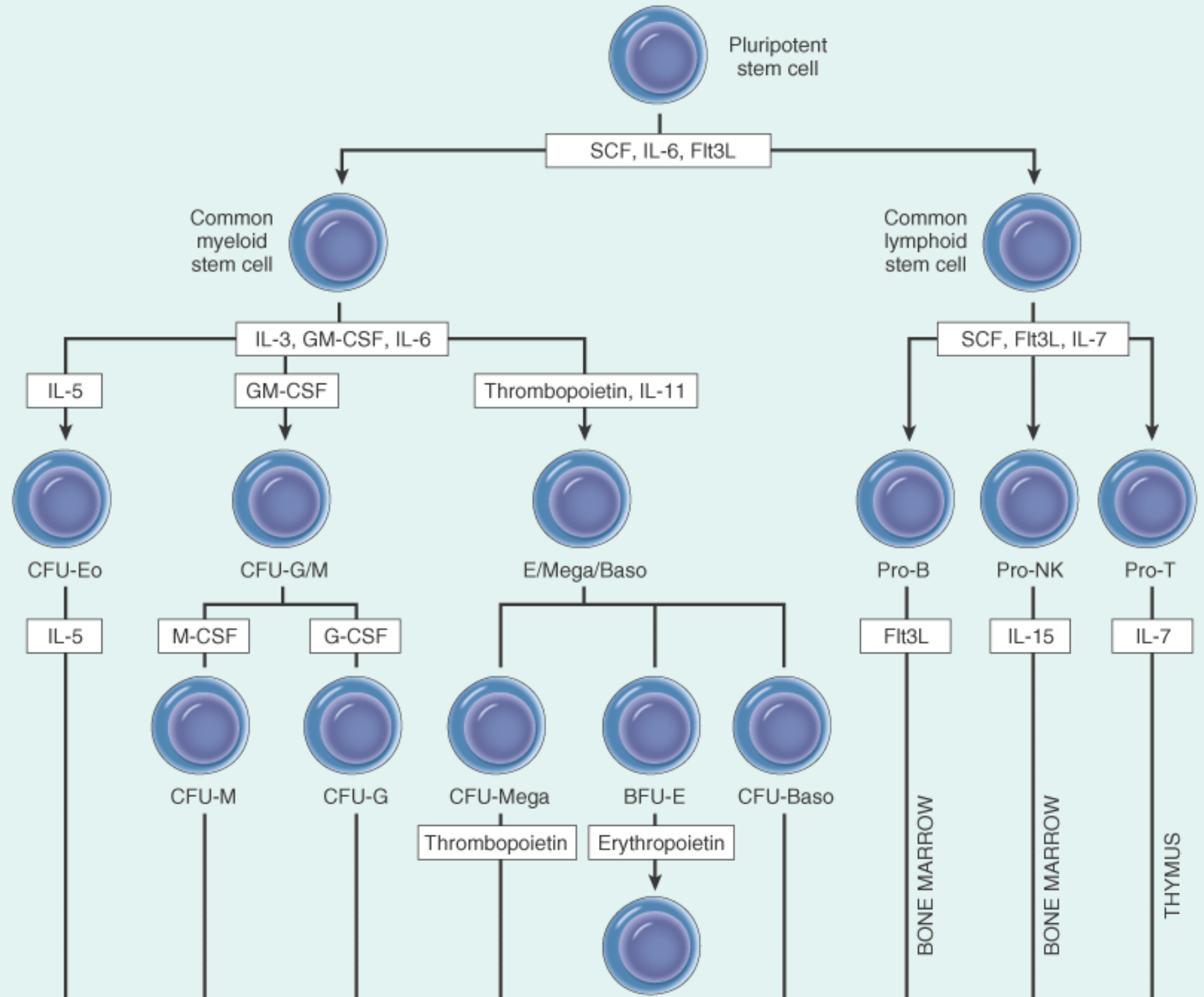
The formed elements of blood—red cells, granulocytes, monocytes, platelets, and lymphocytes—have a common origin from pluripotent hematopoietic stem cells sitting at the apex of a complex hierarchy of progenitors ( Fig. 13-1 ). Most of the work supporting this scheme comes from studies conducted in mice, but it is believed hematopoiesis in man proceeds in a highly analogous fashion. The pluripotent stem cell gives rise to two types of multipotent progenitors, the common lymphoid and the common myeloid stem cell. The common lymphoid stem cell in turn gives rise to precursors of T cells (pro-T cells), B cells (pro-B cells), and natural killer cells.<sup>[2]</sup> The details of lymphoid differentiation are not discussed here, but it is worth pointing out that morphologic distinctions among lymphoid cells at various stages of differentiation are subtle at best. As a result, monoclonal antibodies recognizing differentiation-stage-specific antigens are used widely to define normal lymphocyte subsets ( Chapter 14 ). From the common myeloid stem cell arise at least three types of *committed stem cells* capable of differentiating along the erythroid/megakaryocytic, eosinophilic, and granulocyte-macrophage pathways.<sup>[3]</sup> In functional assays the committed stem cells are called colony-forming units (CFU), because each can give rise to colonies of differentiated progeny in vitro (see Fig. 13-1 ). From the various committed stem cells are derived intermediate stages and ultimately the morphologically recognizable precursors of the differentiated cells, such as proerythroblasts, myeloblasts, megakaryoblasts, monoblasts, and eosinophiloblasts, which in turn give rise to mature progeny.

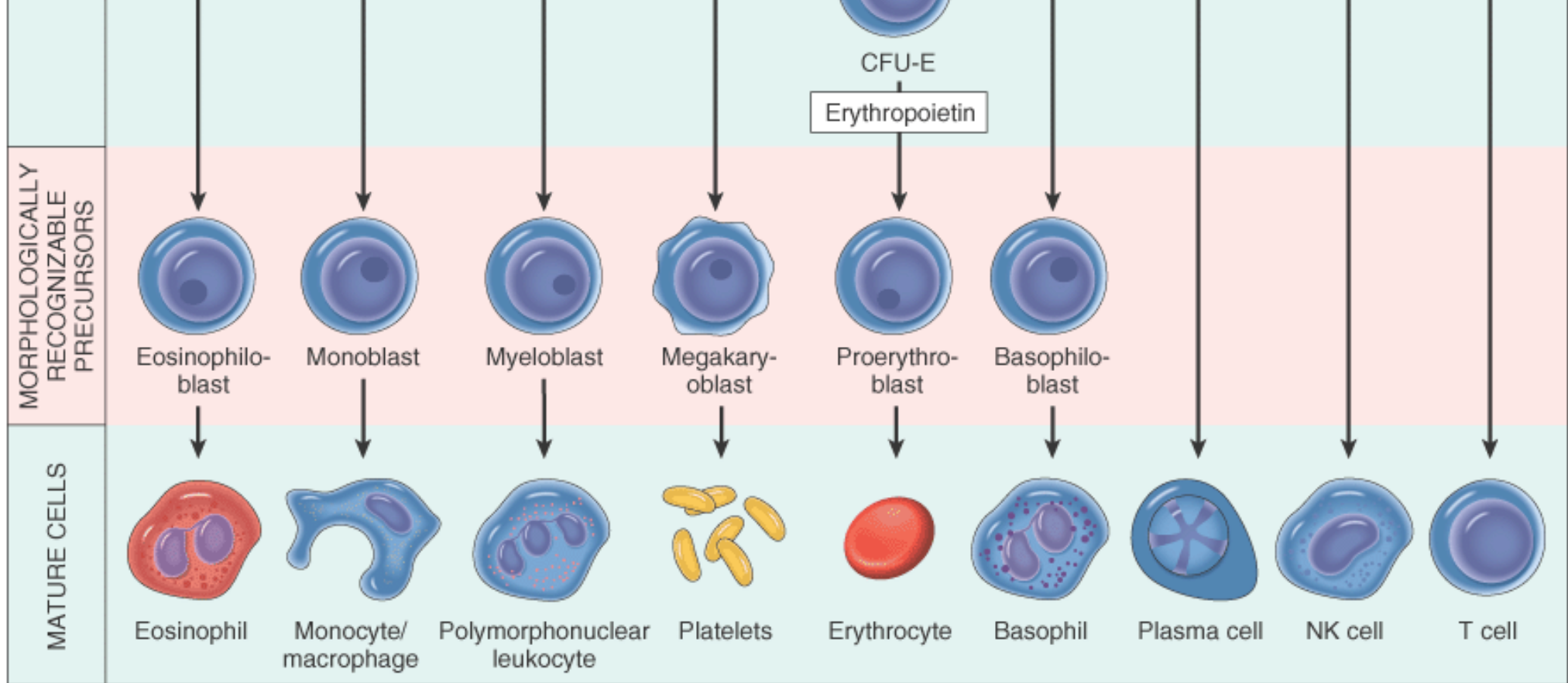
The specific characteristics of rare cells lying high up in the hierarchy shown in Figure 13-1 are still debated. What are agreed upon are certain overarching themes that apply to hematopoiesis. Since mature blood elements are terminally differentiated cells with finite life spans, their numbers must be replenished constantly. It follows that stem cells must not only differentiate, but also *self-renew*, a critical property of stem cells. Pluripotent stem cells have the greatest capacity for self-renewal, but normally most are not in cell cycle. As commitment to particular lines of differentiation proceeds, self-renewal becomes limited, but a greater fraction of committed cells divide actively. For example, few common myeloid stem cells are normally in cell cycle, but up to 50% of CFU-GM



MULTIPOTENT STEM CELLS

COMMITTED STEM CELLS





**TABLE 13-1** -- Classification of Anemia According to Underlying Mechanism

**Blood Loss**

Acute: trauma

Chronic: lesions of gastrointestinal tract, gynecologic disturbances

**Increased Rate of Destruction (Hemolytic Anemias)**

Intrinsic (intracorpuscular) abnormalities of red cells

••*Hereditary*

••Red cell membrane disorders

•••Disorders of membrane cytoskeleton: spherocytosis, elliptocytosis

•••Disorders of lipid synthesis: selective increase in membrane lecithin

••Red cell enzyme deficiencies

•••Glycolytic enzymes: pyruvate kinase deficiency, hexokinase deficiency

••••Enzymes of hexose monophosphate shunt: G6PD, glutathione synthetase
••Disorders of hemoglobin synthesis
••••Deficient globin synthesis: thalassemia syndromes
••••Structurally abnormal globin synthesis (hemoglobinopathies): sickle cell anemia, unstable hemoglobins
•• <i>Acquired</i>
••Membrane defect: paroxysmal nocturnal hemoglobinuria
Extrinsic (extracorpuscular) abnormalities
••Antibody mediated
••••Isohemagglutinins: transfusion reactions, erythroblastosis fetalis
••••Autoantibodies: idiopathic (primary), drug-associated, systemic lupus erythematosus, malignant neoplasms, mycoplasma infection
••Mechanical trauma to red cells
••••Microangiopathic hemolytic anemias: thrombotic thrombocytopenic purpura, disseminated intravascular coagulation
••••Cardiac traumatic hemolytic anemia
••Infections: malaria, hookworm
••Chemical injury: lead poisoning
••Sequestration in mononuclear phagocyte system: hypersplenism
<b><i>Impaired Red Cell Production</i></b>
Disturbance of proliferation and differentiation of stem cells: aplastic anemia, pure red cell aplasia, anemia of renal failure, anemia of endocrine disorders
Disturbance of proliferation and maturation of erythroblasts
••Defective DNA synthesis: deficiency or impaired use of vitamin B <sub>12</sub> and folic acid (megaloblastic anemias)
••Defective hemoglobin synthesis
••••Deficient heme synthesis: iron deficiency
••••Deficient globin synthesis: thalassemias
••Unknown or multiple mechanisms: sideroblastic anemia, anemia of chronic infections, myelophthisic anemias due to marrow infiltrations

(normocytic, microcytic, or macrocytic); degree of hemoglobinization, reflected in the color of red cells (normochromic or hypochromic); and other special features, such as shape. These red cell indices are often judged qualitatively by physicians, but precise quantitation is done in clinical laboratories using special instrumentation. The most useful red cell indices are as follows:

- *Mean cell volume*: the average volume of a red blood cell, expressed in femtoliters (cubic micrometers)
- *Mean cell hemoglobin*: the average content (mass) of hemoglobin per red blood cell, expressed in picograms
- *Mean cell hemoglobin concentration*: the average concentration of hemoglobin in a given volume of packed red blood cells, expressed in grams per deciliter



- *Red blood cell distribution width*: the coefficient of variation of red blood cell volume

Adult reference ranges for red cell indices are shown in Table 13-2 .

Whatever its cause, anemia leads to certain clinical features when sufficiently severe. Patients appear pale. Weakness, malaise, and easy fatigability are common complaints. The lowered oxygen content of the circulating blood leads to dyspnea on mild exertion. The nails can become brittle, lose their usual convexity, and assume a concave spoon shape (koilonychia). Anoxia can cause fatty change in the liver, myocardium, and kidney. If fatty changes in the myocardium are sufficiently severe, cardiac failure can develop and compound the respiratory difficulty caused by reduced oxygen transport. On occasion, the myocardial hypoxia manifests as angina pectoris, particularly when complicated by preexisting coronary artery disease. With acute blood loss and shock, oliguria and anuria can develop due to renal hypoperfusion. Central nervous system hypoxia can cause headache, dimness of vision, and faintness.

## ANEMIAS OF BLOOD LOSS

### Acute Blood Loss

The clinical and morphologic reactions to blood loss depend on the rate of hemorrhage and whether the bleeding

**TABLE 13-2** -- Adult Reference Ranges for Red Blood Cells \*

Measurement (units)	Men	Women
Hemoglobin (gm/dL)	13.6–17.2	12.0–15.0
Hematocrit (%)	39–49	33–43
Red cell count (10 <sup>6</sup> /μL)	4.3–5.9	3.5–5.0
Reticulocyte count (%)	0.5–1.5	
Mean cell volume (μm <sup>3</sup> )	82–96	
Mean corpuscular hemoglobin (pg)	27–33	
Mean corpuscular hemoglobin concentration (gm/dL)	33–37	
RBC distribution width	11.5–14.5	
RBC, red blood cell.		

\*Reference ranges vary among laboratories. The reference ranges for the laboratory providing the result should always be used in interpreting the test result.

is external or internal. The effects of acute blood loss are mainly due to the loss of intravascular volume, which can lead to cardiovascular collapse, shock, and death. If the patient survives, the blood volume is rapidly restored by shift of water from the interstitial fluid compartment. The resulting hemodilution lowers the hematocrit. Reduction in the oxygenation of renal

juxtaglomerular cells triggers increased production of erythropoietin, which stimulates the proliferation of committed erythroid stem cells (CFU-E) in the marrow. It takes about 5 days for the progeny of these CFU-Es to fully differentiate, an event marked by the appearance of increased numbers of newly released red cells (reticulocytes) in the peripheral blood. The iron in hemoglobin is recaptured if red cells are lost internally, as into the peritoneal cavity, but external bleeding leads to iron loss and possible iron deficiency, which can hamper restoration of normal red cell counts.

The earliest change in the peripheral blood immediately after acute blood loss is *leukocytosis*, due to the mobilization of granulocytes from marginal pools. Initially, red cells appear normal in size and color (normocytic, normochromic). However, as marrow production increases, *there is a striking increase in the reticulocyte count, reaching 10% to 15% after 7 days*. Reticulocytes are recognizable as polychromatophilic macrocytes in the usual blood smear. Early recovery from blood loss is often accompanied by *thrombocytosis*, which is caused by increased platelet production.

### Chronic Blood Loss

Chronic blood loss induces anemia only when the rate of loss exceeds the regenerative capacity of the marrow or when iron reserves are depleted. Iron deficiency anemia, which has identical features regardless of underlying cause (e.g., bleeding, malnutrition, malabsorption states), will be discussed later.

### HEMOLYTIC ANEMIAS

Hemolytic anemias share the following features:

- *A shortened red cell life span (normal = 120 days); that is, premature destruction of red cells*
- *Elevated erythropoietin levels and increased erythropoiesis in the marrow and other sites*, to compensate for the loss of red cells
- *Accumulation of the products of hemoglobin catabolism, due to an increased rate of red cell destruction*

The physiologic destruction of senescent red cells takes place within the mononuclear phagocytic cells of the spleen. In the great majority of hemolytic anemias, the premature destruction of red cells also occurs within the mononuclear phagocyte system (extravascular hemolysis), which undergoes a form of work-related hyperplasia marked by splenomegaly. Much less commonly, lysis of red cells within the vascular compartment (intravascular hemolysis) predominates.

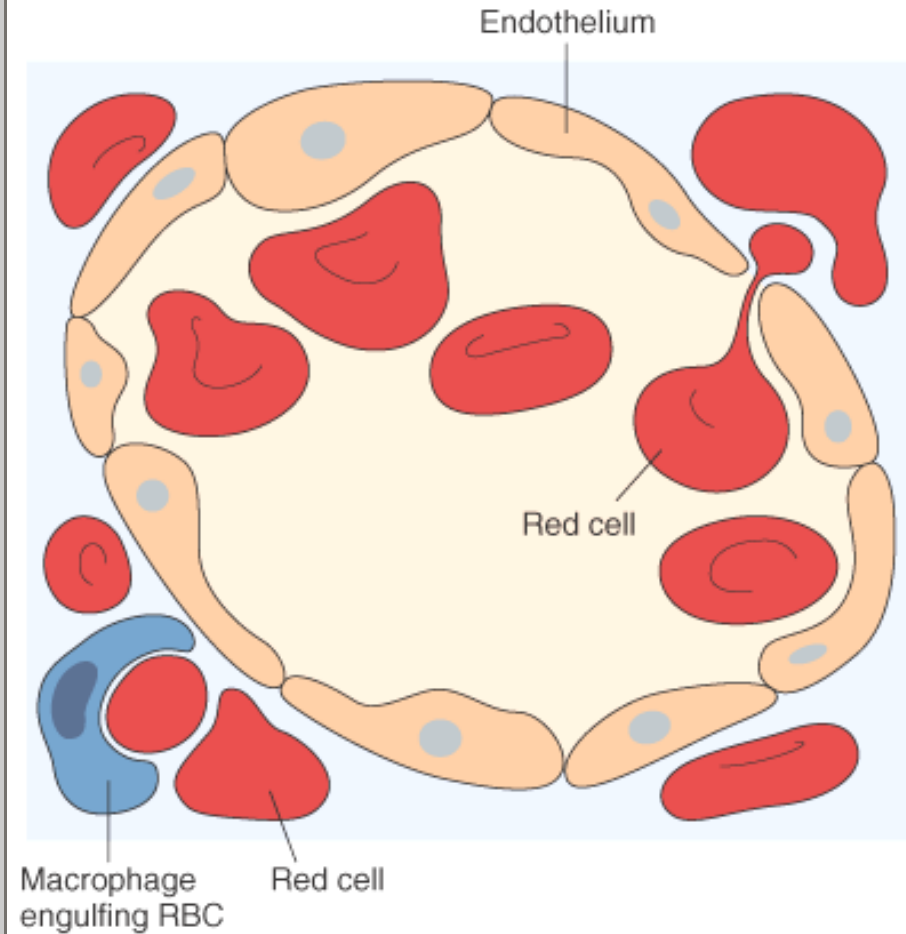
*Intravascular hemolysis* of red cells is caused by mechanical injury, complement fixation, infection by intracellular parasites such as falciparum malaria ( Chapter 8 ), or exogenous toxic factors. Mechanical injury caused by defective cardiac valves, thrombi within the microcirculation, or repetitive physical trauma (marathon running, bongo drum beating) can physically lyse red cells. Complement fixation can occur on antibody-coated cells during transfusion of mismatched blood. Toxic injury is exemplified by clostridial sepsis, which releases toxins that attack the red cell membrane.

Whatever the mechanism, *intravascular hemolysis is manifested by (1) hemoglobinemia, (2) hemoglobinuria, (3) jaundice, and (4) hemosiderinuria*. Free hemoglobin in plasma is promptly bound by an  $\alpha_2$ -globulin (haptoglobin), producing a complex that is rapidly cleared by the mononuclear phagocyte system, thus preventing excretion into the urine. *Decreased serum haptoglobin is characteristic of intravascular hemolysis*. When the haptoglobin is depleted, free hemoglobin is prone to oxidation to methemoglobin, which is brown in color. The renal proximal tubular cells reabsorb and catabolize much of the filtered hemoglobin and methemoglobin, but some passes out with the urine, imparting a red-brown color. Iron released from hemoglobin can accumulate within tubular cells, giving rise to renal hemosiderosis. Concomitantly, heme groups derived from the complexes are catabolized to bilirubin within the mononuclear phagocyte system, leading to jaundice. In hemolytic anemias, the serum bilirubin is unconjugated and the level of hyperbilirubinemia depends on the functional capacity of the liver and the rate of hemolysis. When the liver is normal, jaundice is rarely severe. Excessive bilirubin excreted by the liver into the gastrointestinal tract leads to increased formation and fecal excretion of urobilin ( Chapter 18 ).

*Extravascular hemolysis* takes place whenever red cells are rendered "foreign" or become less deformable. Since extreme alterations in shape are required for red cells to navigate the splenic sinusoids successfully, reduced deformability makes the passage difficult and leads to sequestration within the cords, followed by phagocytosis ( Fig. 13-2 ). This is an important

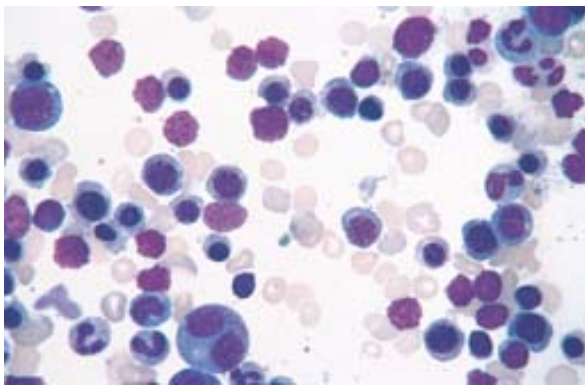
pathogenetic mechanism of extravascular hemolysis in a variety of hemolytic anemias. With extravascular hemolysis,

**Figure 13-2** Schematic of splenic sinus (electron micrograph). A red cell is in the process of squeezing from the red pulp cords into the sinus lumen. Note the degree of deformability required for red cells to pass through the wall of the sinus.

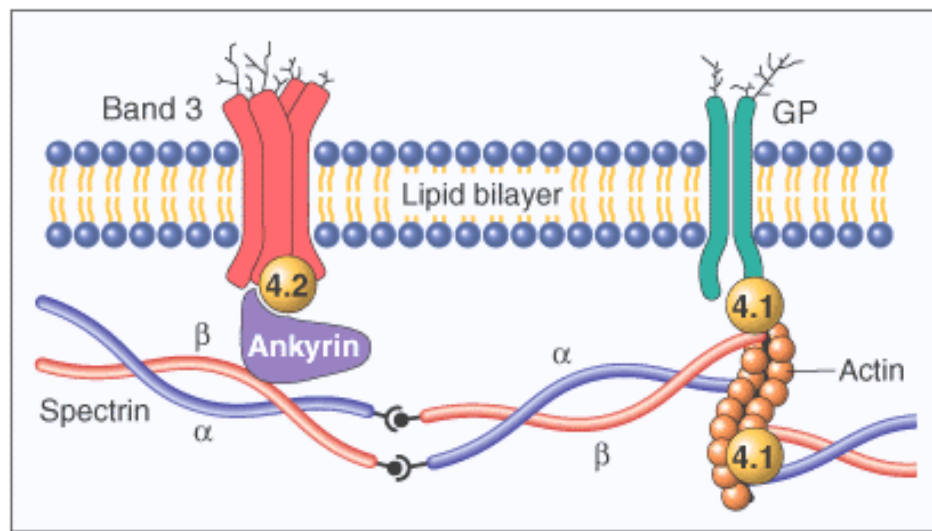


**Figure 13-3** Marrow smear from a patient with hemolytic anemia. The marrow reveals greatly increased numbers of maturing erythroid progenitors (normoblasts). (*Courtesy of Dr. Steven Kroft, Department of Pathology, University of Texas Southwestern Medical School, Dallas, TX.*)

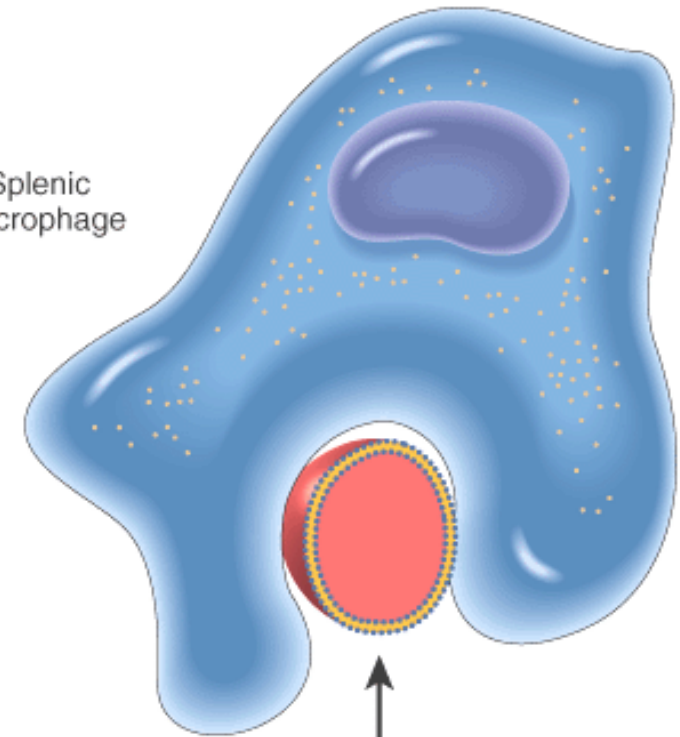




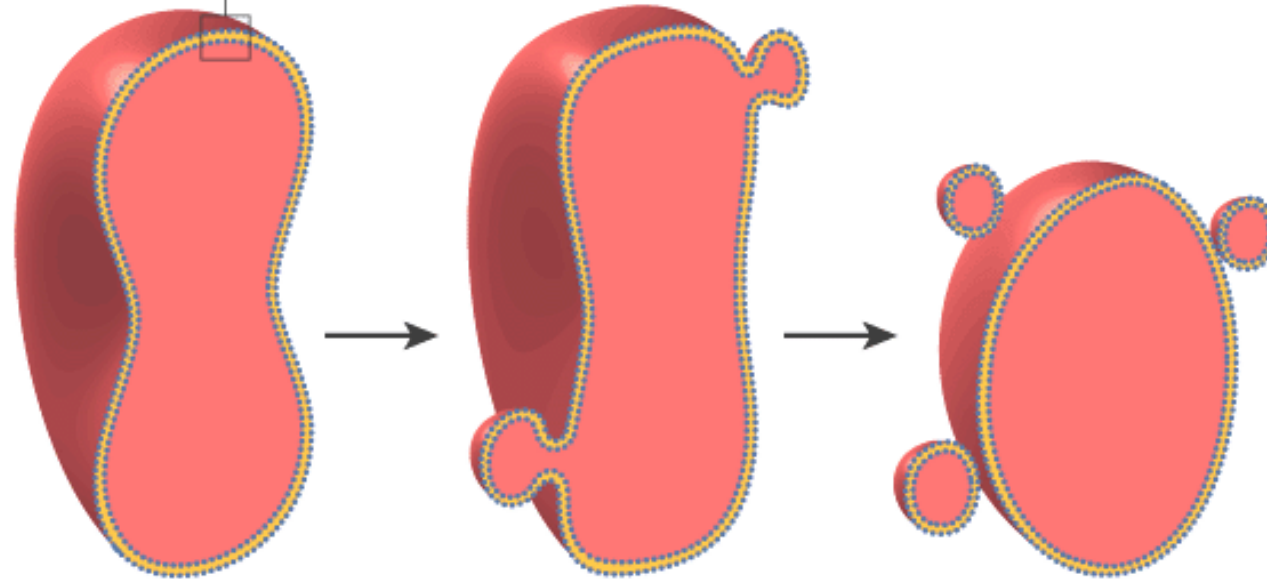
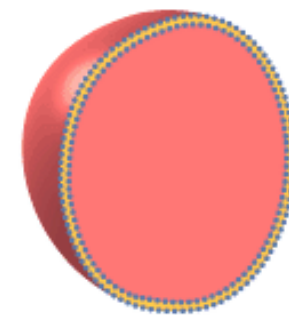
**Figure 13-4** Schematic representation of the red cell membrane cytoskeleton and alterations leading to spherocytosis and hemolysis. Mutations weakening interactions involving  $\alpha$ -spectrin,  $\beta$ -spectrin, ankyrin, band 4.2, or band 3 all cause the normal biconcave red cell to lose membrane fragments and adopt a spherical shape. Such spherocytic cells are less deformable than normal and therefore become trapped in the splenic cords, where they are phagocytosed by macrophages.



Splenic macrophage

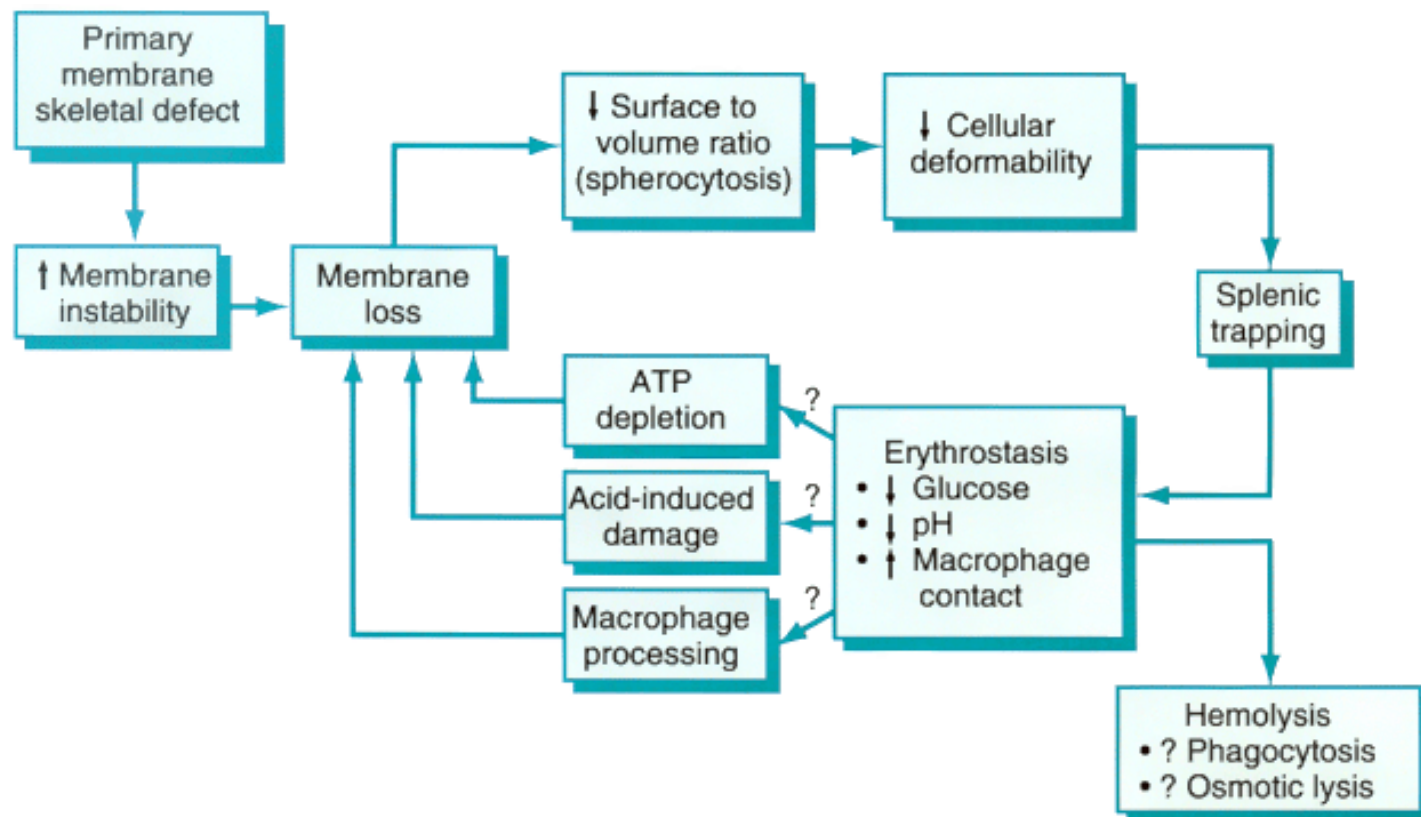


Spherocyte

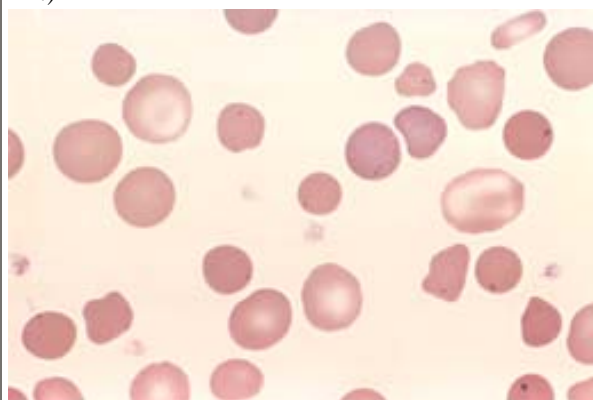


Normal

**Figure 13-5** Model of the pathophysiology of hereditary spherocytosis. (Adapted from Wyngaarden JB, et al [eds]: Cecil Textbook of Medicine, 19th ed. Philadelphia, WB Saunders, 1992, p. 859.)

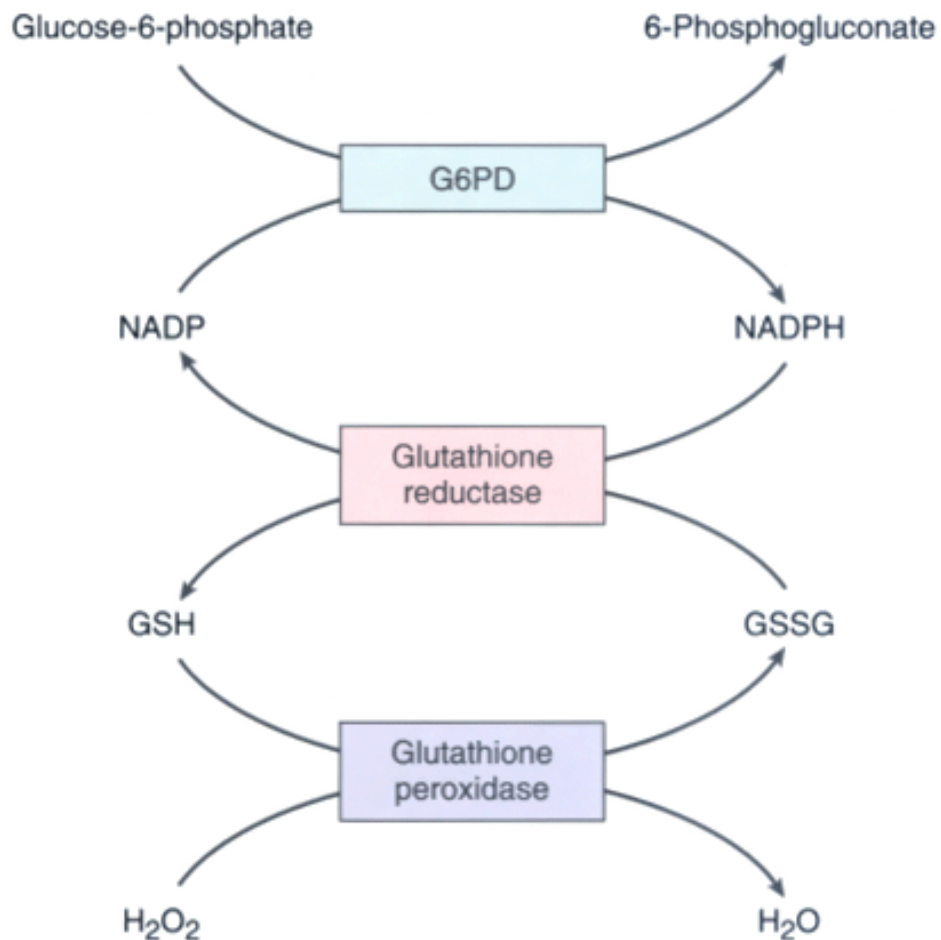


**Figure 13-6** Hereditary spherocytosis (peripheral smear). Note the anisocytosis and several dark-appearing spherocytes with no central pallor. Howell-Jolly bodies (small dark nuclear remnants) are also present in red cells of this asplenic patient. (Courtesy of Dr. Robert W. McKenna, Department of Pathology, University of Texas Southwestern Medical School, Dallas, TX.)

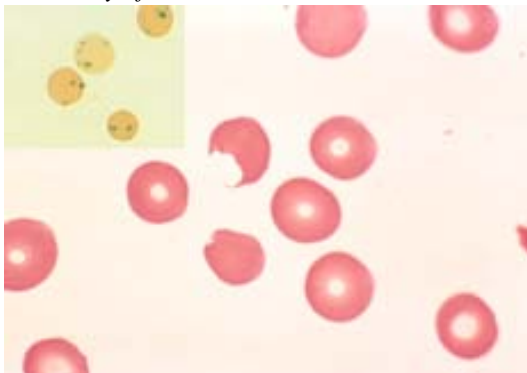


**Figure 13-7** Role of glucose-6-phosphate dehydrogenase (G6PD) in defense against oxidant injury. The disposal of  $H_2O_2$ , a potential oxidant, is dependent on the adequacy of reduced glutathione (GSH), which is generated by the action of NADPH. The synthesis of NADPH is dependent on the activity of G6PD. GSSG, oxidized glutathione.



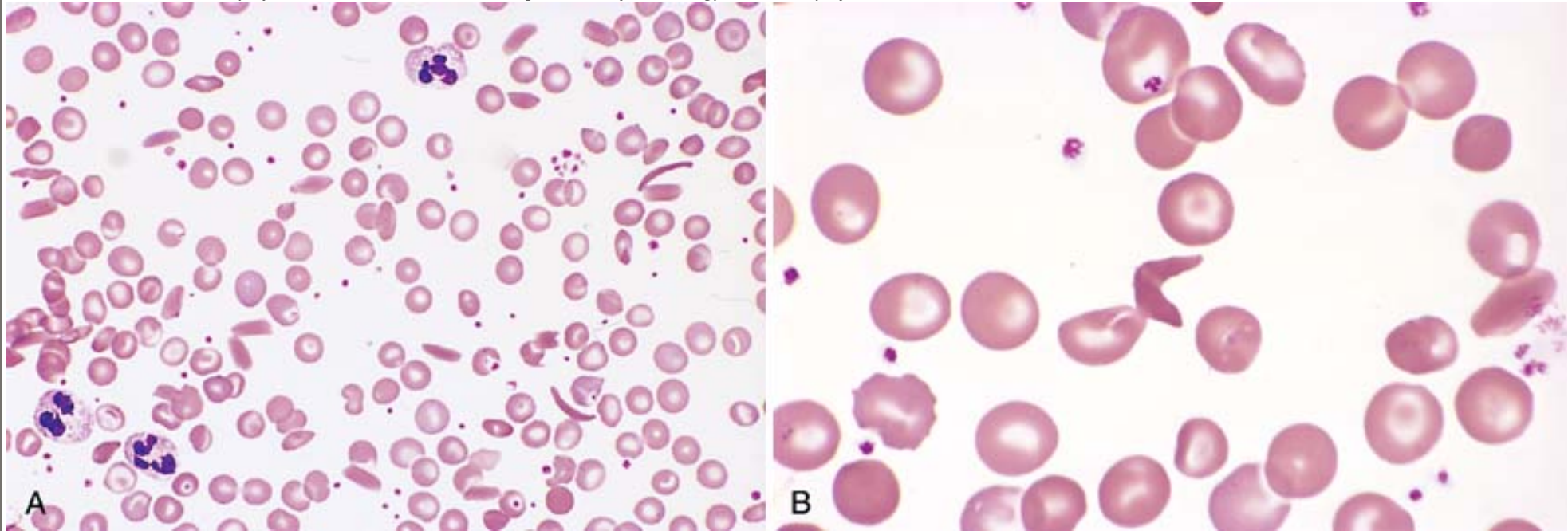


**Figure 13-8** G6PD deficiency: effects of oxidant drug exposure (peripheral blood smear). *Inset*, Red cells with precipitates of denatured globin (Heinz bodies) revealed by supravital staining. As the splenic macrophages pluck out these inclusions, "bite cells" like the one in this smear are produced. (Courtesy of Dr. Robert W. McKenna, Department of Pathology, University of Texas Southwestern Medical School, Dallas, TX.)

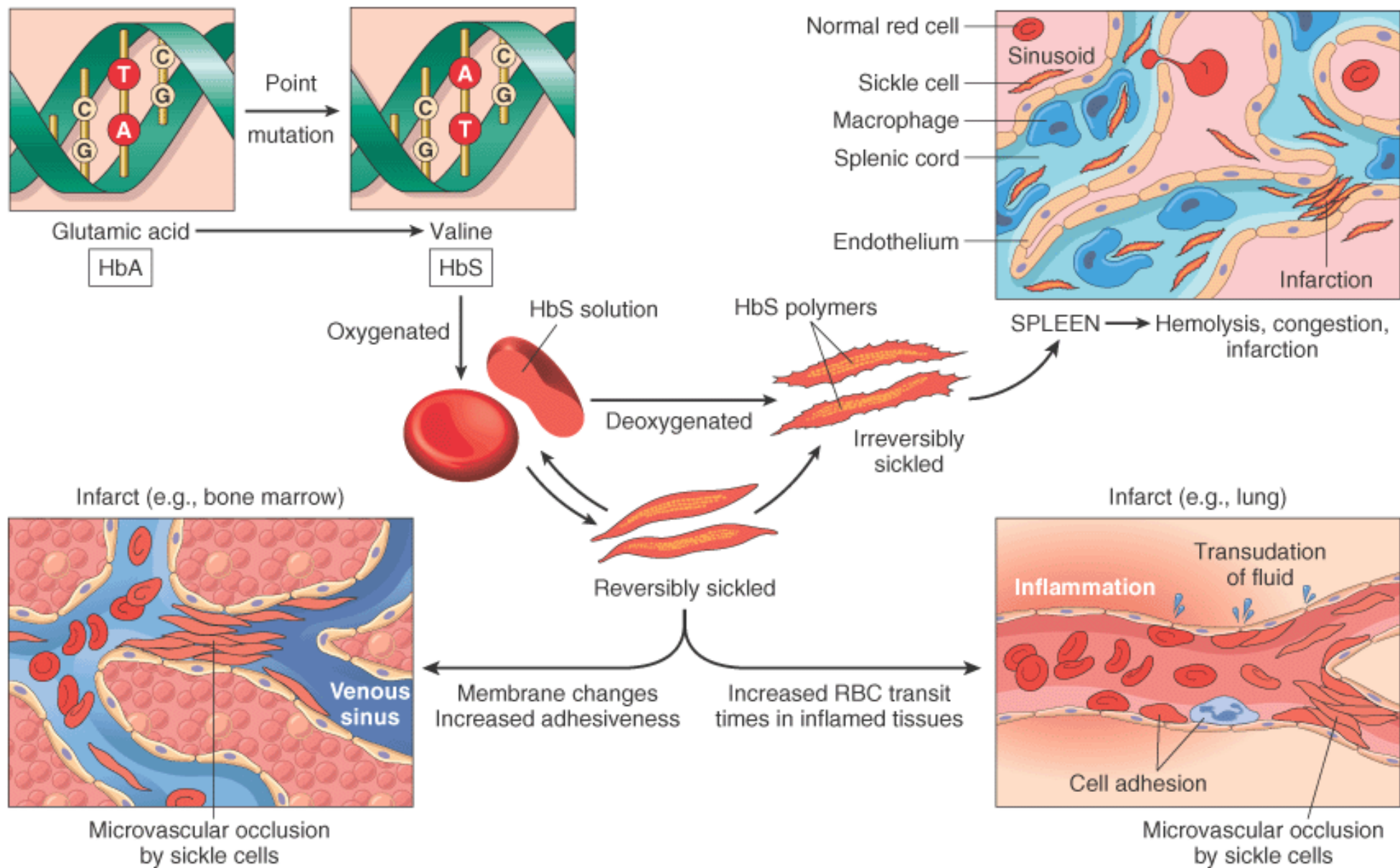


**Figure 13-9** Sickle cell anemia (peripheral blood smear). A, Low magnification show sickle cells, anisocytosis, and poikilocytosis. B, Higher magnification shows an irreversibly sickled

cell in the center. (Courtesy of Dr. Robert W. McKenna, Department of Pathology, University of Texas Southwestern Medical School, Dallas, TX.)

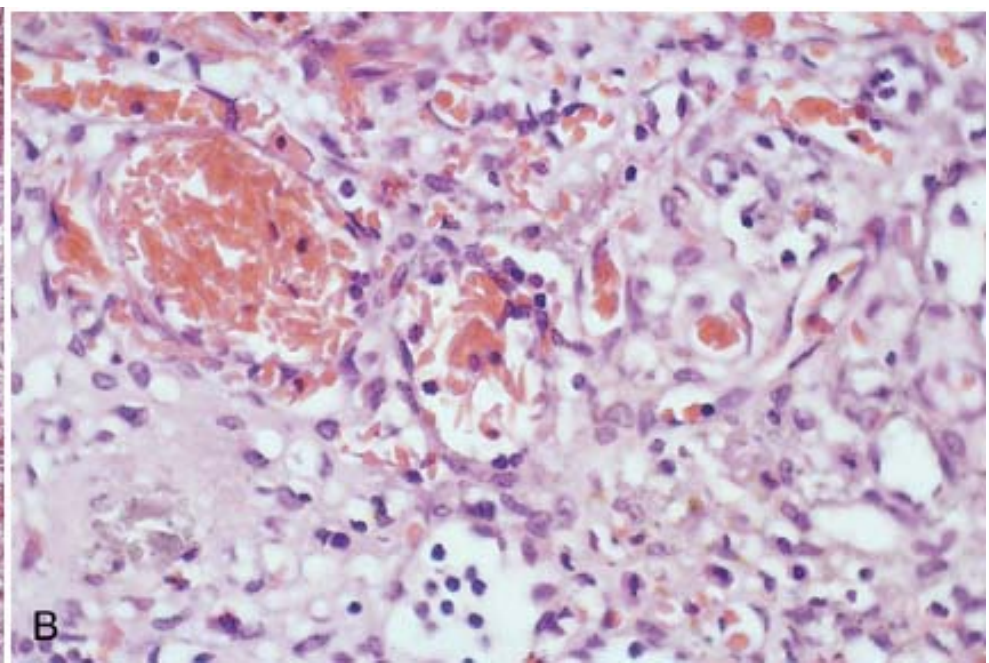
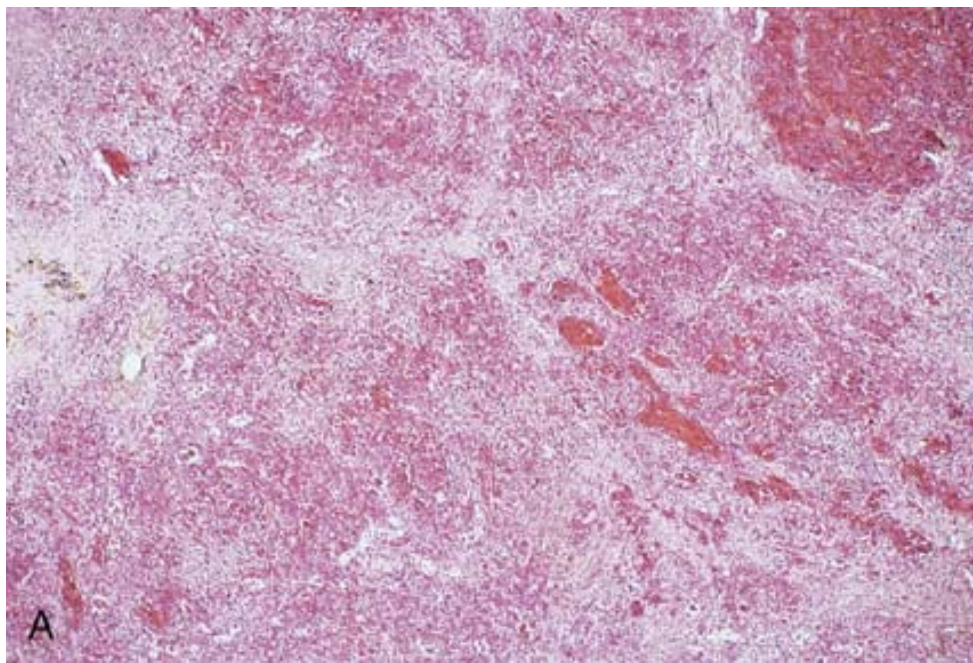


**Figure 13-10** Pathophysiology of sickle cell anemia.

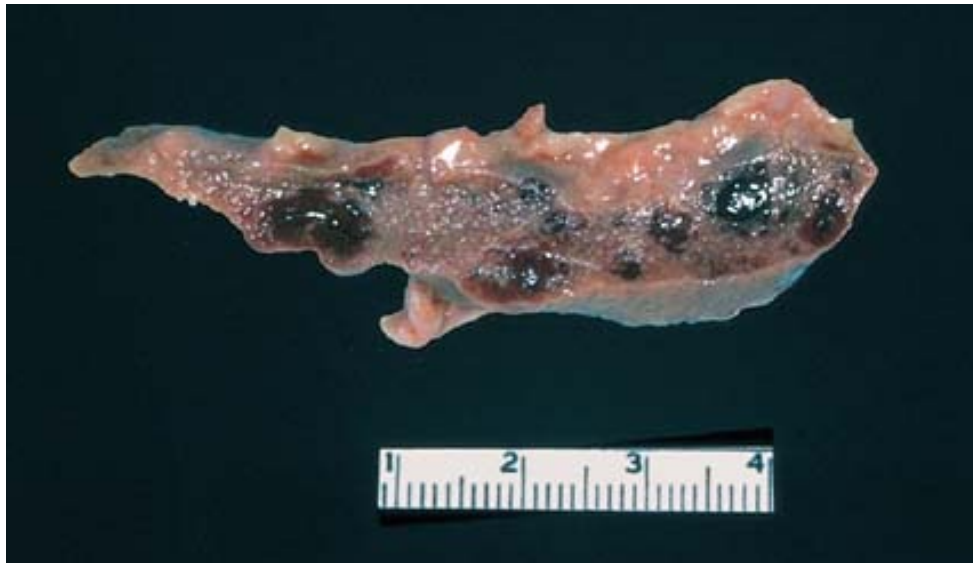

**Figure 13-11** A, Spleen in sickle cell anemia (low power). Red pulp cords and sinusoids are markedly congested; between the congested areas, pale areas of fibrosis resulting from ischemic damage are evident. B, Under high power, splenic sinusoids are dilated and filled with sickled red cells. (Courtesy of Dr. Darren Wirthwein, Department of Pathology, University of Texas Southwestern Medical School, Dallas, TX.)

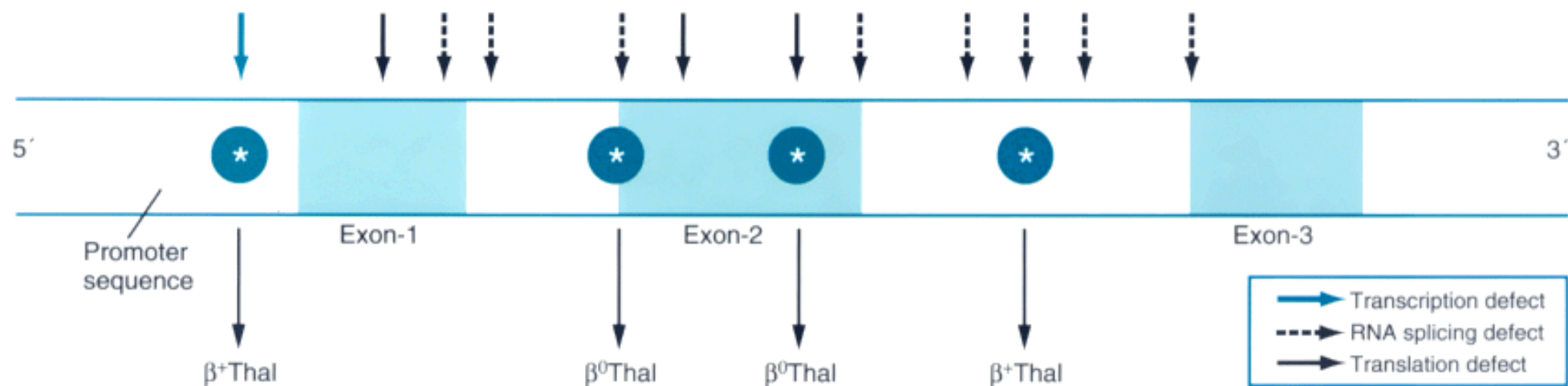




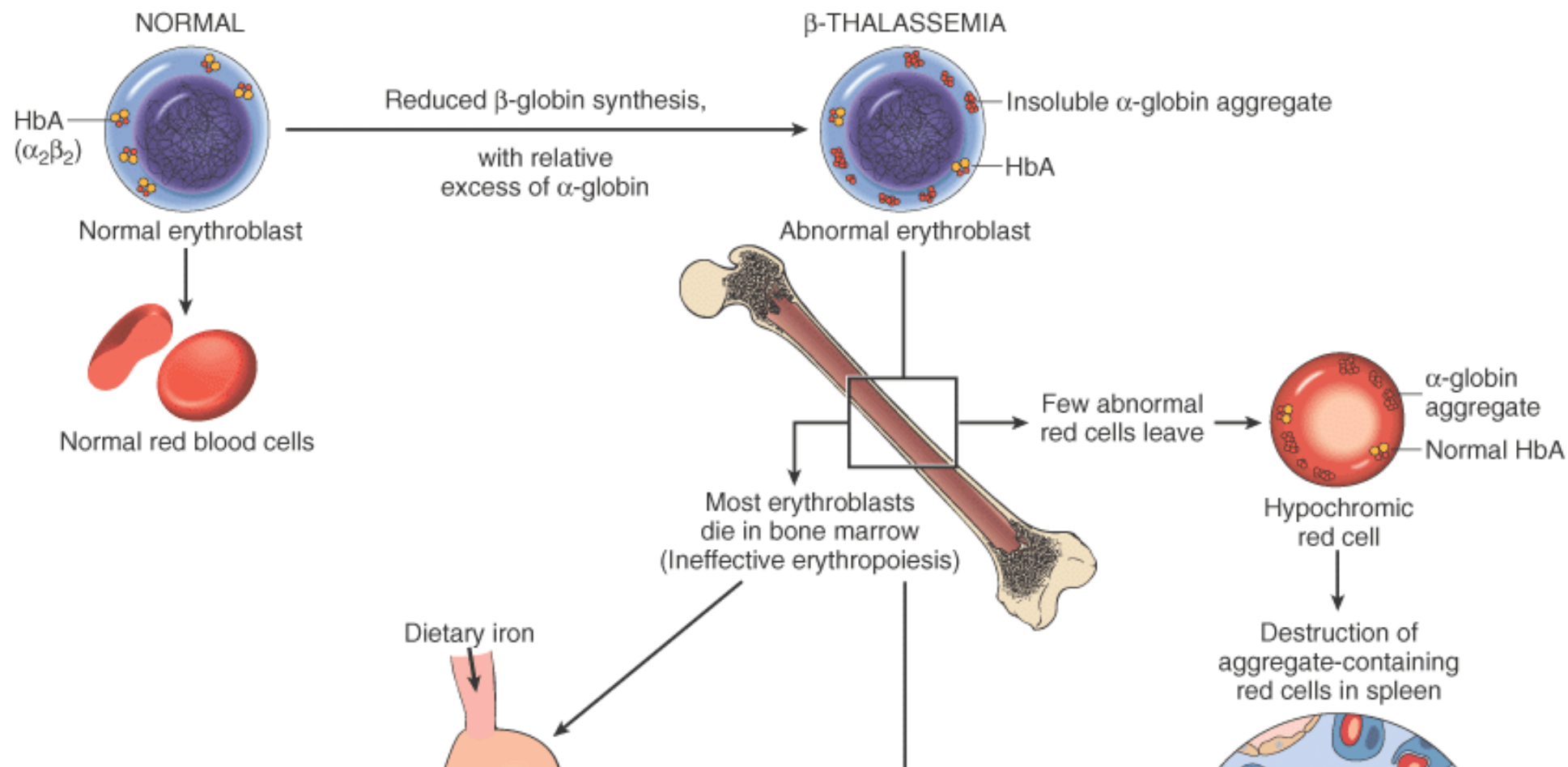
**Figure 13-12** Splenic remnant in sickle cell anemia. (Courtesy of Drs. Dennis Burns and Darren Wirthwein, Department of Pathology, University of Texas Southwestern Medical School, Dallas, TX.)

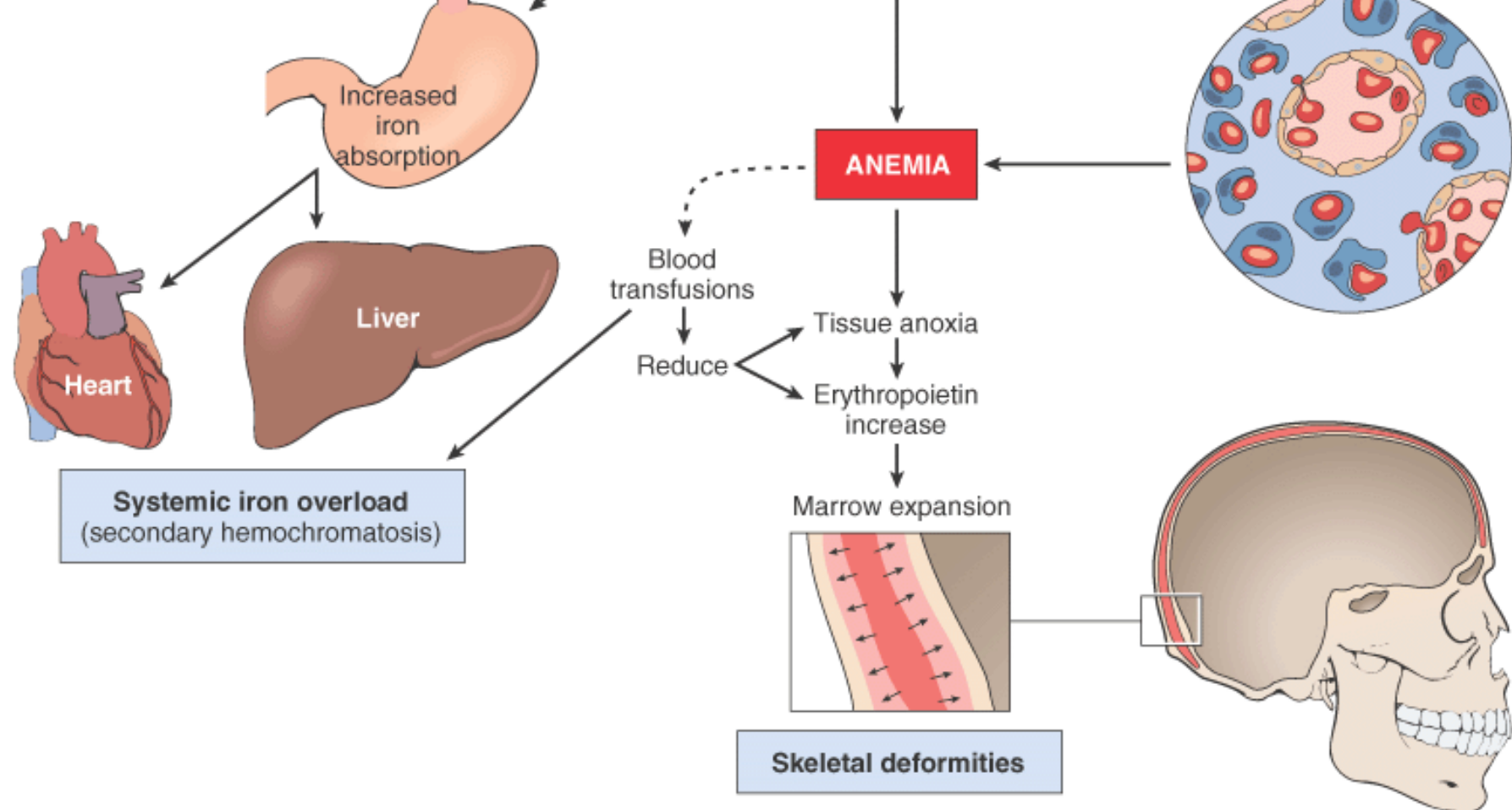


**Figure 13-13** Diagrammatic representation of the  $\beta$ -globin gene. Arrows denote sites where point mutations giving rise to thalassemia have been identified.



**Figure 13-14** Pathogenesis of  $\beta$ -thalassemia major. Note that aggregates of unpaired  $\alpha$ -globin chains are not visible in routinely stained blood smears. Blood transfusions are a double-edged sword, correcting the anemia and thereby reducing the stimulus for marrow expansion, but also adding to systemic iron overload.





**TABLE 13-3** -- Clinical and Genetic Classification of Thalassemias

Clinical Nomenclature	Genotype	Disease	Molecular Genetics
<b><math>\beta</math>-Thalassemias</b>			
Thalassemia major	Homozygous $\beta^0$ -thalassemia ( $\beta^0/\beta^0$ )	Severe; requires blood transfusions	Rare gene deletions in $\beta^0/\beta^0$ Defects in transcription, processing, or translation of $\beta$ -globin mRNA
	Homozygous $\beta^+$ -thalassemia ( $\beta^+/\beta^+$ )		
Thalassemia intermedia	$\beta^0/\beta$	Severe, but does not require regular blood transfusions	
	$\beta^+/\beta^+$		
Thalassemia minor	$\beta^0/\beta$	Asymptomatic with mild or absent anemia; red cell abnormalities seen	
	$\beta^+/\beta$		



$\alpha$ -Thalassemias			
Hydrops fetalis	-/- -/-	Lethal in utero without transfusions	Mainly gene deletions
HbH disease	-/- $-\alpha$	Severe; resembles $\beta$ -thalassemia intermedia	
$\alpha$ -Thalassemia trait	-/- $\alpha/\alpha$ (Asian)	Asymptomatic, like $\beta$ -thalassemia minor	
	-/ $\alpha$ $-\alpha/\alpha$ (black African)		
Silent carrier	-/ $\alpha$ $\alpha/\alpha$	Asymptomatic; no red cell abnormality	

the following discussions of thalassemia major and minor ( Table 13-3 ).

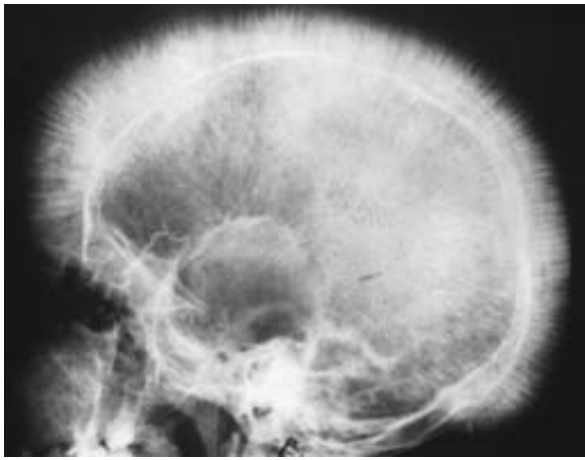
#### Thalassemia Major.

$\beta$ -Thalassemia is most common in Mediterranean countries and parts of Africa and Southeast Asia. In the United States, the incidence is highest in immigrants from these areas. As indicated in Table 13-3 , the genotype of affected patients can be  $\beta^+/\beta^+$  ,  $\beta^0/\beta^0$  , or  $\beta^0/\beta^+$  . With all these genotypes, the anemia manifests 6 to 9 months after birth, as hemoglobin synthesis switches from HbF to HbA. In untransfused patients, hemoglobin levels range between 3 and 6 gm/dL. The peripheral blood smear shows severe red cell morphologic abnormalities, including marked anisocytosis and poikilocytosis (variation in size and shape, respectively), microcytosis (small size), and hypochromia (poor hemoglobinization). Target cells (so called because hemoglobin collects in the center of the cells), basophilic stippling, and fragmented red cells are also common. Inclusions of aggregated  $\alpha$  chains are efficiently removed by the spleen and not easily found in peripheral blood smears. The reticulocyte count is elevated, but because of ineffective erythropoiesis is lower than expected for the severity of anemia. Variable numbers of poorly hemoglobinized normoblasts are seen in the peripheral blood due to "stress" erythropoiesis and abnormal release of progenitors from sites of extramedullary hematopoiesis. The red cells can completely lack HbA ( $\beta^0/\beta^0$  genotype) or contain small amounts ( $\beta^+/\beta^+$  or  $\beta^0/\beta^+$  genotypes). HbF is markedly increased and indeed constitutes the major red cell hemoglobin. HbA<sub>2</sub> levels may be normal, low, or high.

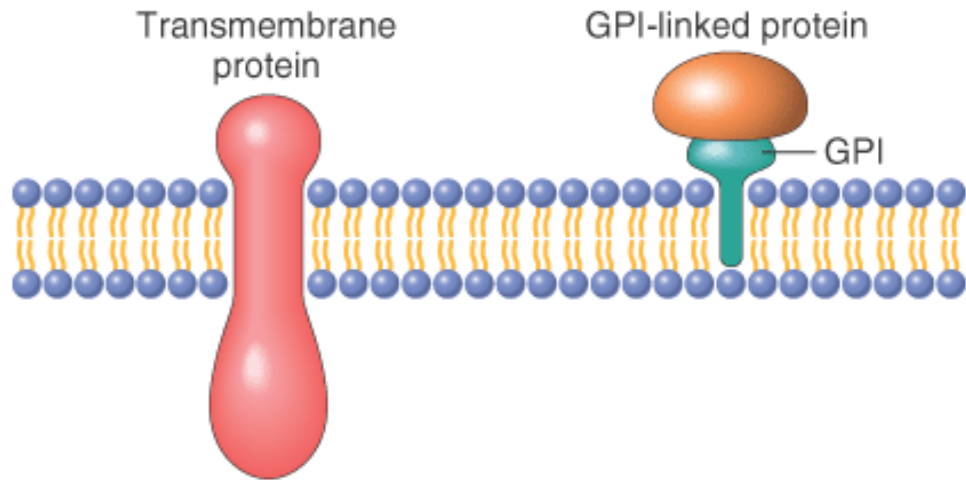
#### Morphology.

The major morphologic alterations, in addition to those found in all hemolytic anemias, involve the bone marrow and spleen. In the untransfused patient, there is striking expansion of hematopoietically active marrow, particularly in facial bones. This erodes existing cortical bone and induces new bone formation, giving rise to a "crew-cut" appearance on X-rays ( Fig. 13-15 ). Both mononuclear phagocytic cell hyperplasia and extramedullary hematopoiesis contribute to enlargement of the spleen, which can weigh up to 1500 gm.

**Figure 13-15** Thalassemia: x-ray film of the skull showing new bone formation on the outer table, producing perpendicular radiations resembling a crew-cut. (*Courtesy of Dr. Jack Reynolds, Department of Radiology, University of Texas Southwestern Medical School, Dallas, TX.*)



**Figure 13-16** Two kinds of membrane proteins: transmembrane and glycosyl phosphatidyl inositol (GPI)-linked. The latter are anchored to cell membranes through a covalent attachment to a glycosyl phosphatidyl inositol moiety. In PNH, GPI cannot be synthesized, leading to a global deficiency of GPI-linked membrane proteins.



**TABLE 13-4** -- Classification of Immunohemolytic Anemias

<i>Warm Antibody Type</i>
The antibody is of the IgG type, does not usually fix complement, and is active at 37°C.
<i>Primary</i> (idiopathic)
<i>Secondary</i>
••Lymphomas and leukemias
••Other neoplastic diseases
••Autoimmune disorder (particularly systemic lupus erythematosus)

••Drugs
<b><i>Cold Agglutinin Type</i></b>
The antibodies are IgM and most active in vitro at 0° to 4°C.
••Antibodies dissociate at 30°C or above; agglutination of cells by IgM and complement fixation occurs only in peripheral cool parts of the body (e.g., fingers, ears, and toes).
<i>Acute</i> (mycoplasmal infection, infectious mononucleosis)
<i>Chronic</i>
••Idiopathic
••Associated with lymphoma
<b><i>Cold Hemolysins (Paroxysmal Cold Hemoglobinuria)</i></b>
IgG antibodies bind red cells at low temperature, fix complement, and cause hemolysis when the temperature is raised above 30°C.

this test, patient red cells are mixed with heterologous antisera specific for human immunoglobulins or complement. If either is present, red cells are cross-linked by multivalent antibodies, causing clumping or agglutination. The indirect Coombs antiglobulin test, in which patient serum is tested for its ability to agglutinate defined test red cells, can then be used to characterize the target of the autoantibody. The temperature dependence of this reaction also helps to define the type of antibody responsible. Quantitative immunologic tests to measure such antibodies directly are also available.

#### **Warm Antibody Immunoheolytic Anemia.**

This is the most common form (48% to 70%) of immune hemolytic anemia. About 50% of cases are idiopathic (primary); the remainder arise secondarily in the setting of a predisposing condition (see Table 13-4 ) or drug exposure. Most causative antibodies are of the immunoglobulin G (IgG) class; only sometimes are IgA antibodies culpable. Most red cell destruction in this form of hemolytic disease is extravascular. IgG-coated red cells bind Fc receptors on monocytes and splenic macrophages, which results in loss of red cell membrane during "partial" phagocytosis. As in hereditary spherocytosis, *the loss of cell membrane converts the red cells to spherocytes, which are sequestered and removed in the spleen, the major site of red cell destruction in this disorder. Thus, moderate splenomegaly is characteristic of this form of anemia.*

As with other forms of autoimmunity, the cause of autoantibody formation is largely unknown. In many cases, the antibodies are directed against the Rh blood group antigens. The mechanisms of drug-induced hemolysis are better understood. Two predominant immunologic mechanisms have been implicated.<sup>[31]</sup>

- *Hapten model.* The drugs—exemplified by penicillin and cephalosporins—act as haptens by binding to the red cell membrane. Antibodies directed against the cell-bound drug result in the destructive sequence cited before. This form of hemolytic anemia is usually caused by large intravenous doses of the antibiotic and occurs 1 to 2 weeks after onset of therapy. Sometimes the antibodies bind only to the offending drug, as in penicillin-induced hemolytic anemia. In other cases, such as quinidine-induced hemolysis, the antibodies recognize a complex of the drug and a membrane protein. In drug-induced hemolytic anemias, the destruction of red cells can occur intravascularly after fixation of complement or extravascularly in the mononuclear phagocyte system.
- *Autoantibody model.* These drugs, of which the antihypertensive agent  $\alpha$ -methyldopa is the prototype, in some manner initiate the production of antibodies directed against intrinsic red cell antigens, in particular the Rh blood group antigens. Approximately 10% of patients taking  $\alpha$ -methyldopa develop autoantibodies, as assessed by the direct Coombs test. However, only 1% develops clinically significant hemolysis.

#### **Cold Agglutinin Immunoheolytic Anemia.**

This form of immunoheolytic anemia is caused by so-called *cold agglutinins*, IgM antibodies that bind and agglutinate red cells avidly at low temperatures (0° to 4°C).<sup>[32]</sup> It is less