

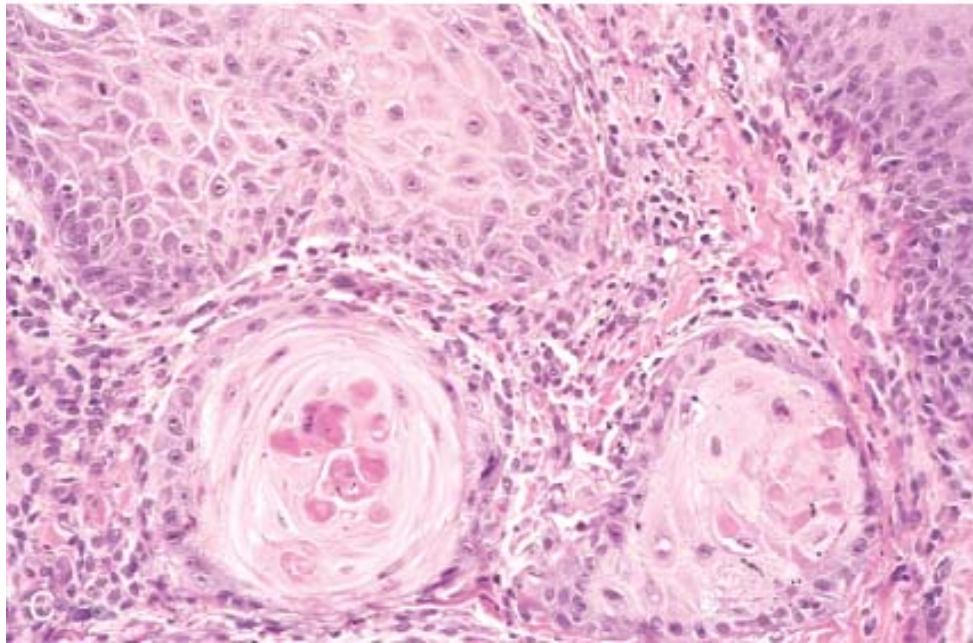
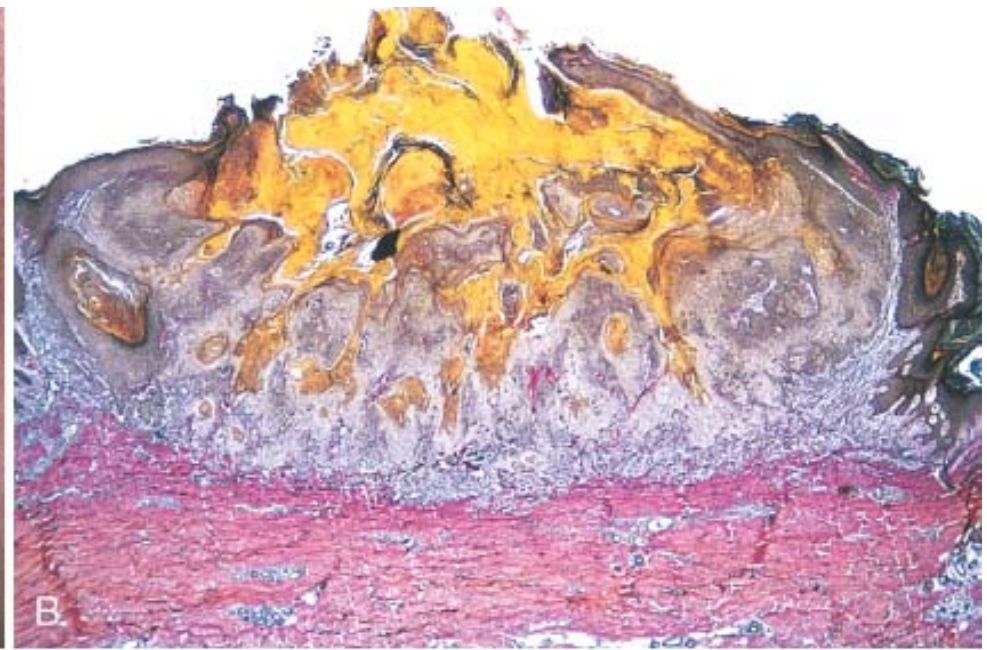
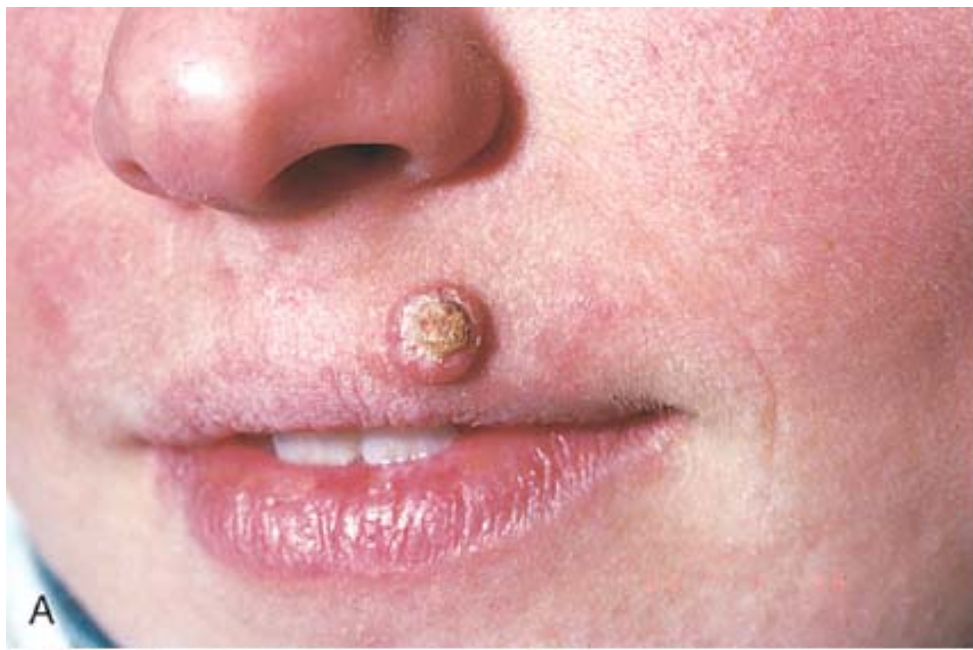### ACTINIC KERATOSIS

[A-PDF Split DEMO : Purchase from www.A-PDF.com to remove the watermark](http://www.A-PDF.com)

Before the development of overt malignancy of the epidermis, a series of progressively dysplastic changes occur, a phenomenon analogous to the atypia that precedes carcinoma of the squamous mucosa of the uterine cervix ( Chapter 22 ). Because this dysplasia is usually the result of chronic exposure to sunlight and is associated with build-up of excess keratin, these lesions are called *actinic keratoses*. As would be expected, they occur with particularly high incidence in lightly pigmented individuals. Exposure to ionizing radiation, hydrocarbons, and arsenicals may induce similar lesions.

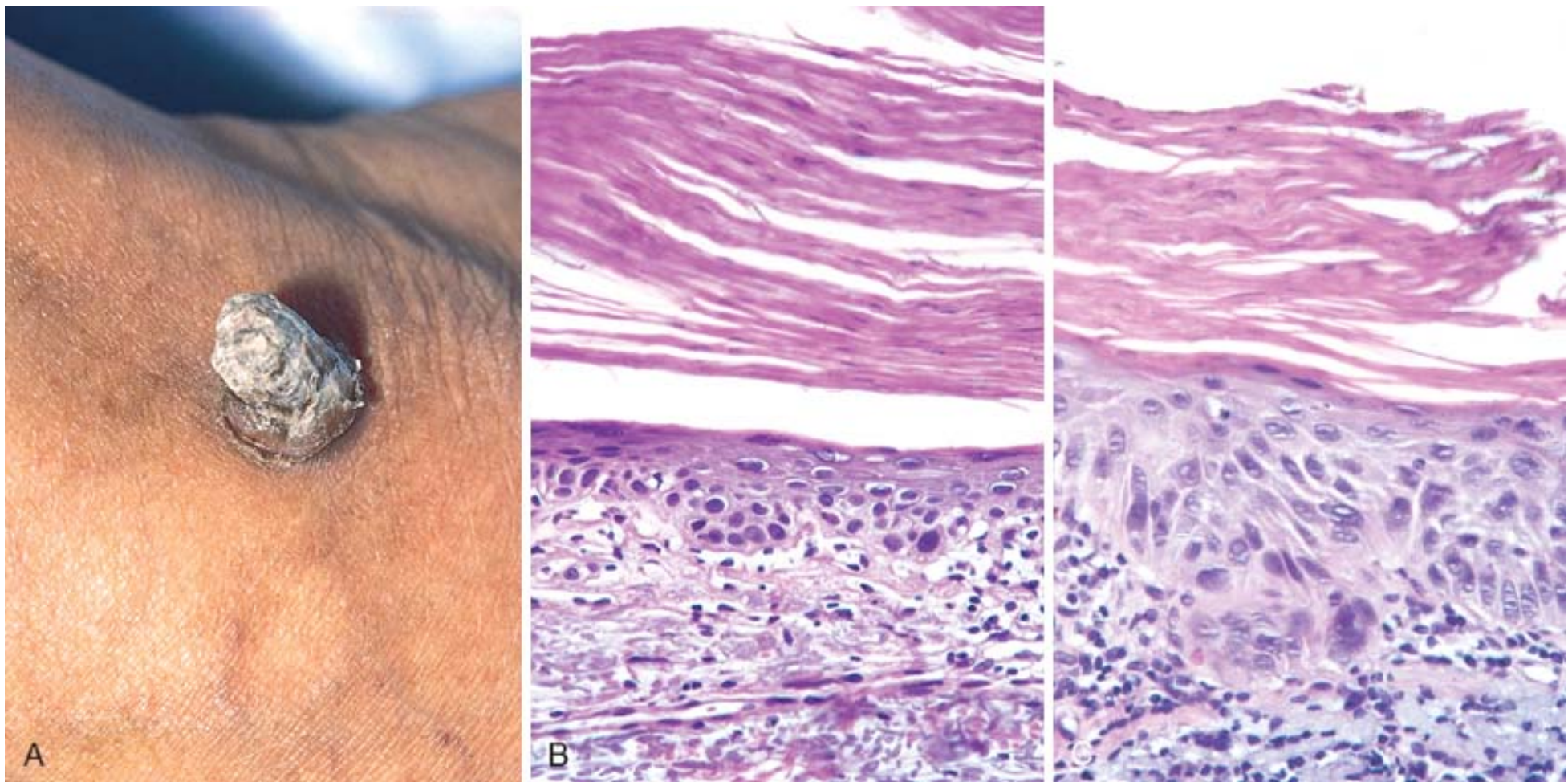
Actinic keratoses are usually less than 1 cm in diameter; are tan-brown, red, or skin-colored; and have a rough, sandpaper-like consistency. Some lesions may produce so much keratin that a "cutaneous horn" develops ( Fig. 25-13A ). Such horns may become so prominent that they actually resemble the

**Figure 25-12** Keratoacanthoma. *A*, This symmetric crater-like nodule has a prominent central keratin plug. *B*, At low power, the crater-like architecture may be appreciated with an elastic tissue stain where the dermis is red, epithelial elements are gray, and the central keratin plug is yellow. *C*, Higher power view shows keratoacanthoma to be composed of large, glassy squamous cells and central islands of eosinophilic keratin.



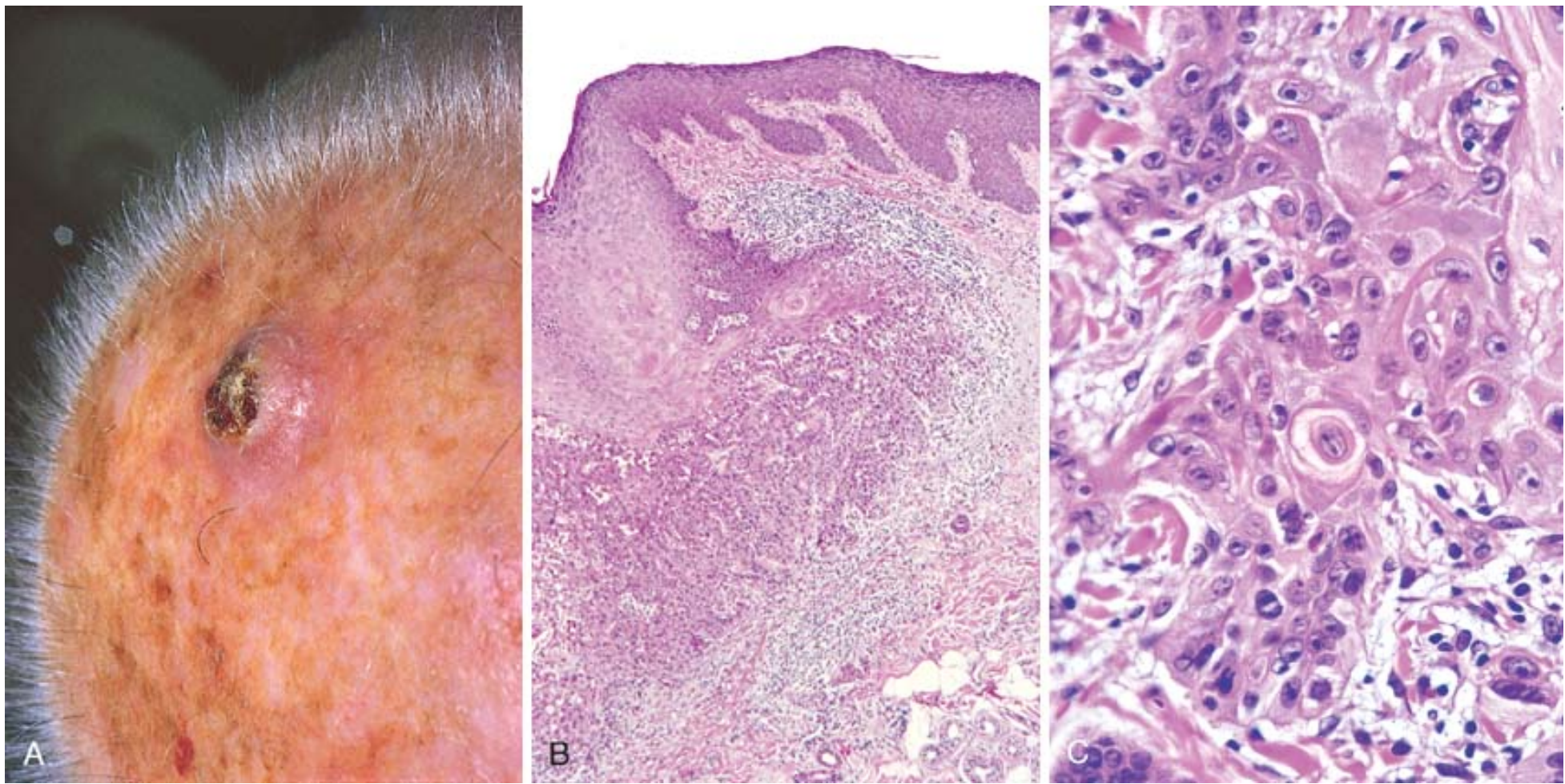
**Figure 25-13** Actinic keratosis. *A*, Excessive scale formation in this lesion has produced a "cutaneous horn." *B*, Basal cell layer atypia is associated with marked hyperkeratosis and parakeratosis. *C*, Progression to full-thickness nuclear atypia, with or without the presence of superficial epidermal maturation, heralds the development of early squamous cell carcinoma in situ.





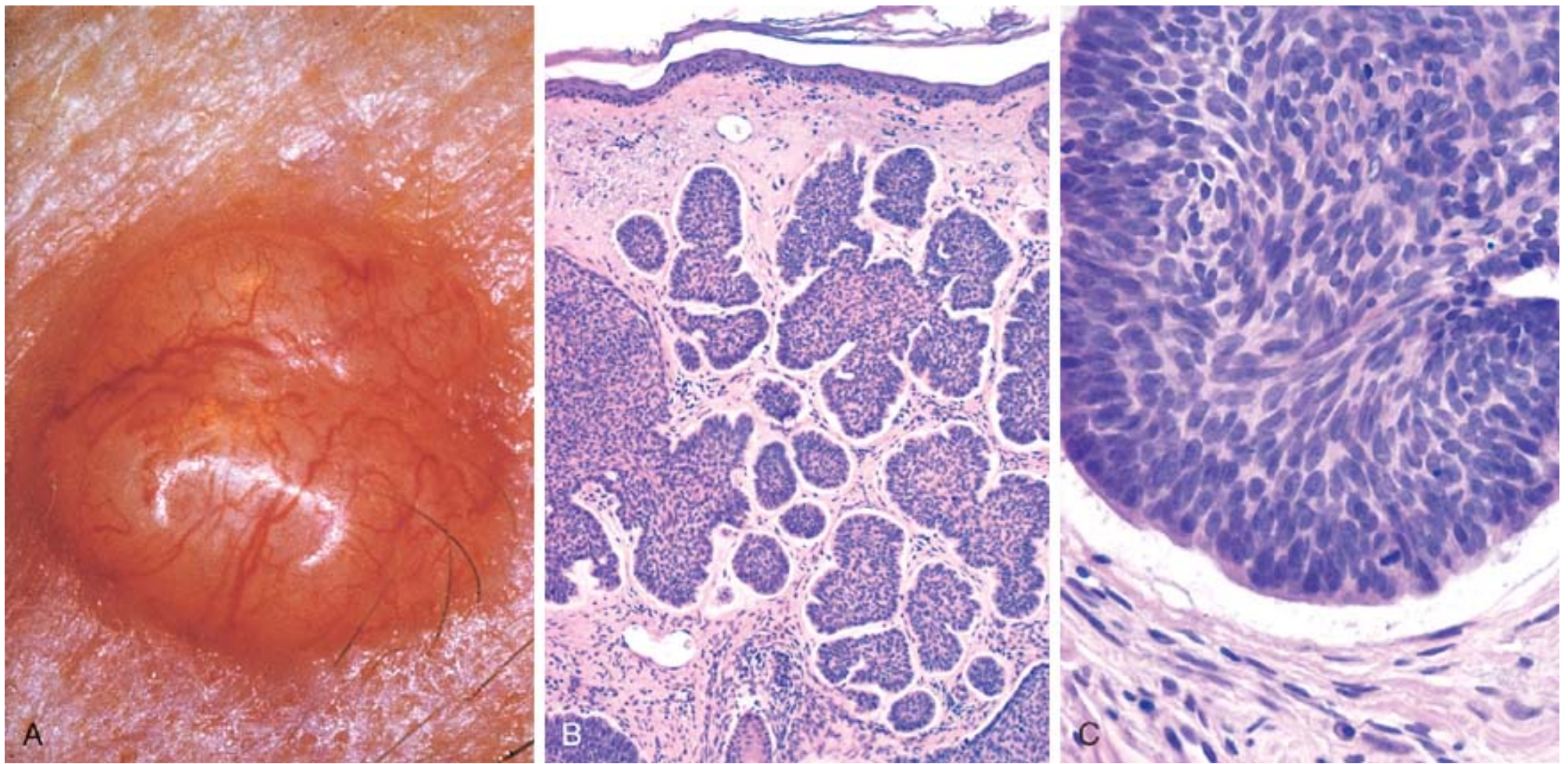
**Figure 25-14** Invasive squamous cell carcinoma. *A*, Lesions are often nodular and ulcerated. *B*, Tongues of atypical squamous epithelium have transgressed the basement membrane, invading deeply into the dermis. *C*, Invasive tumor cells exhibit enlarged nuclei with angulated contours and prominent nucleoli.





**Figure 25-15** Basal cell carcinoma. Pearly, telangiectatic nodules (*A*) are composed of nests of basaloid cells within the dermis (*B*) that are often separated from the adjacent stroma by thin clefts (*C*).





**TABLE 25-3** -- A Survey of Familial Cancer Syndromes with Cutaneous Manifestations<sup>[44]</sup>

Disease	Inheritance	Chromosomal Location	Gene/Protein	Function/Manifestation
Ataxia-telangiectasia	AR	11q22.3	<i>AT/AT</i> <sup>†</sup>	DNA repair after radiation injury; p53 signaling/neurologic and vascular lesions
Nevoid basal cell carcinoma syndrome	AD	9q22.3	<i>PTCH//PTCH</i>	Developmental gene/multiple basal cell carcinomas; jaw cysts, etc.
Cowden syndrome	AD	10q23	<i>PTEN, MMAC1/PTEN, TEP1, MMAC1</i>	Lipid/protein phosphatase/benign follicular appendage tumors (trichilemmomas); internal adenocarcinoma
Familial melanoma syndrome	AD	9p21	<i>CDKN2/p16INK4</i>	Inhibits CDKs from phosphorylating Rb, thus arresting cell cycle/melanoma

			<i>CDKN2</i> /p14ARF	Binds MDM2 and thus, preserves p53/melanoma
Muir-Torre syndrome	AD	2p22	<i>hMSH2</i> /hMSH2	Involved in DNA mismatch repair/benign and malignant sebaceous tumors; internal adenocarcinoma
Neurofibromatosis I	AD	17q11.2	<i>NF1</i> /neurofibromin	Negatively regulates Ras family of signal molecules/neurofibromas
Neurofibromatosis II	AD	22q12.2	<i>NF2</i> /merlin	Integrates cytoskeletal signaling/neurofibromas and acoustic neuromas
Tuberous sclerosis	AD	9q34	<i>TSC1</i> /hamartin	Interacts with tuberlin; function unknown
		16p13.3	<i>TSC2</i> /tuberin	Interacts with hamartin; may regulate ras proteins/angiofibromas, mental retardation
Xeroderma pigmentosum	AR	9q22 and others	<i>XPA</i> /XPA and others	Nucleotide excision repair/melanoma and nonmelanoma skin cancers

AD, Autosomal dominant; AR, autosomal recessive.

†By convention, genes are italicized and proteins are not italicized.

mutations are found in approximately 30% of sporadic basal cell carcinomas, and of these, about one-third have mutations (C to T transitions) that are considered to be the hallmark of UV damage. Mutations in *p53* occur in 40% to 60% of basal cell carcinomas, and 60% of these have such a "UV signature." [54] Xeroderma pigmentosum, a disorder of DNA repair, presents a striking example of the connection between sun exposure and defects in *PTCH* and *p53*. [55] In these tumors, the frequency of mutations in *PTCH* and *p53* are, respectively, 90% and 40%, and the majority of these bear the UV signature.

*In summary, mutations of PTCH are the cause of NBCCS. In sporadic basal cell carcinomas there are frequent mutations in PTCH and p53, most mutations being the product of unrepaired DNA damage by UV light.*

### Squamous Cell Carcinoma.

By contrast to basal cell carcinomas, there is no inherited single gene defect associated with squamous cell carcinomas. Thus, most studies of the molecular genetics of squamous cell carcinoma have examined defects in sporadic tumors and their precursors (actinic keratoses), and the relationships between these defects and sun exposure. [56] The incidence of mutations in *p53* in Caucasian patients with actinic keratoses is high, suggesting that sunlight causes alterations at the early stages of carcinogenesis. [57] However it is not known whether lesions with *p53* mutations are more likely to progress to carcinomas than lesions without the mutation. The immediate effects of UV light on *p53* are positive, involving its induction, resulting in cell-cycle arrest in G<sub>1</sub> to permit DNA repair, or elimination by apoptosis of the damaged cells that are beyond repair (see Chapter 7 ). When this protective function of *p53* is lost because of unrepaired UV-induced damage of the gene through production of pyrimidine dimers, [58] continuous division of the mutant cells is favored. Such mutations are found in some but not all invasive squamous cell carcinomas. Unlike basal cell carcinomas, aneuploidy is very common in squamous cell carcinomas, and loss of heterozygosity involving chromosomes 3, 9, and 17 occurs in approximately 30% of cases. With the exception of the *p53* locus on chromosome 17, putative tumor suppressor genes localized in the other chromosomes have not been identified.

HPV types 5 and 8, among others (see Chapter 7 ), are involved in the molecular pathogenesis of a rare condition, epidermodysplasia verruciformis, associated with formation of numerous cutaneous squamous cell carcinomas. A decreased immune response also seems to play a role, since this condition may be found in severely immunosuppressed individuals. [59]

## Melanomas.

It is estimated that 10% to 15% of melanomas arise in a familial setting.<sup>[60]</sup> This was first observed in families whose members have large numbers of dysplastic nevi. As already mentioned, some dysplastic nevi develop into melanoma, as in the familial BK mole syndrome, also known

---

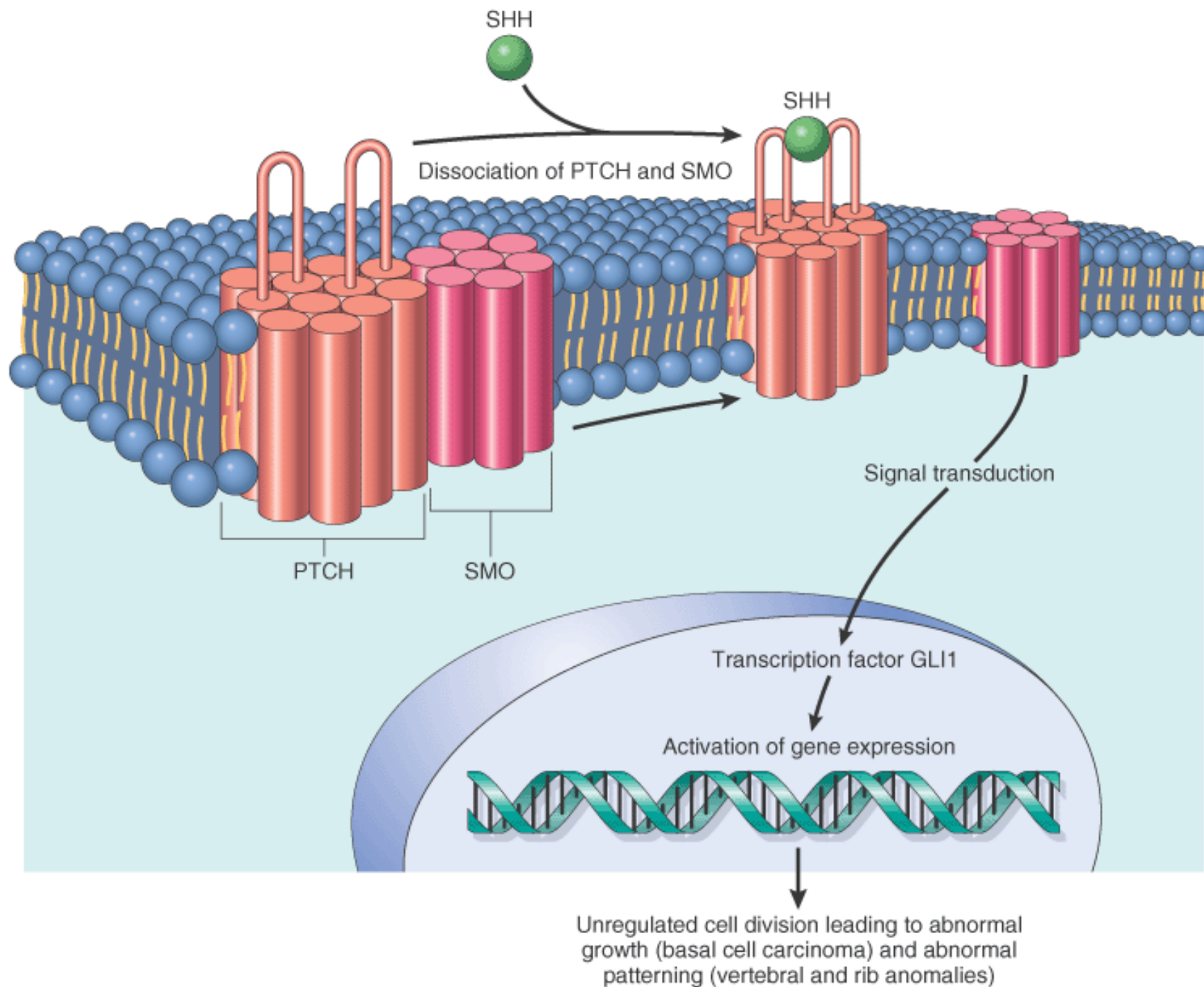
1246

as *dysplastic nevus syndrome*, *familial atypical multiple mole-melanoma syndrome*, or simply *familial melanoma syndrome* (FMS). Unlike NBCCS, which has a clear Mendelian mode of inheritance, FMS does not display distinct and predictable inherited phenotypic abnormalities.<sup>[44]</sup> The situation is even more complex because not all familial melanomas develop in the setting of multiple dysplastic nevi; conversely, melanomas can occur in patients with multiple sporadic dysplastic nevi. To complicate matters, there is no complete agreement about the histopathologic criteria for the diagnosis of dysplastic nevi. <sup>[61]</sup> <sup>[62]</sup> <sup>[63]</sup>

The main locus associated with familial predisposition to melanomas has been mapped to chromosome 9p21<sup>[64]</sup> and it encodes *p16INK4A* (also known as cyclin-dependent kinase inhibitor 2, or *CDNK2*). It is frequently deleted in melanomas. <sup>[65]</sup> <sup>[66]</sup> As you may recall from the discussions of the cell cycle, lack of functional p16INK4A leads to unrestricted phosphorylation of RB, release of E2F, and uncontrolled cell growth. *p16INK4A* is the most commonly mutated gene in

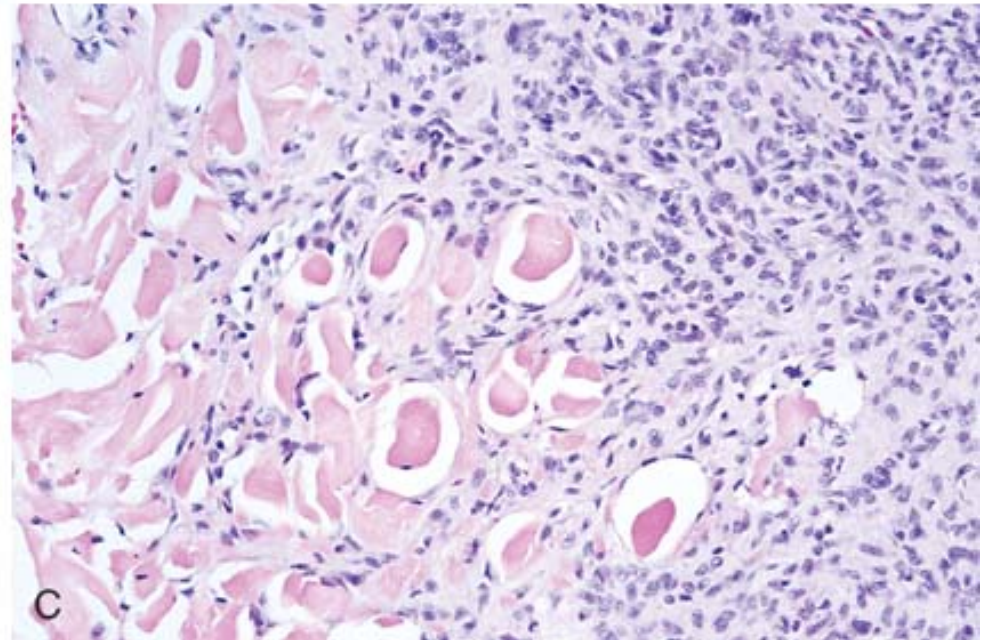
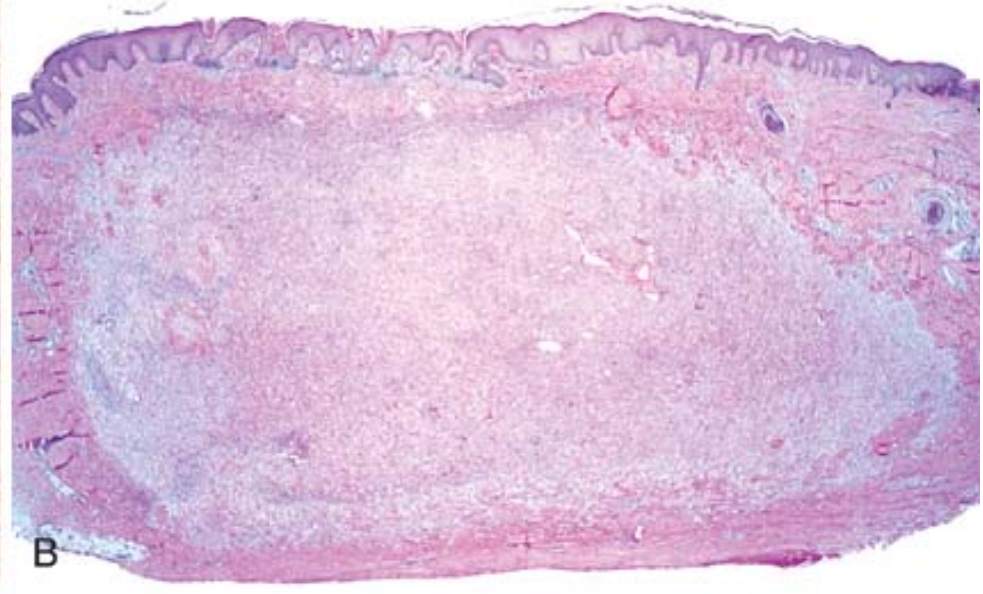
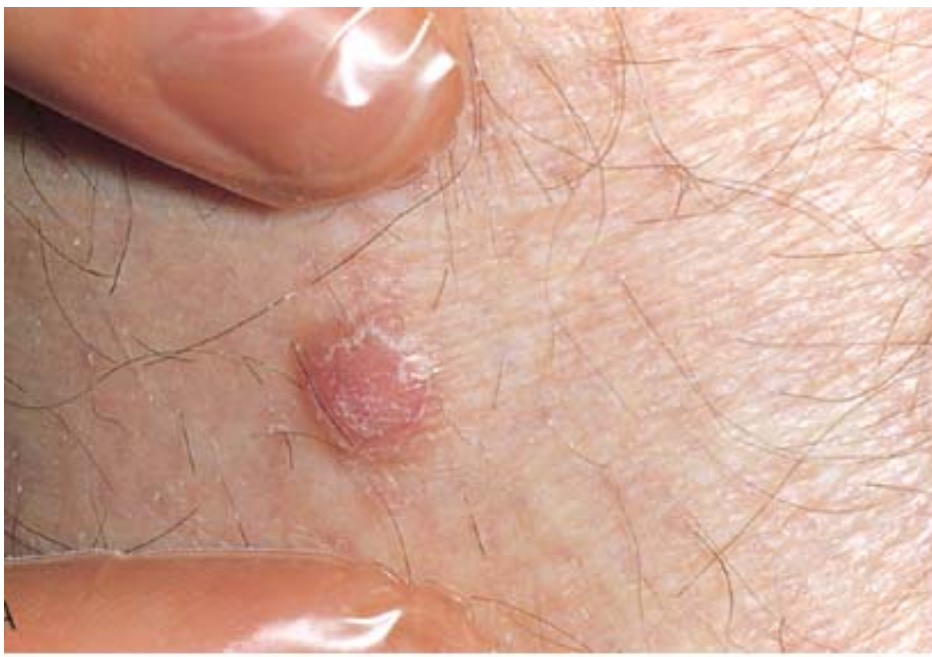**Figure 25-16** Model of the hedgehog signaling pathway. PTCH and SMD form a receptor complex that binds Sonic Hedge Hog (SHH). In the absence of SHH, the PTCH protein prevents SMO from activating signal transduction. Binding of the SHH to the two large extracellular domains of PTCH releases SMO from its association with PTCH and allows downstream activation of hedgehog target genes via an intracytoplasmic signal cascade and generation of transcription factors, the most notable one being GLI1. Unopposed gene expression leads to basal cell carcinoma and development of anomalies seen in the nevoid basal cell carcinoma syndrome (NBCCS). Perturbations of this pathway are also important in sporadic forms of basal cell carcinoma.





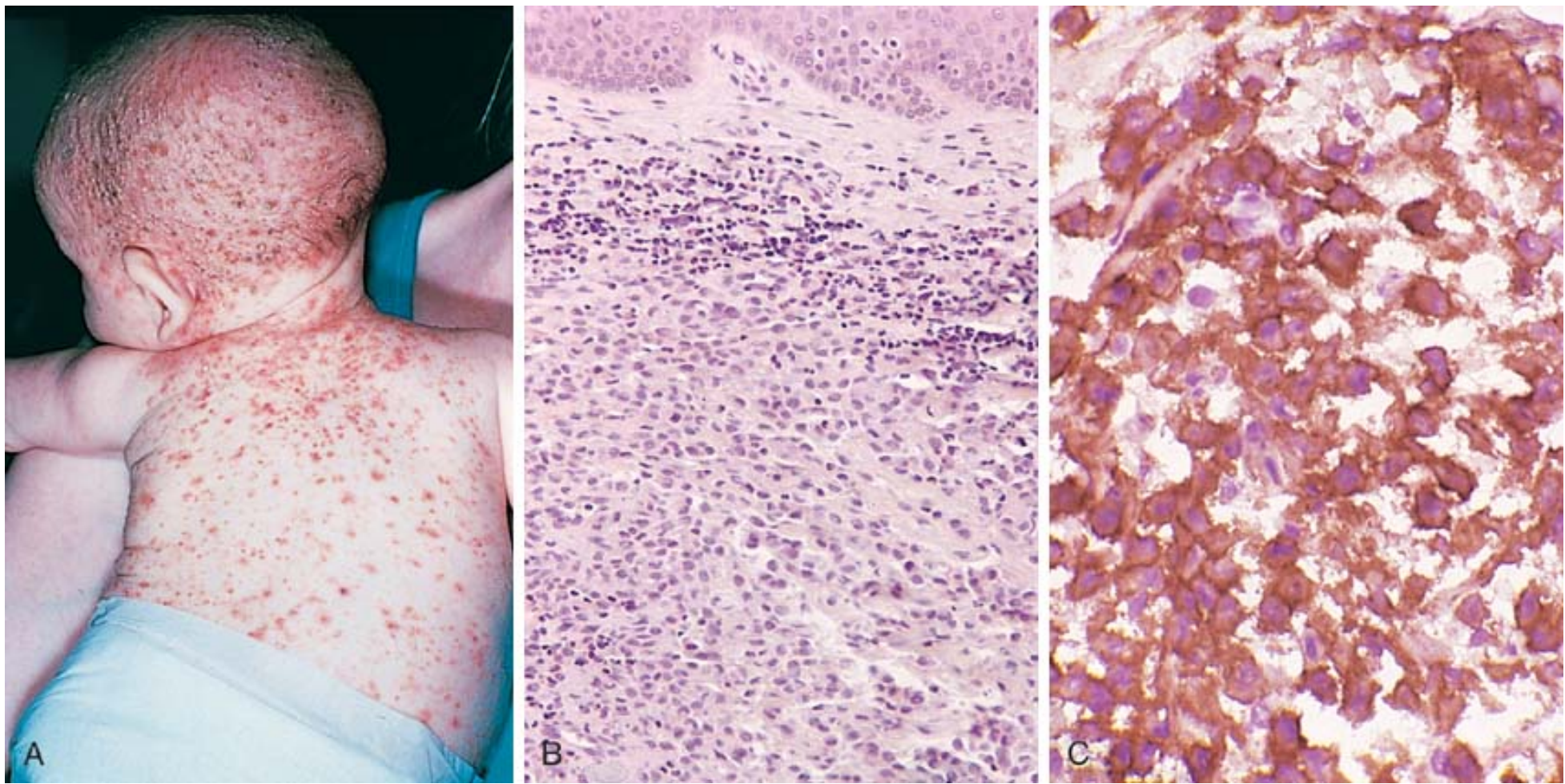
**Figure 25-17** A, Benign fibrous histiocyteoma (dermatofibroma). B, C, On excision, this firm, tan papule on the leg shows a localized nodular proliferation of benign-appearing fibroblasts within the dermis. Note the characteristic overlying epidermal hyperplasia and the tendency of fibroblasts to surround individual collagen bundles.





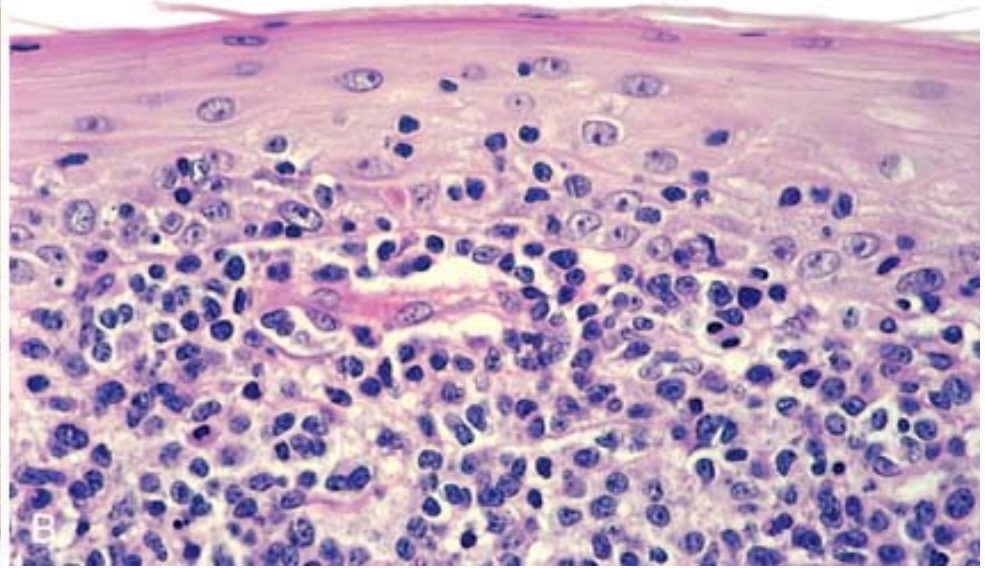
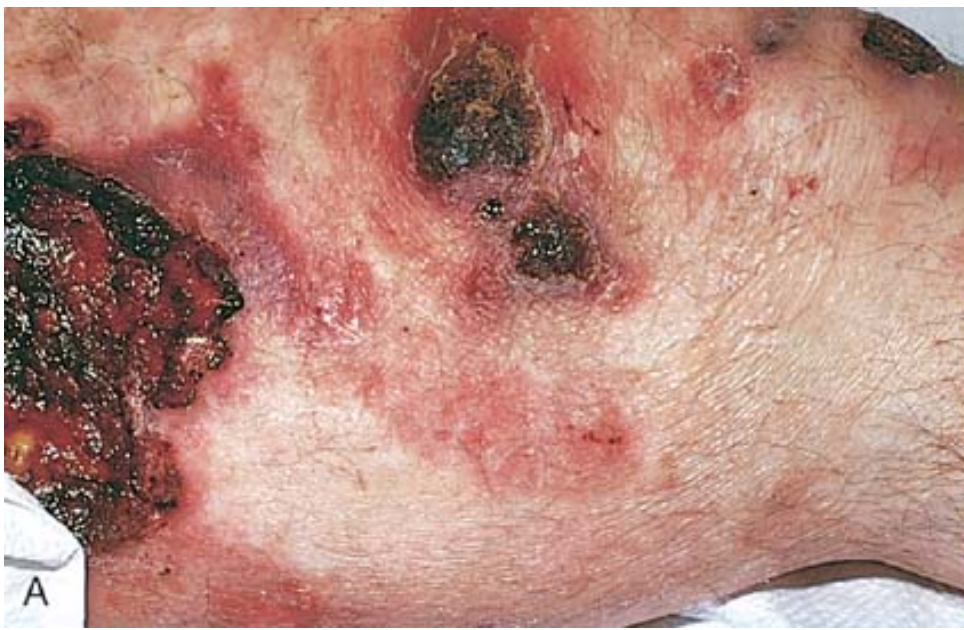**Figure 25-18** Langerhans cell histiocytosis. *A*, Lesions may appear clinically as papules and nodules or, as in this case, as erythematous scaling plaques mimicking the infantile form of seborrheic dermatitis. *B*, Dermal infiltration by bland mononuclear cells with infolded nuclei presents a nonspecific histologic pattern. *C*, Immunohistochemical demonstration of CD1a antigen confirms the origin of these mononuclear cells from Langerhans cells.





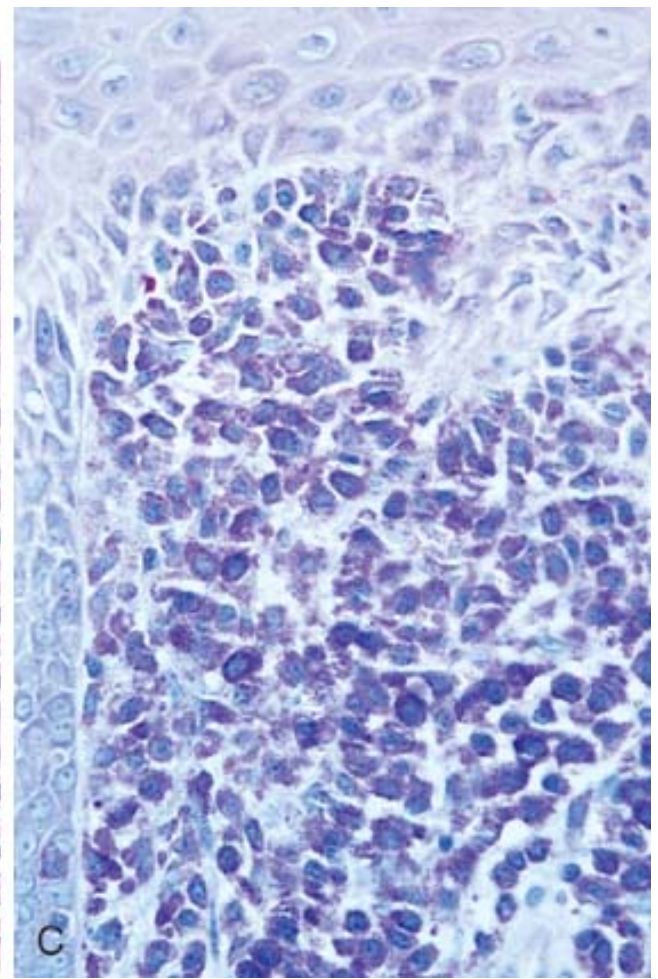
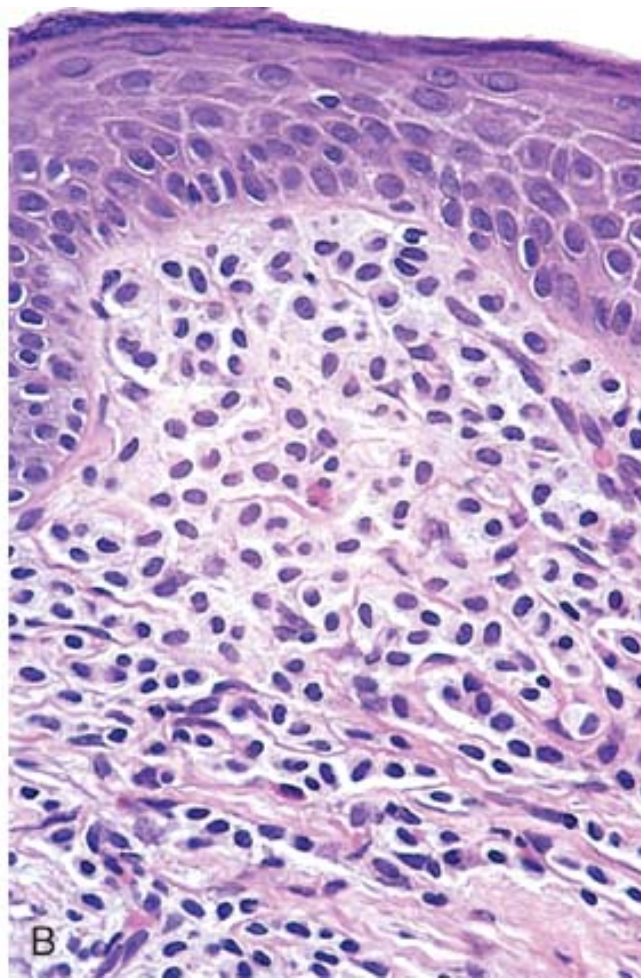
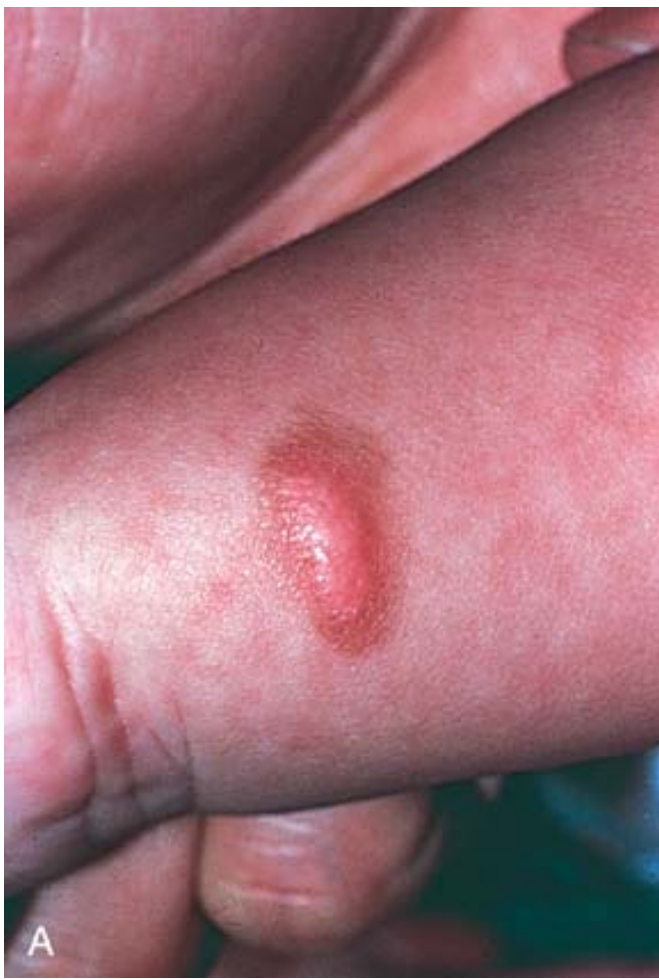**Figure 25-19** Cutaneous T-cell lymphoma. The histologic correlate of ill-defined, erythematous, often scaling, and occasionally ulcerated plaques (*A*) is an infiltrate of atypical lymphocytes that show a tendency to accumulate beneath the epidermal layer (*B*) and to invade the epidermis as small microabscesses.





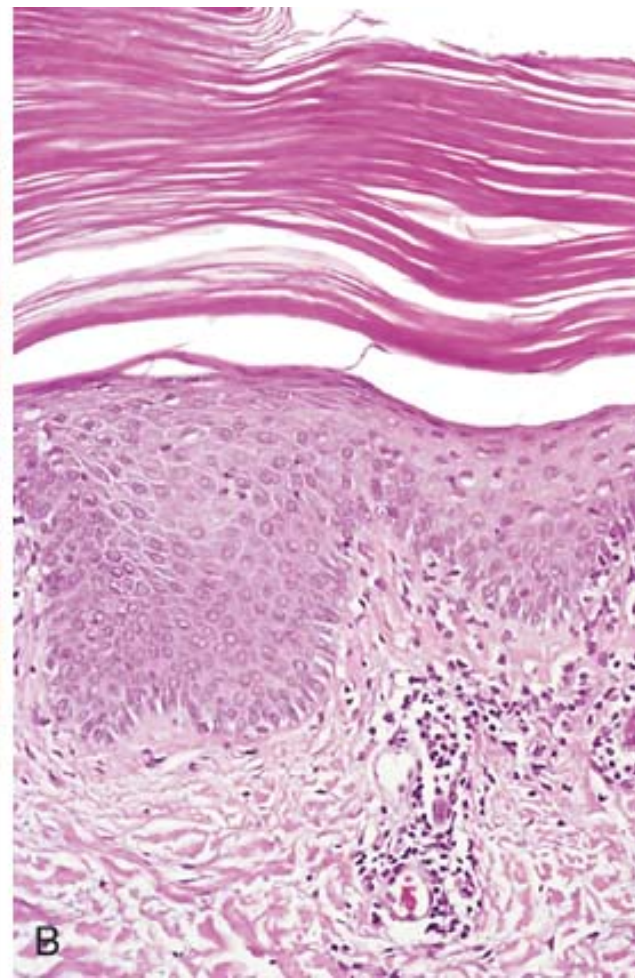
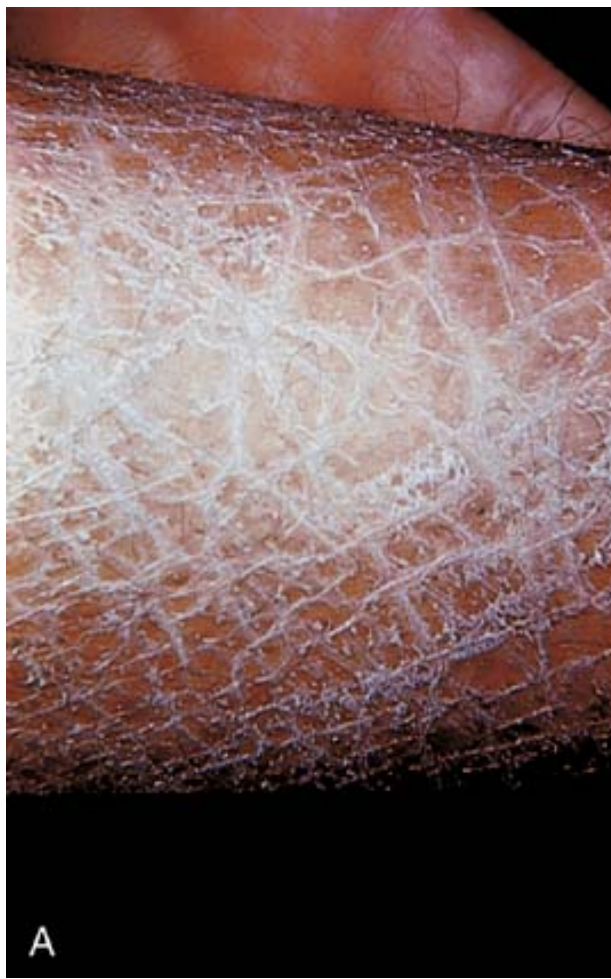**Figure 25-20** Mastocytosis. *A*, Solitary mastocytoma in a 1-year-old child. *B*, By routine histology, numerous ovoid cells with uniform, centrally located nuclei are observed in the dermis. *C*, Giemsa staining reveals purple, "metachromatic" granules within the cytoplasm of the cells.



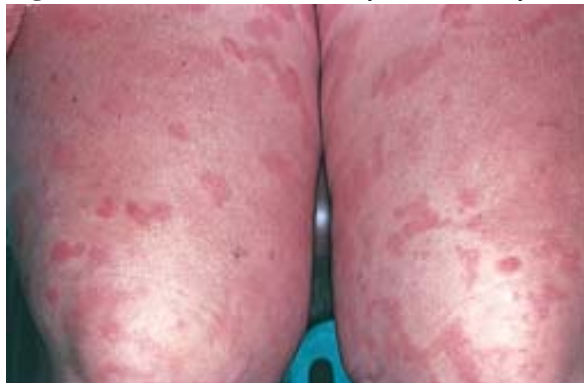

**Figure 25-21** Ichthyosis. Note prominent fishlike scales (*A*) and compacted stratum corneum (*B*).

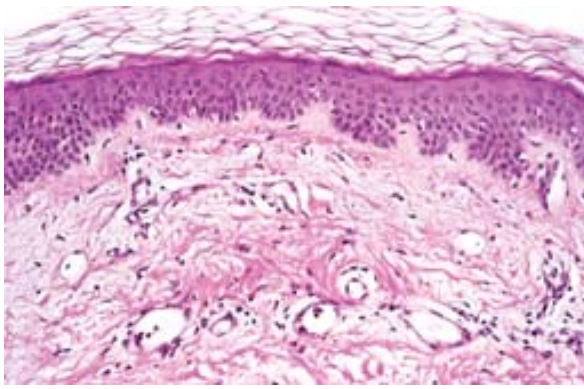




**Figure 25-22** Urticaria. Clinically, there are erythematous, edematous, often circular plaques covered by a normal epidermal surface.

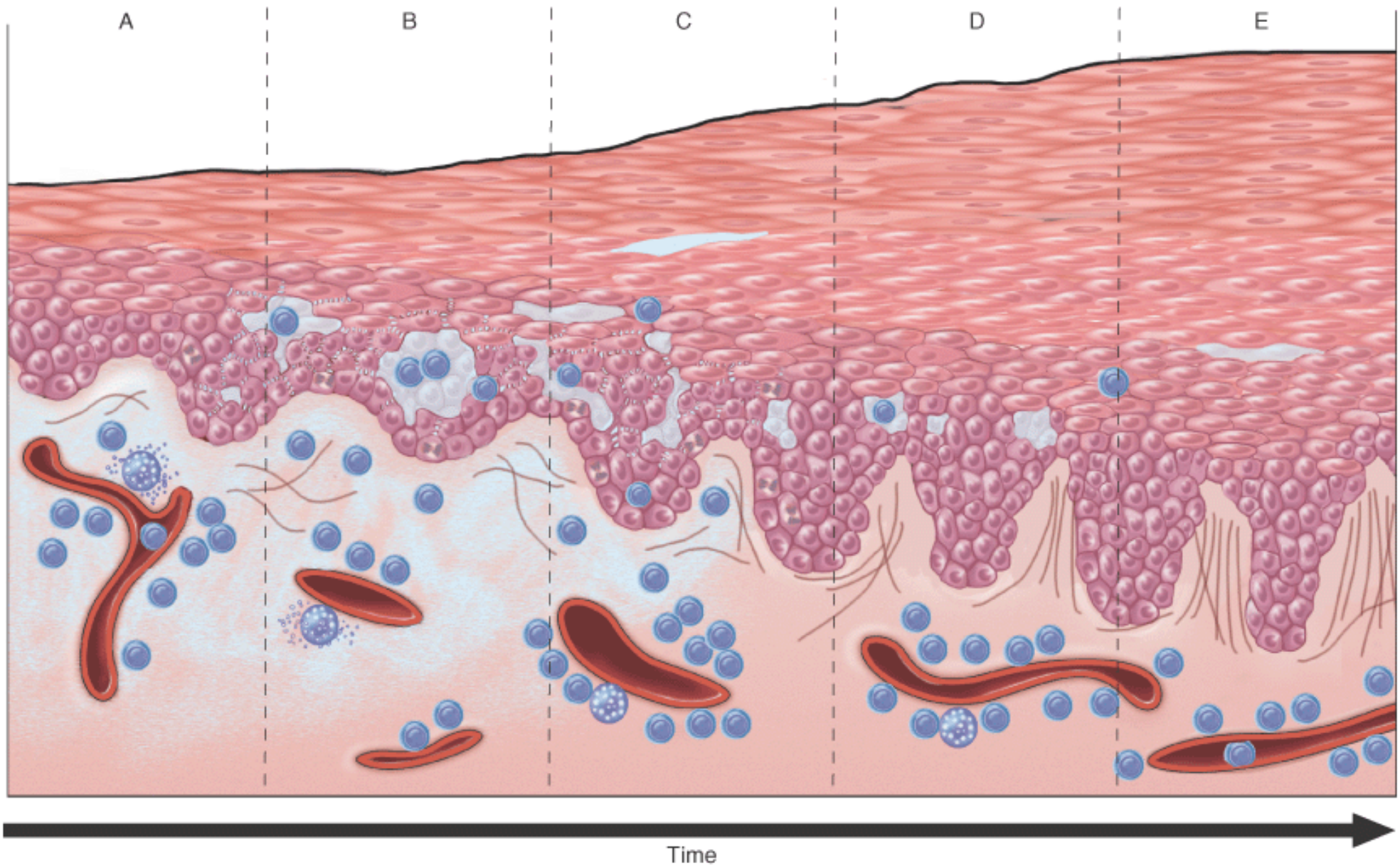


**Figure 25-23** Urticaria. Histologically, there is superficial dermal edema and dilated lymphatic and blood-filled vascular spaces. The edema is manifested by widening of spaces that separate the collagen bundles.



**Figure 25-24** Stages of eczema development. *A*, Initial dermal edema and perivascular infiltration by inflammatory cells is followed within 24 to 48 hours by epidermal spongiosis and microvesicle formation (*B*). *C*, Abnormal scale, including parakeratosis, follows, along with progressive epidermal hyperplasia (*D*) and hyperkeratosis (*E*) as the lesion enters into a more chronic stage.





**TABLE 25-4** -- Classification of Eczematous Dermatitis

Type	Cause or Pathogenesis	Histology *	Clinical Features
Contact dermatitis	Topically applied antigens	Spongiotic dermatitis	Marked itching, burning, or both; requires antecedent exposure

Atopic dermatitis	Unknown; may be heritable	Spongiotic dermatitis	Erythematous plaques in flexural areas; family history of eczema, hay fever, or asthma
Drug-related eczematous dermatitis	Systemically administered antigens or haptens (e.g. penicillin)	Spongiotic dermatitis; infiltrate often deeper with abundant eosinophils	Temporal relationship to drug administration; remits with cessation of drug
Eczematous insect bite reaction	Locally injected antigen or toxin	Spongiotic dermatitis; wedge-shaped infiltrate; many eosinophils	Papules, nodules, and plaques with vesicles; may be linear when multiple
Photoeczematous eruption	Ultraviolet light	Spongiotic dermatitis; infiltrate that diminishes gradually with depth	Occurs at sites of sun exposure; may require associated exposure to systemic or topical antigen; photopatch testing may help in diagnosis
Primary irritant dermatitis	Repeated trauma or chemical irritants (as in detergent)	Spongiotic dermatitis in early stages; acanthosis predominates in later stages	Localized mechanical or chemical irritants (nonimmunologic)

\*All types, with time, may develop chronic changes, with prominent acanthosis of the epidermal layer.

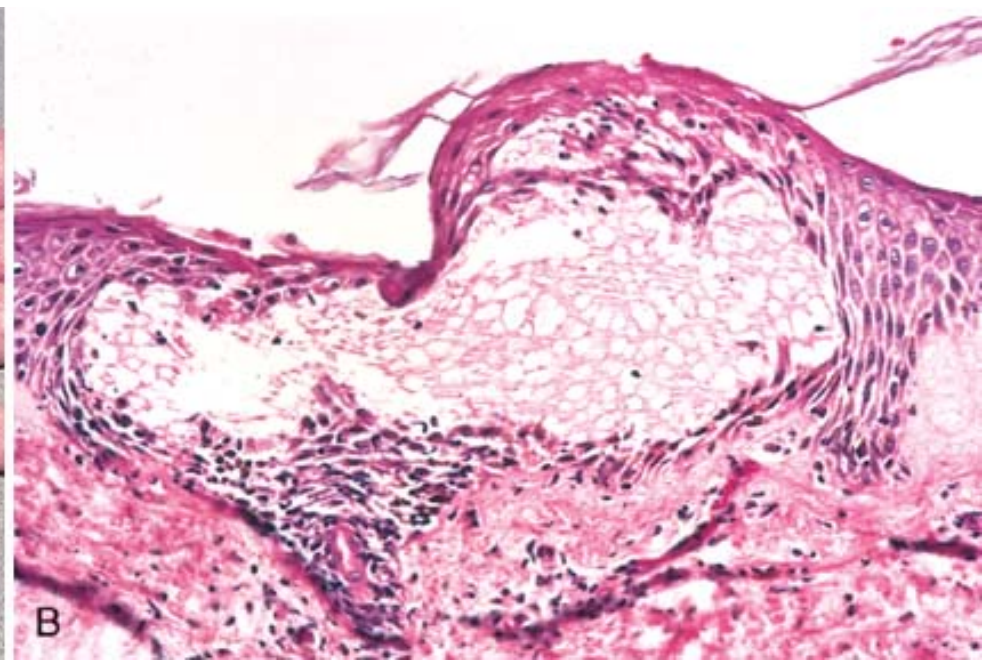
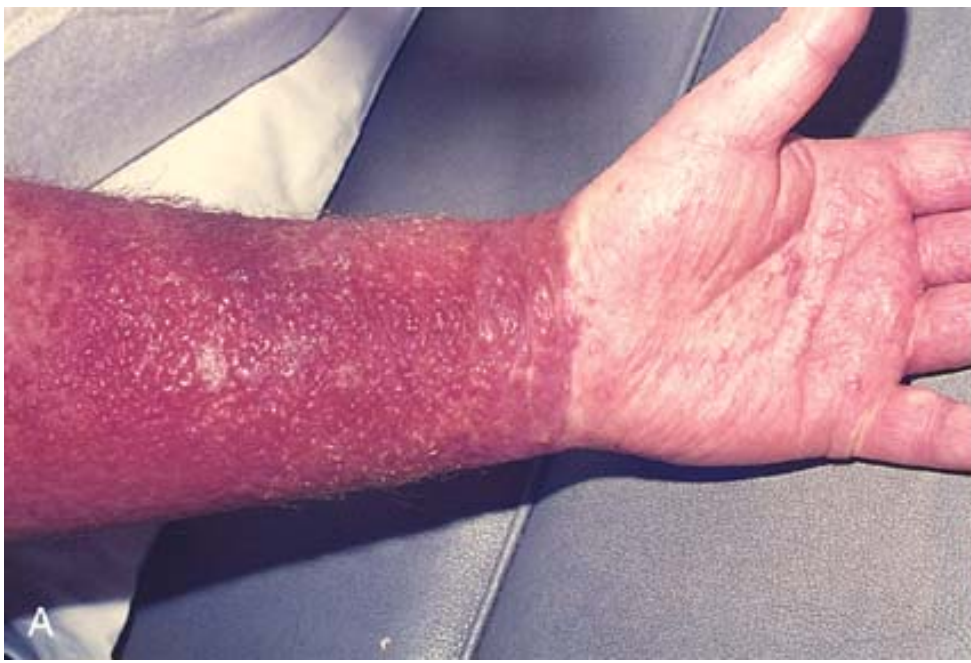The most obvious example is an acute contact reaction to topical antigens such as poison ivy, characterized by pruritic, edematous, oozing plaques, often containing small and large blisters (vesicles and bullae) ( Fig. 25-25A ). Such lesions are prone to bacterial superinfection, which produces a yellow crust (impetiginization). With time, persistent lesions become less "wet" (fail to ooze or form vesicles) and become progressively scaly (hyperkeratotic) as the epidermis thickens (acanthosis).

#### Pathogenesis.

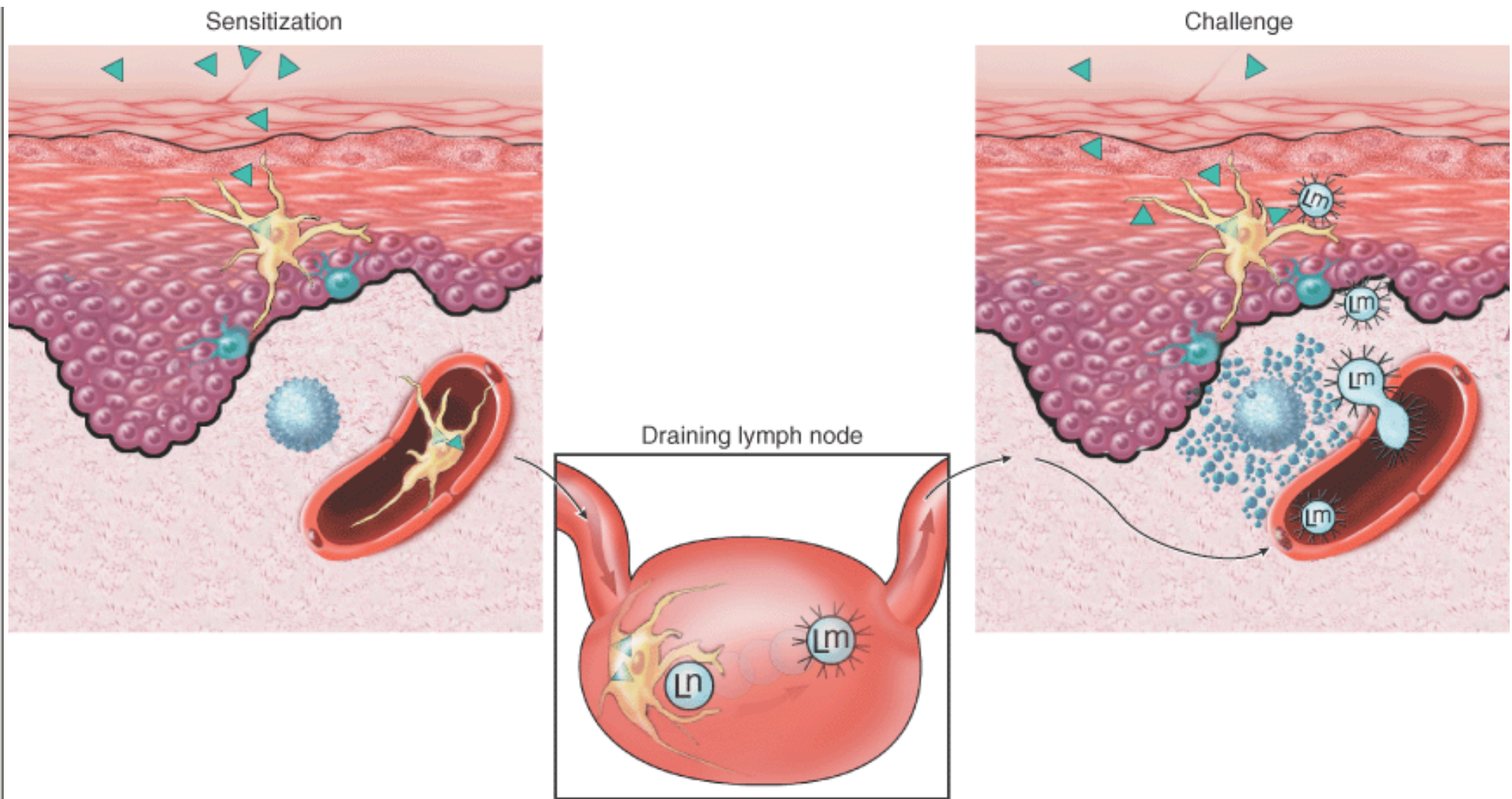
This has been well studied in dermatitis due to contact hypersensitivity (e.g., poison ivy dermatitis). Initially, antigens at the epidermal surface are taken up by dendritic Langerhans cells, which then migrate by way of dermal lymphatics to draining lymph nodes ( Fig. 25-26 ). Here, antigens, now processed by the Langerhans cell, are presented to naive CD4 T cells, which are activated and develop into effector and memory cells ( Chapter 6 ). On antigen re-exposure,

**Figure 25-25** Eczematous dermatitis. *A*, In an acute allergic contact dermatitis, numerous vesicles appear at the site of antigen exposure (in this case, laundry detergent that persisted in clothing). *B*, Histologically, intercellular edema produces widened intercellular spaces within the epidermis, eventually resulting in small, fluid-filled intraepidermal vesicles.



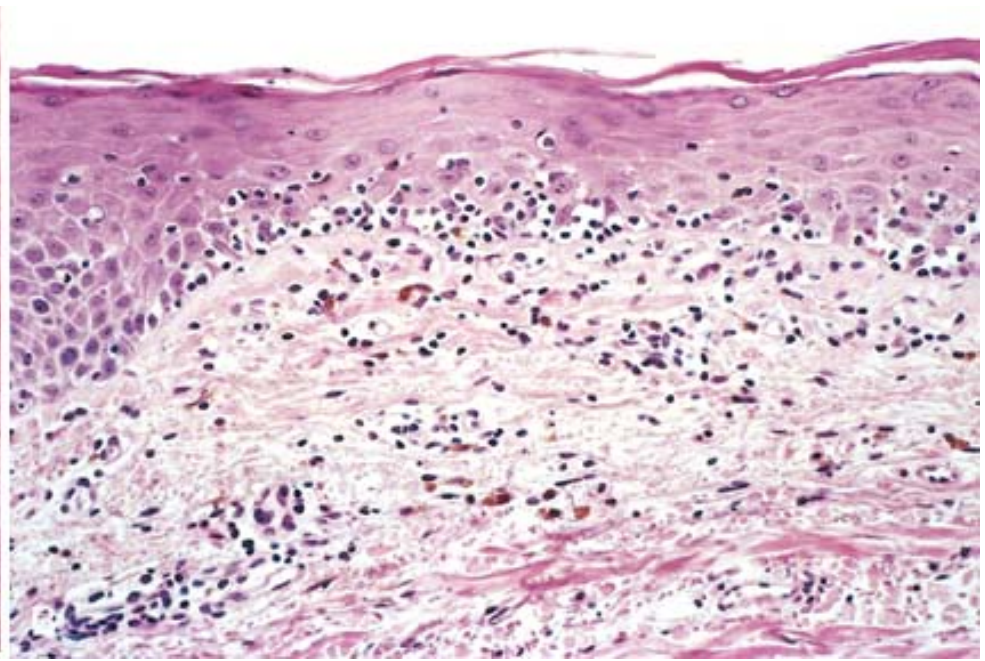
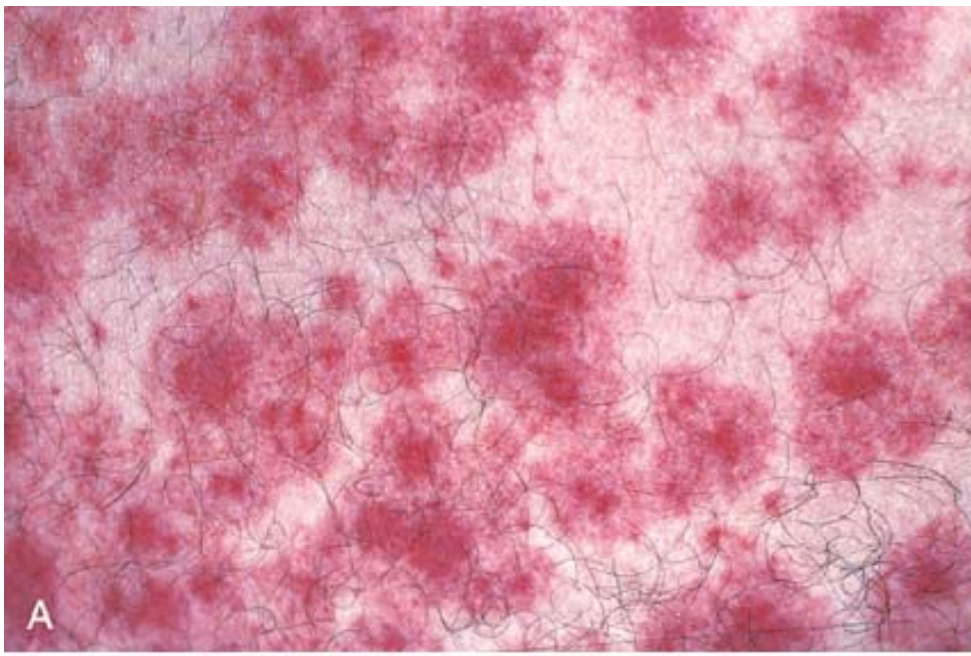


**Figure 25-26** Schematic diagram of mechanisms of allergic contact dermatitis.  $\Delta$ , antigen; Ln, naive T lymphocyte; Lm, memory T lymphocyte.

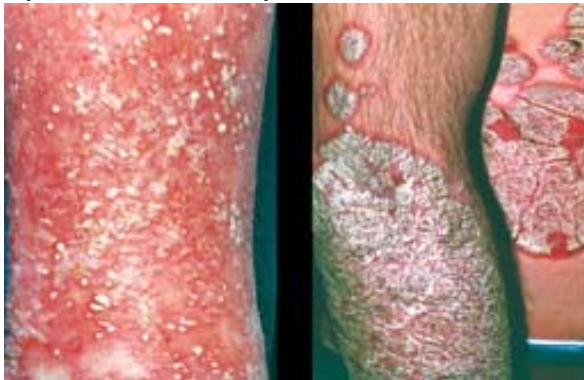

**Figure 25-27** Erythema multiforme. *A*, The target-like clinical lesions consist of a central blister or zone of epidermal necrosis surrounded by macular erythema. *B*, Early lesions show lymphocytes collecting along the dermal epidermal junction where basal keratinocytes have begun to become vacuolated.

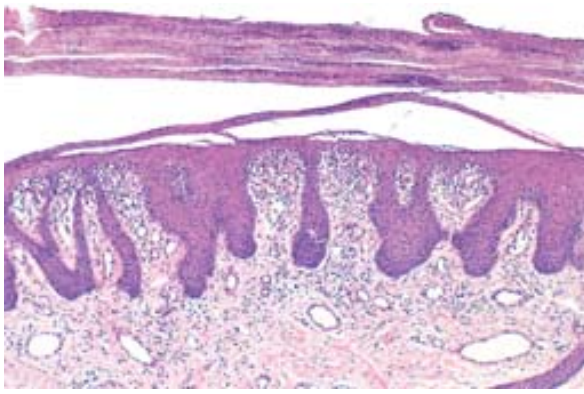




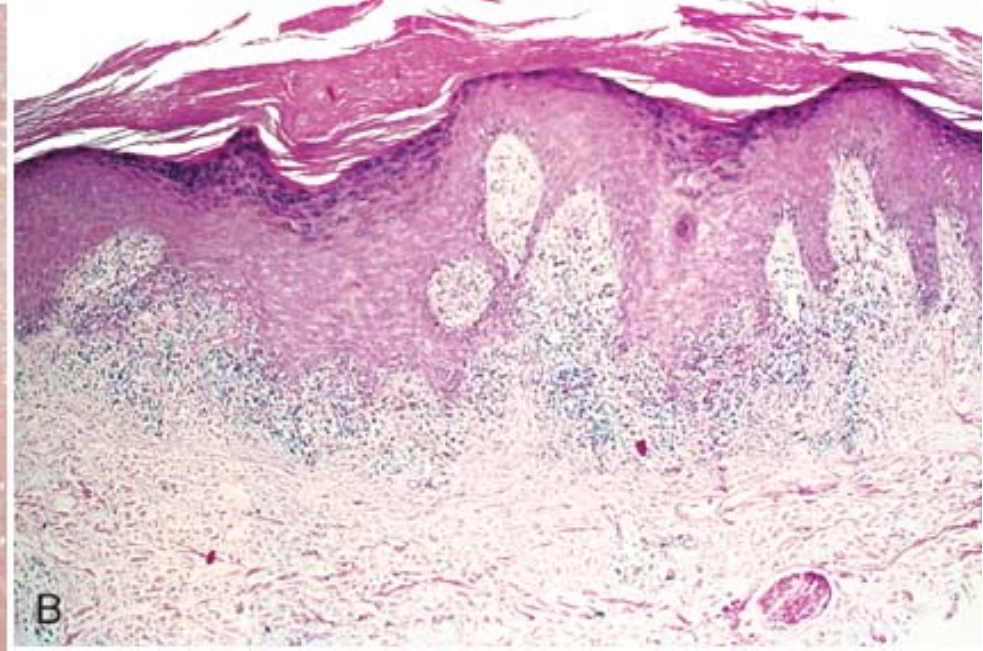
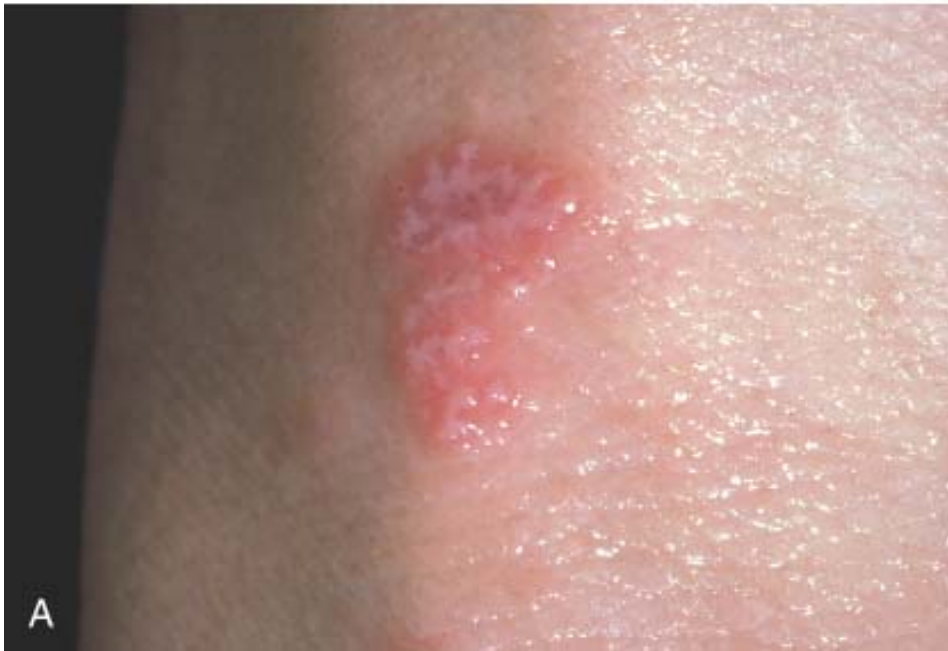**Figure 25-28** Clinical evolution of psoriasis. Early and eruptive lesions may be dominated by signs of inflammation and erythema (*left*). Established, chronic lesions demonstrate erythema surmounted by characteristic silver-white scale (*right*). Rarely, the early inflammatory phase predominates throughout the course of the disease (pustular psoriasis).



**Figure 25-29** Psoriasis. Histologically, established lesions demonstrate marked epidermal hyperplasia, parakeratotic scale, and, importantly, minute microabscesses of neutrophils within the superficial epidermal layers.

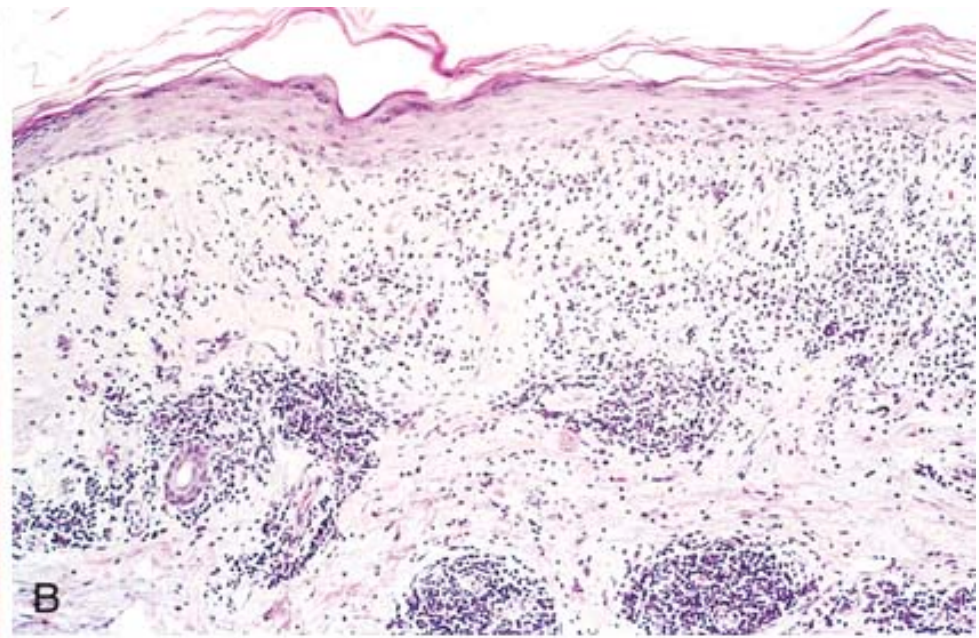
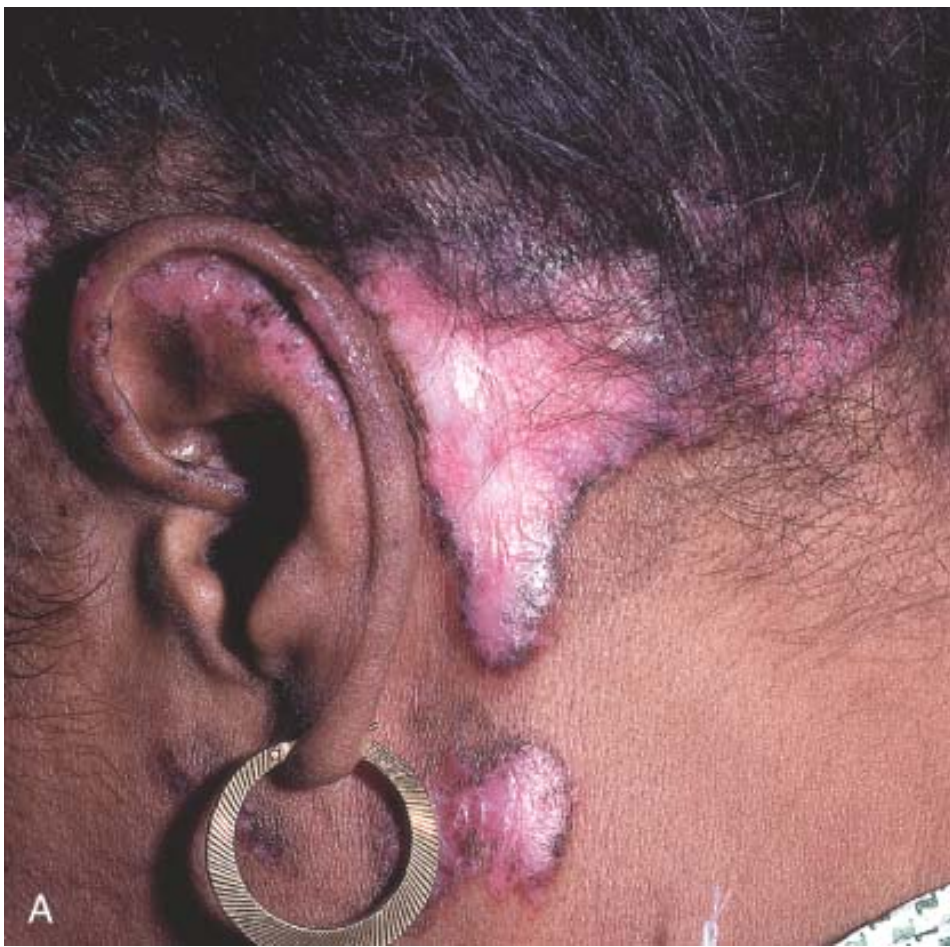

**Figure 25-30** Lichen planus. *A*, A solitary lesion of lichen planus (glistening surface is due to application of mineral oil, rendering the scale transparent). This flat-topped pink-purple, polygonal papule shows prominent Wickham striae that are more easily appreciated through the transparent scale. *B*, Biopsy of one of the lesions demonstrates the bandlike infiltrate of lymphocytes at the dermoepidermal junction and pointed rete ridges (saw-toothing; compare with Fig. 25-1 ).

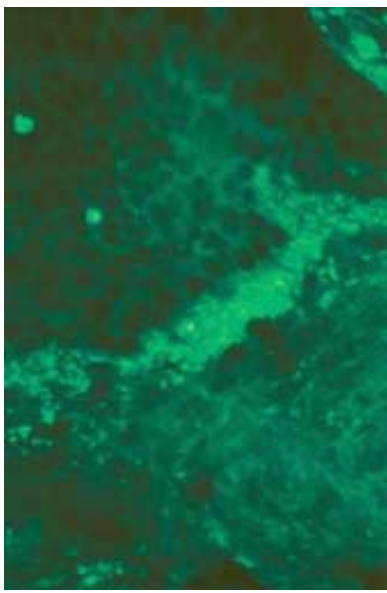


**Figure 25-31** Lupus erythematosus. *A*, These chronic plaques show a thinned and glistening (atrophic) epidermis, areas where dilated and tortuous dermal vessels are apparent, and central hypopigmentation surrounded by peripheral hyperpigmentation. Note areas of early hair loss due to follicular involvement. *B*, There is an infiltrate of lymphocytes within the superficial and deep dermis, marked thinning of the epidermis with loss of normal rete ridges, and hyperkeratosis.

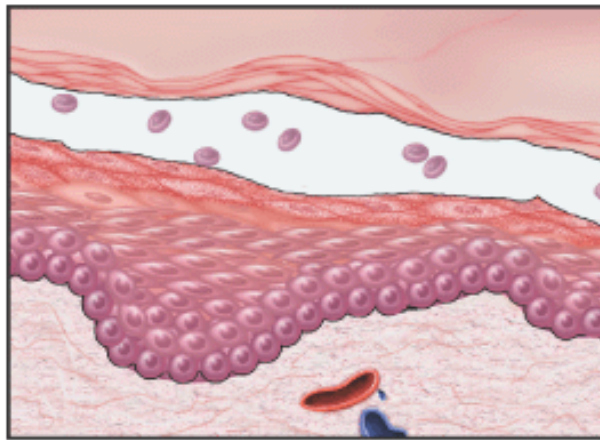




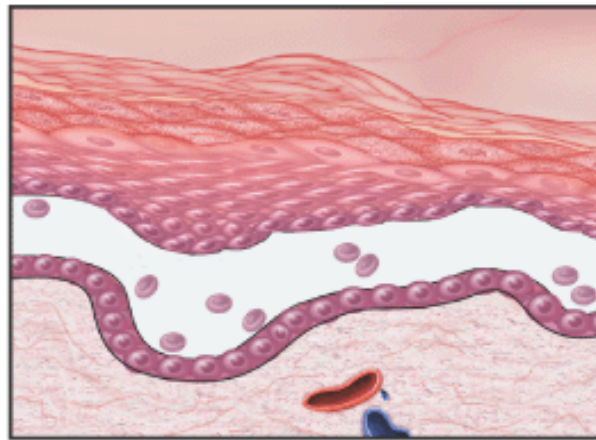
**Figure 25-32** Granular deposits of immunoglobulin (here IgG) and complement at the dermoepidermal junction constitute a positive "band test" in lupus erythematosus.



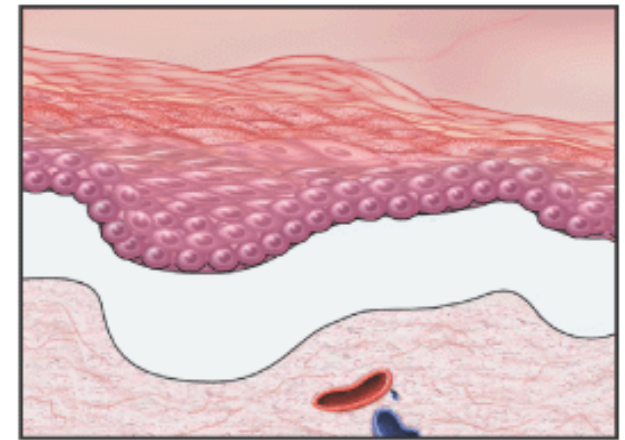
**Figure 25-33** Schematic representation of sites of blister formation. *A*, In a subcorneal blister, the stratum corneum forms the roof of the bulla (as in impetigo or pemphigus foliaceus). *B*, In a suprabasal blister, a portion of the epidermis including the stratum corneum forms the roof (as in pemphigus vulgaris). *C*, In a subepidermal blister, the entire epidermis separates from the dermis (as in bullous pemphigoid and dermatitis herpetiformis).



**A** Subcorneal



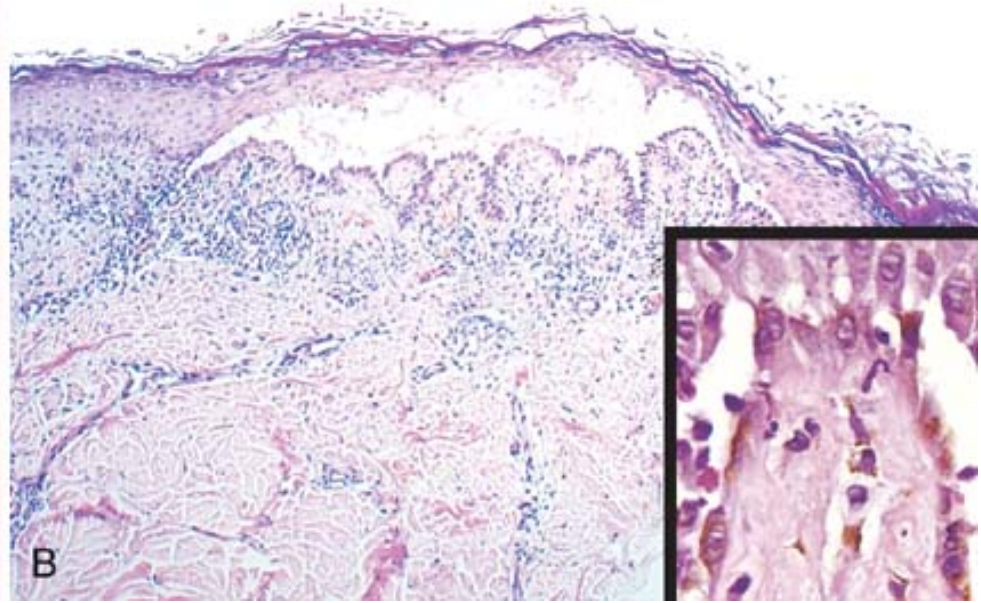
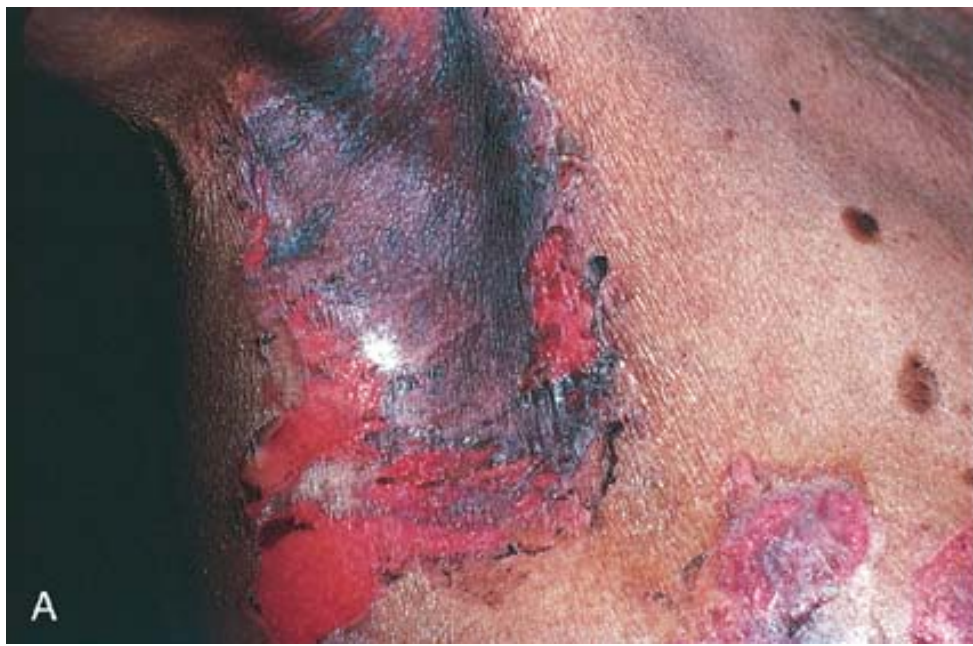**B** Suprabasal



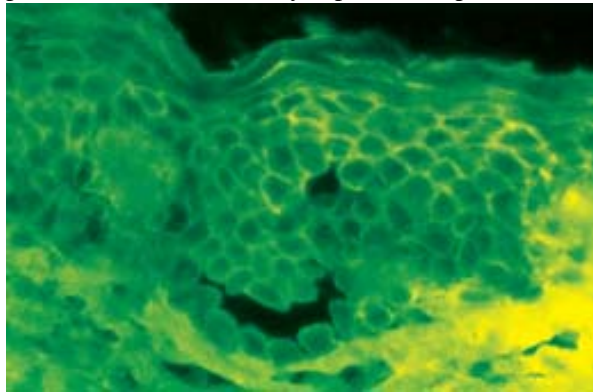
**C** Subepidermal

**Figure 25-34** Pemphigus vulgaris. *A*, Eroded plaques are formed on rupture of confluent, thin-roofed bullae, here affecting axillary skin. *B*, Suprabasal acantholysis results in an intraepidermal blister in which rounded (acantholytic) epidermal cells are identified (*inset*).



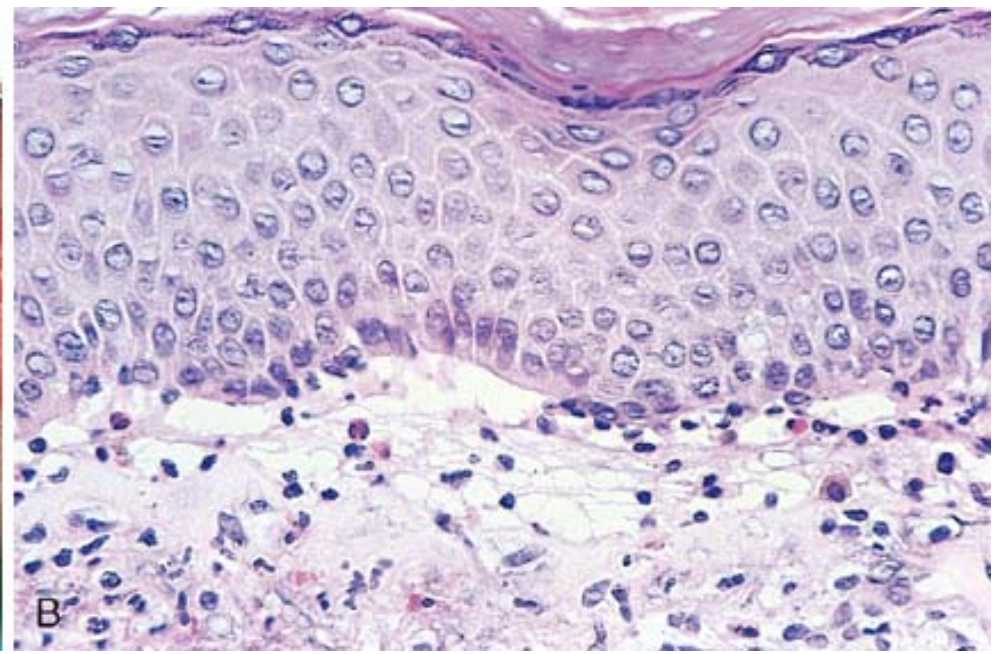
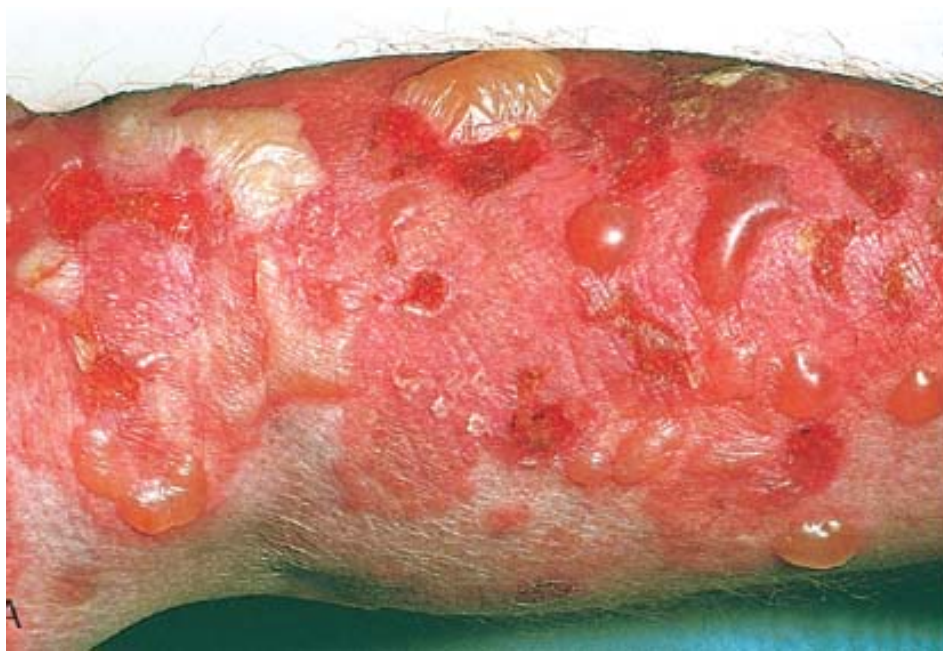

**Figure 25-35** Direct immunofluorescence of pemphigus vulgaris. There is deposition of immunoglobulin along the plasma membranes of epidermal keratinocytes in a fishnet-like pattern. Also note the early suprabasal separation due to loss of cell-to-cell adhesion (acantholysis).

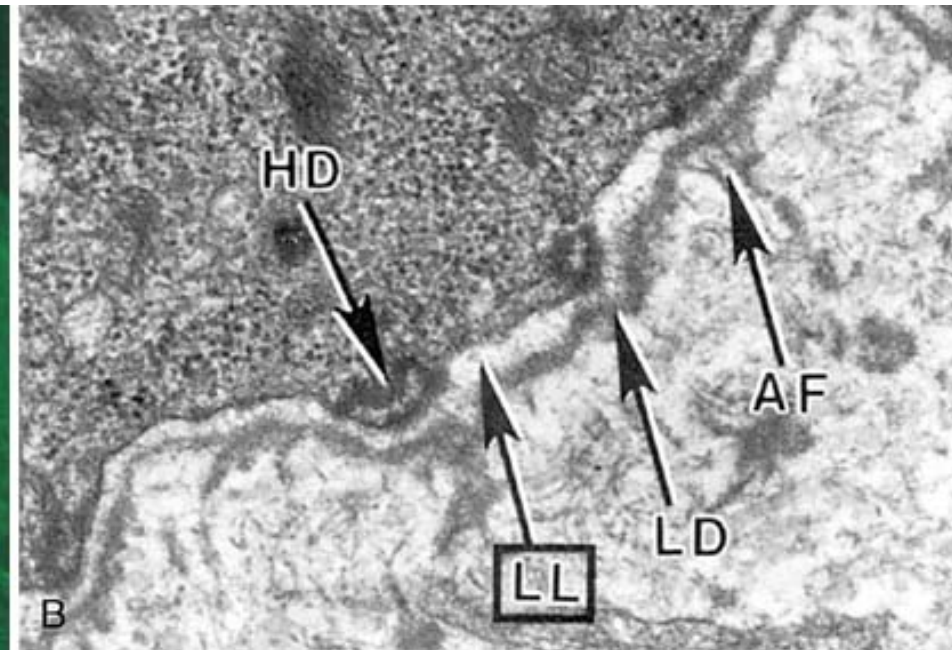
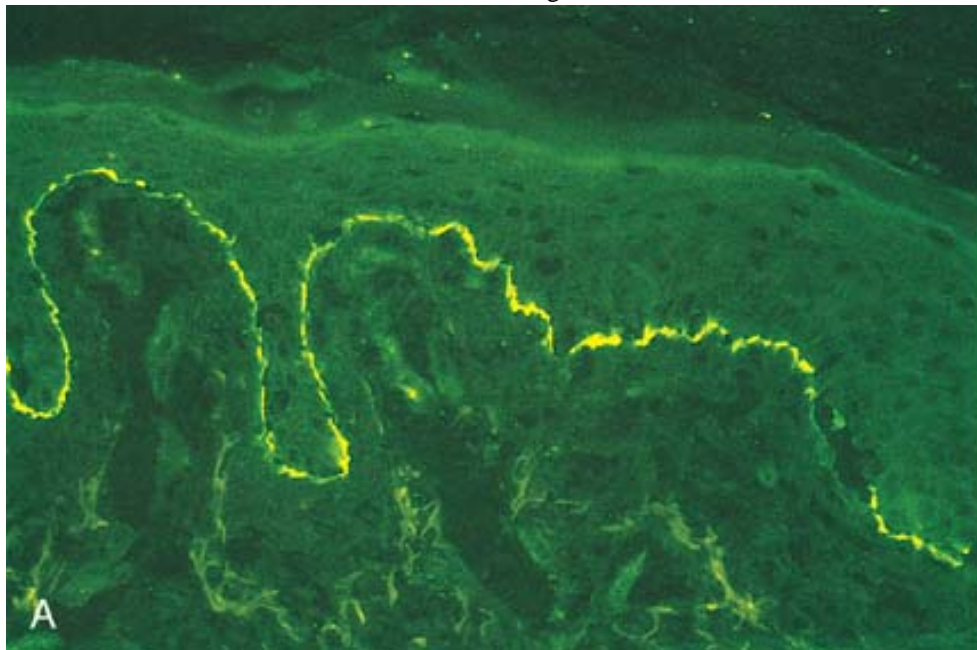


**Figure 25-36** Bullous pemphigoid. Clinical bullae (A) result from basal cell layer vacuolization, producing a subepidermal blister (B). Histopathology of the edge of an early lesion showing the onset of epidermal separation from the underlying dermis. Eosinophils, as well as lymphocytes and occasional neutrophils, may be intimately associated with basal cell layer destruction, creating the subepidermal cleft.



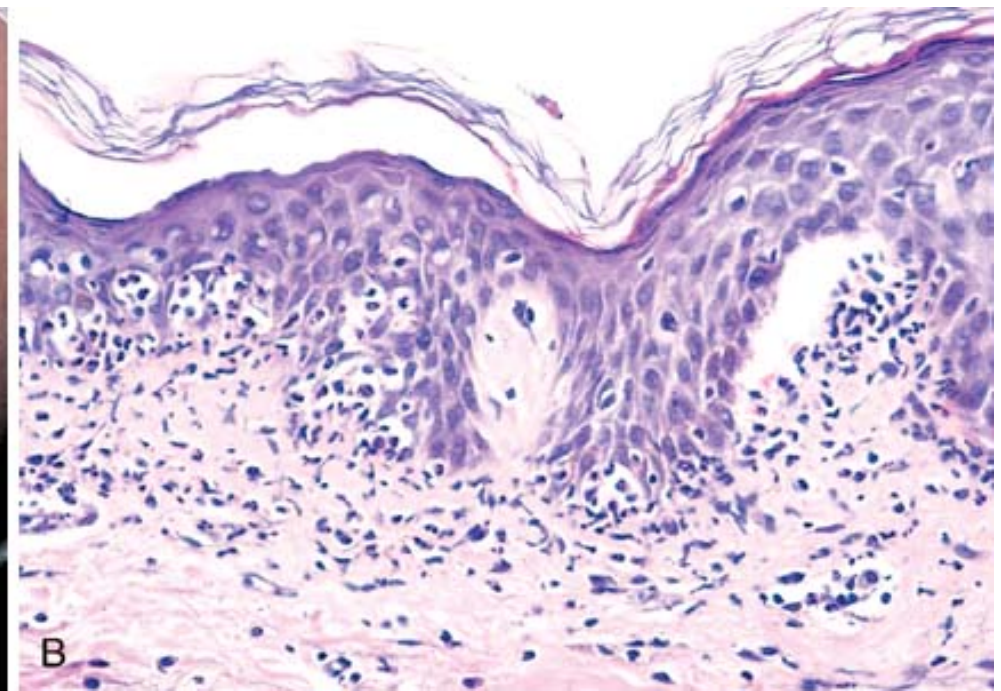
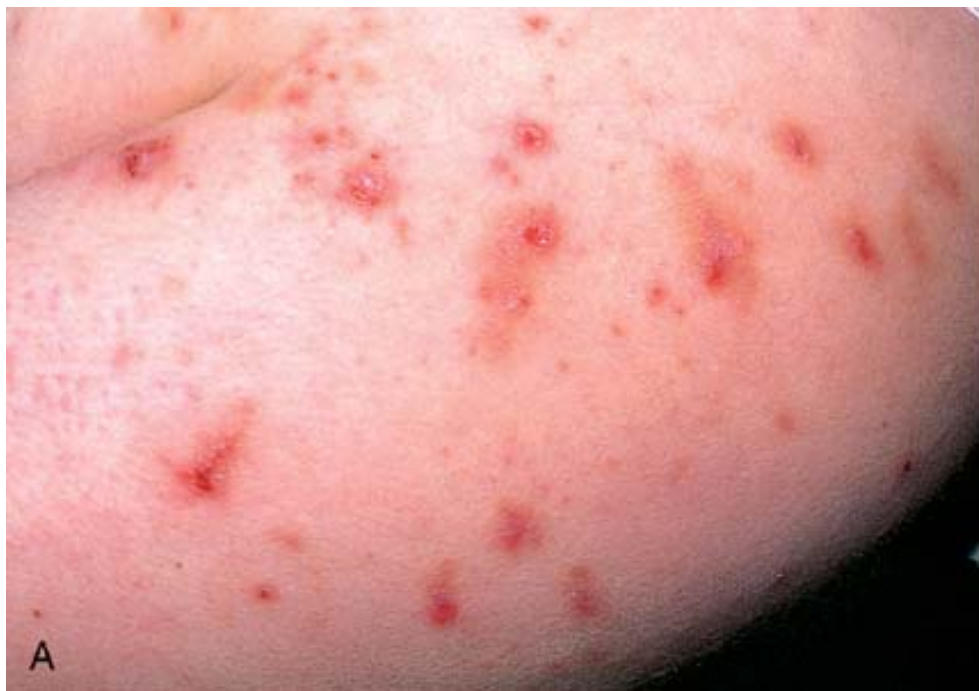

**Figure 25-37** *A*, Linear deposition of complement along the dermoepidermal junction in bullous pemphigoid; the pattern has been likened to ribbon candy. *B*, Bullous pemphigoid antigen is located in the lowermost portion of the basal cell cytoplasm in association with hemidesmosomes (HD), with blister formation affecting the lamina lucida (LL) of the basement membrane zone. LD, lamina densa; AF, anchoring fibrils.

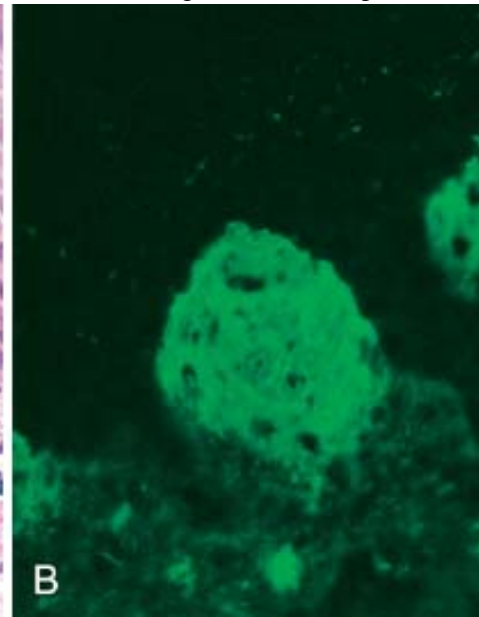
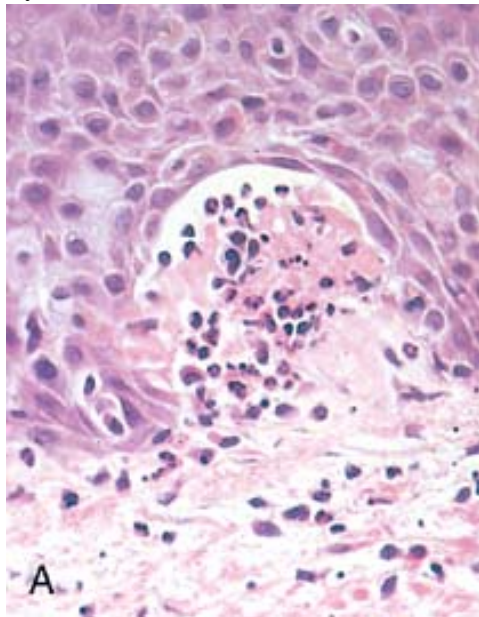


**Figure 25-38** Dermatitis herpetiformis. *A*, Clinical lesions consist of intact and eroded erythematous blisters that are often grouped together. *B*, Histologically, neutrophilic microabscesses selectively involve the dermal papilla.



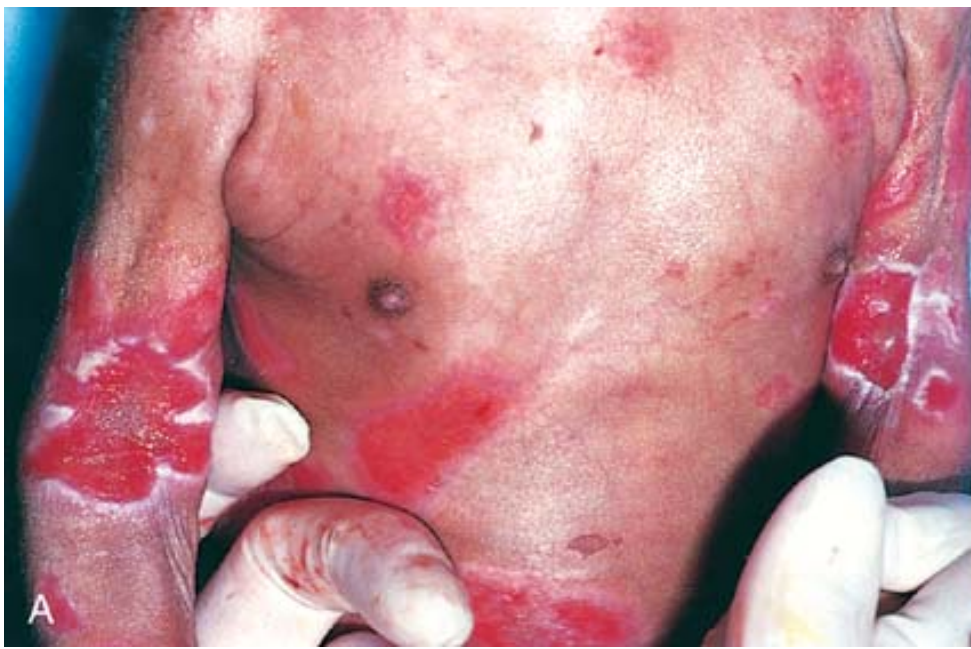


**Figure 25-39** Dermatitis herpetiformis. *A*, Papillary dermal microabscesses are associated with zones of dermoepidermal cleavage that eventually coalesce to form a clinical blister. *B*, By direct immunofluorescence, these abscesses are rich in IgA and fibrin deposits.

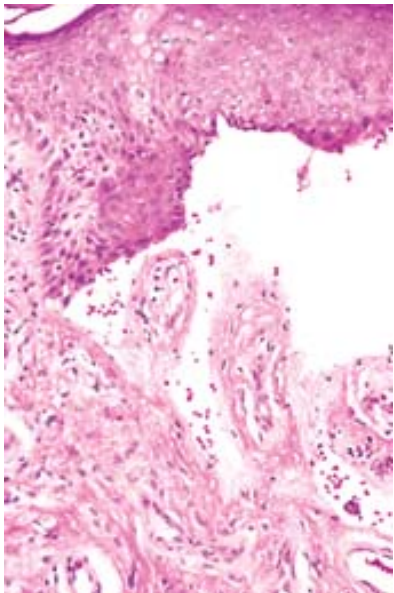


**Figure 25-40** Epidermolysis bullosa. *A*, Junctional epidermolysis bullosa showing typical erosions in flexural creases. *B*, A noninflammatory subepidermal blister in this case has formed at the level of the lamina lucida (Giemsa-stained section).



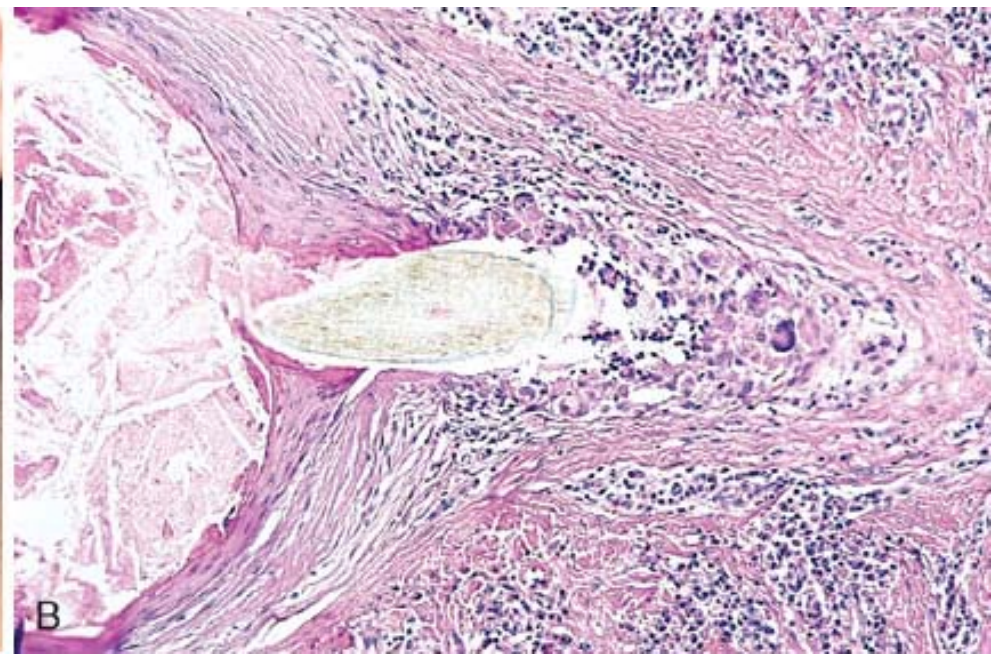
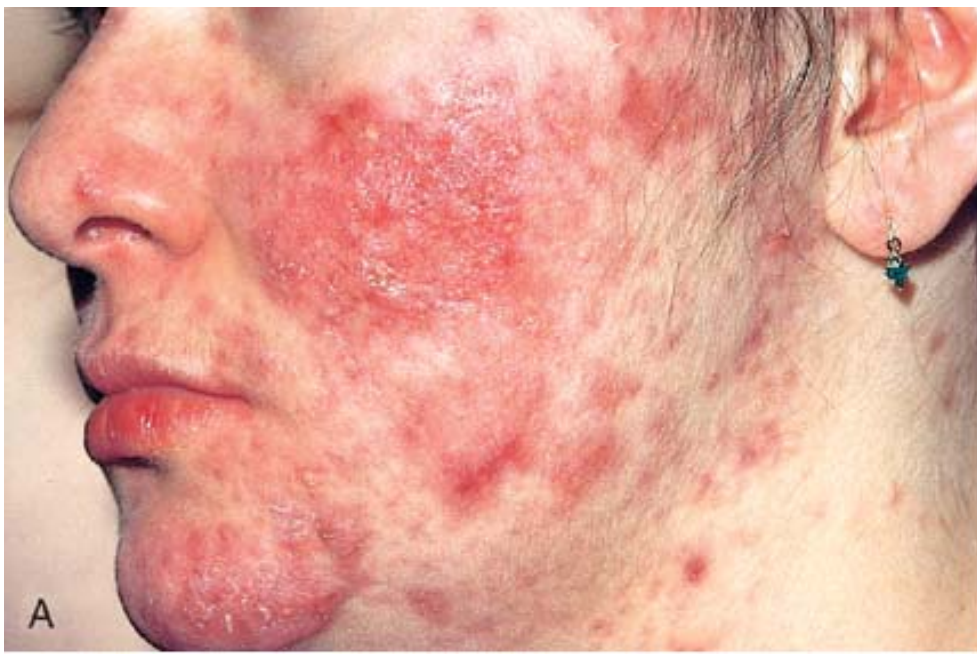

**Figure 25-41** Porphyria. A noninflammatory blister is forming at the dermoepidermal junction; note the seemingly rigid dermal papillae at the base that contain the altered superficial vessels.



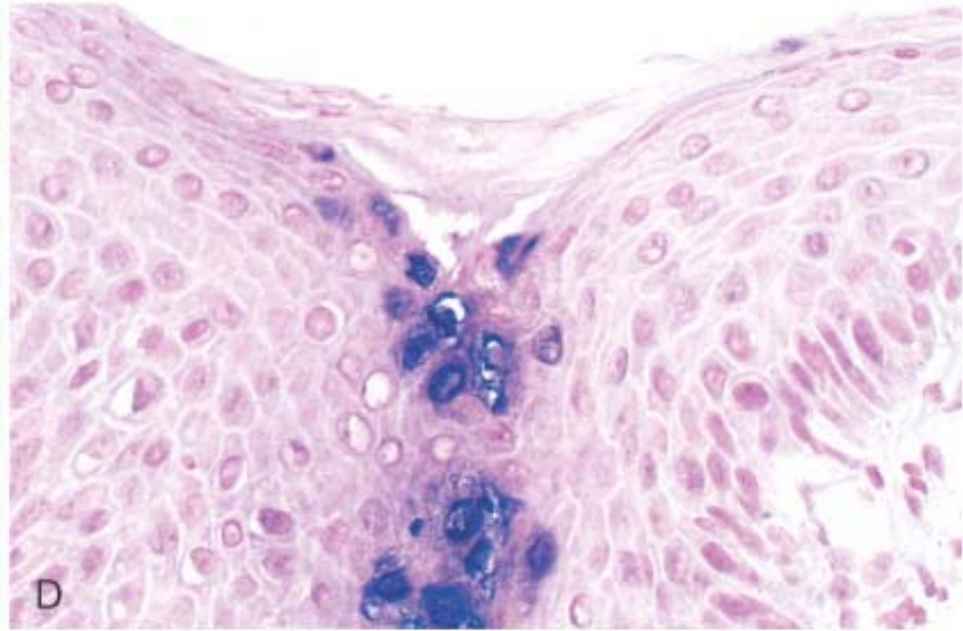
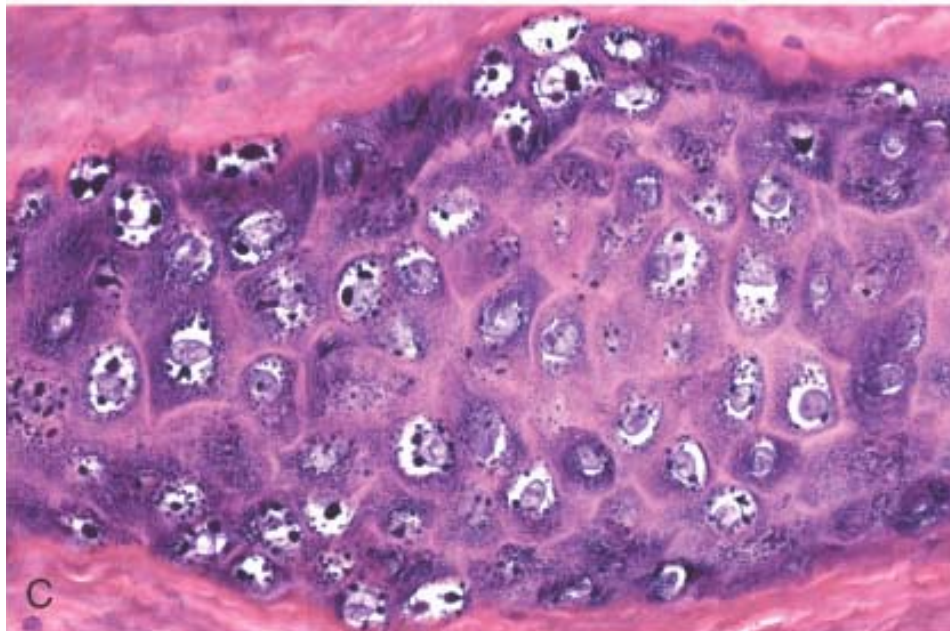
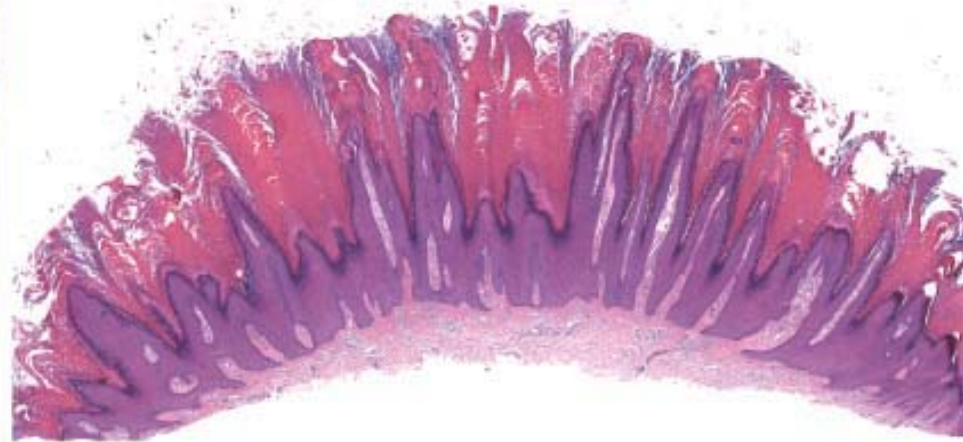
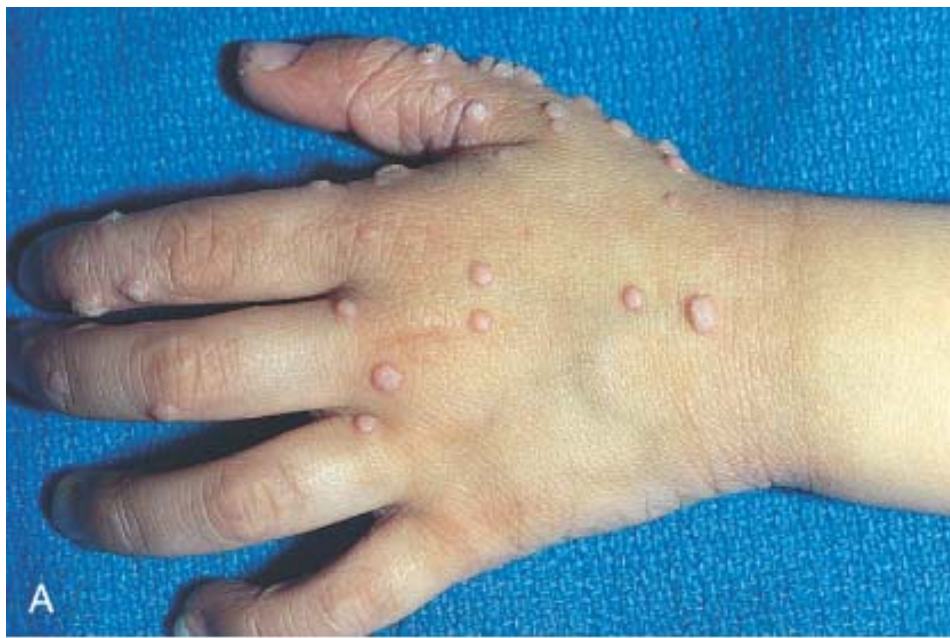**Figure 25-42** Acne. A, Inflammatory acne is characterized clinically by erythematous papules and pustules, with the possibility of eventual scarring. B, A portion of a hair shaft piercing the follicular epithelium and eliciting an inflammatory response and fibrosis.





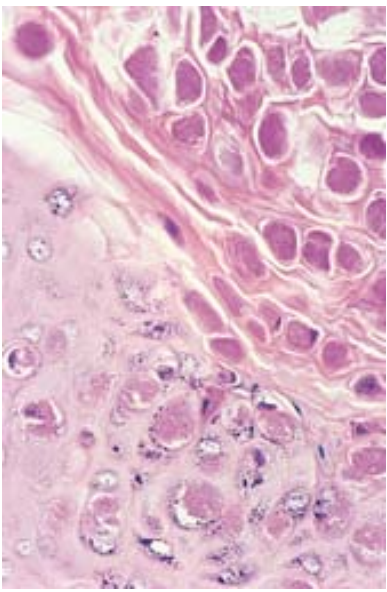
**Figure 25-43** Verruca vulgaris. *A*, Multiple papules with rough pebble-like surfaces. *B* (low power) and *C* (high power), histology of the lesions show papillomatous epidermal hyperplasia and cytopathic alterations that include nuclear pallor and prominent keratohyaline granules. *D*, In situ hybridization showing viral DNA within epidermal cells.



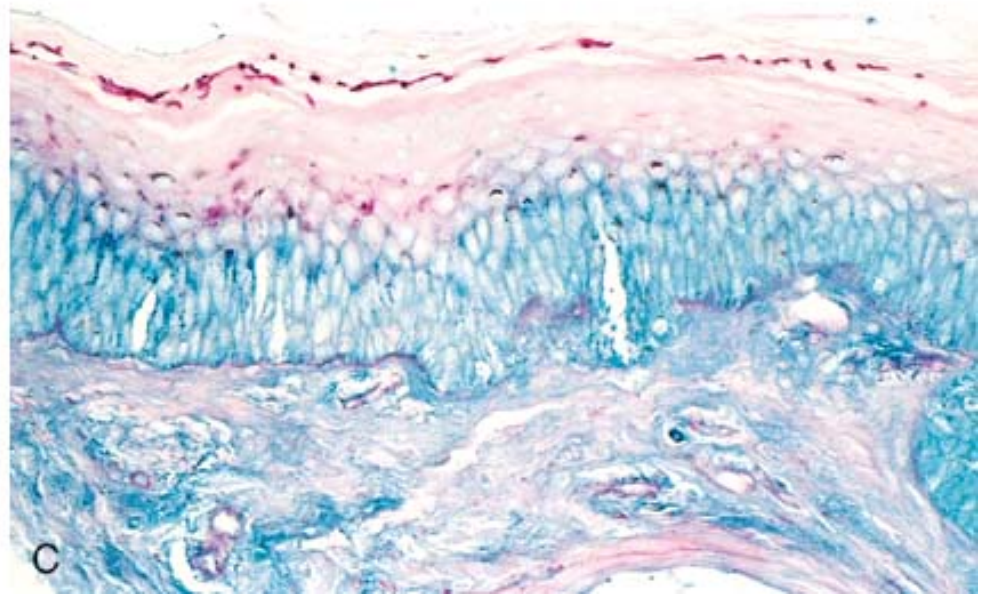
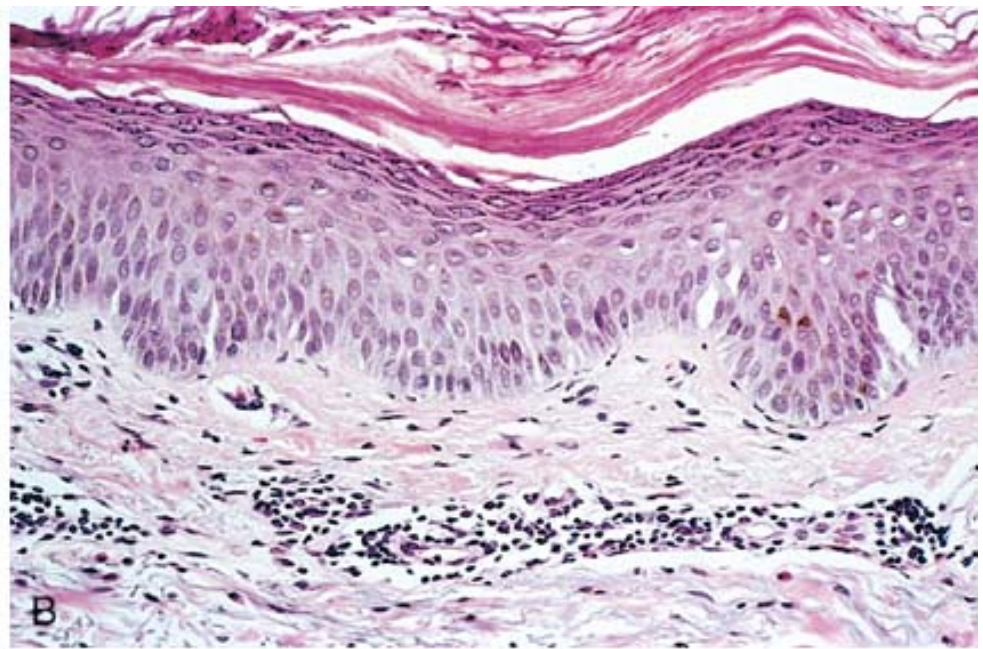
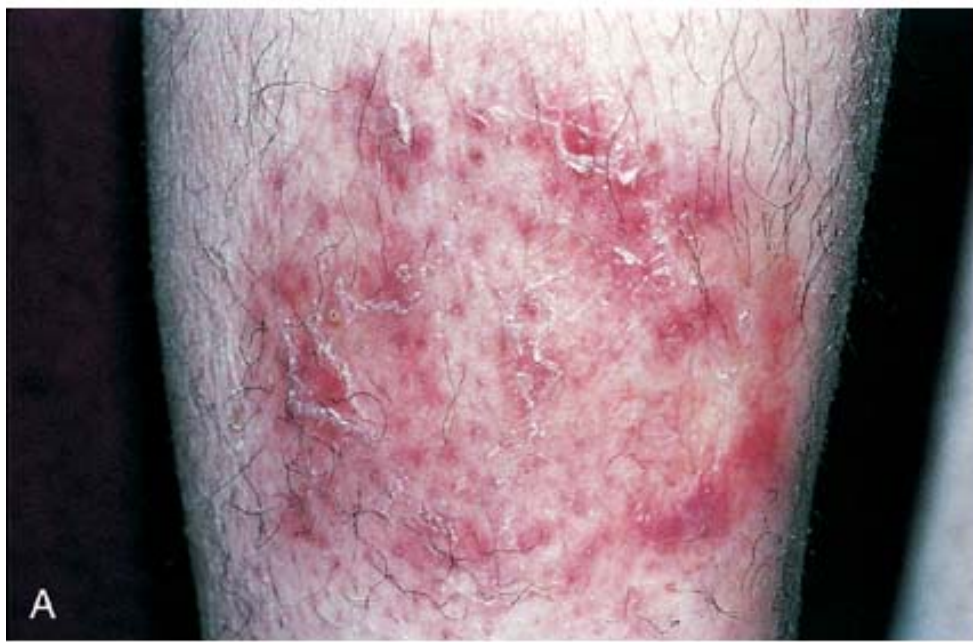

**Figure 25-44** Molluscum contagiosum. A focus of verrucous epidermal hyperplasia contains numerous cells with ellipsoid cytoplasmic inclusions (molluscum bodies) within the stratum granulosum and stratum corneum.



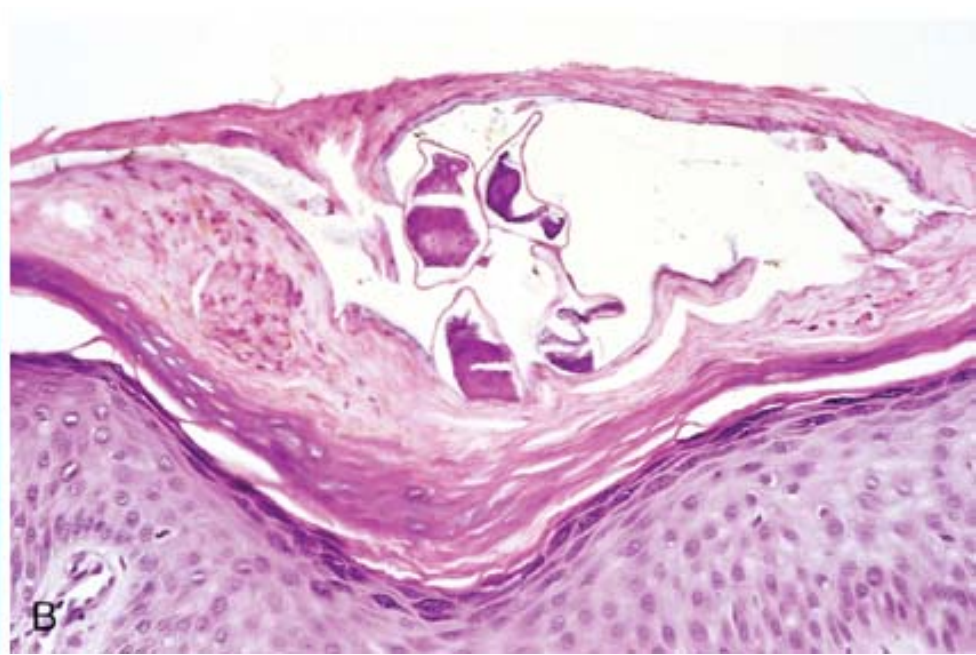
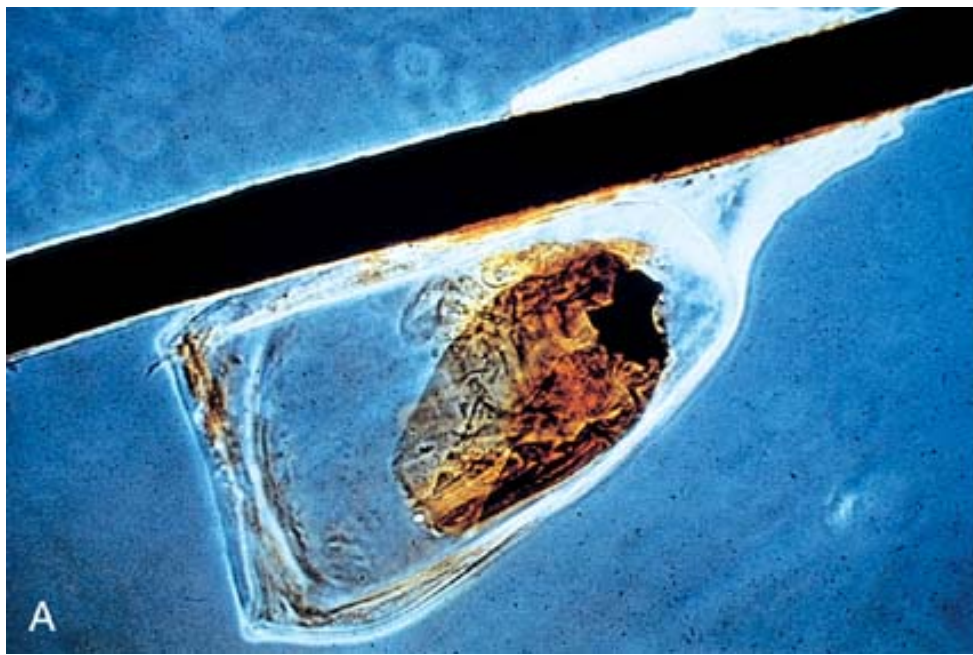


**Figure 25-45** Tinea. *A*, Characteristic plaque of tinea corporis. Routine histology (*B*) shows the picture of mild eczematous (spongiotic) dermatitis, and periodic acid-Schiff stain reveals deep red hyphae and yeast forms (*C*) within the stratum corneum.



**Figure 25-46** *A*, Pediculosis. Egg case (nit) of head louse attached to hair shaft. *B*, Portions of a scabies mite within a burrow involving the stratum corneum.





## References

1. Virchow R: Cellular Pathology. London, John Churchill, 1860, p 33.
2. Williams IR, Kupper TS: Immunity at the surface: homeostatic mechanisms of the skin immune system. *Life Sci* 58:1485, 1996.
3. Murphy GF: The secret of "NIN," a novel neural immunological network potentially integral to immunologic function in human skin. In Nickoloff BJ (ed): *Mast Cells, Macrophages and Dendritic Cells in Skin Disease*. Boca Raton, FL, CRC Press, 1993, pp 227–244.
4. Johnson KO: The roles and functions of cutaneous mechanoreceptors. *Curr Opin Neurobiol* 11:455, 2001.
5. Lavker RM, et al: Hair follicle stem cells. *J Invest Dermatol Symp Proc* 8:28, 2003.
6. Deguchi M, et al: 12E2: a cloned murine dermal cell with features of dermal dendrocytes and capacity to produce pathologic changes resembling early Kaposi's sarcoma *Am J Pathol* 163:1817, 2003.
7. Fishman P, et al: Autoantibodies to tyrosinase: the bridge between melanoma and vitiligo. *Cancer* 79:1461, 1997.
8. Le Poole IC, et al: Presence of T cells and macrophages in inflammatory vitiligo skin parallels melanocyte disappearance. *Am J Pathol* 148:1219, 1996.
9. Mandelcorn-Monson RL, et al: Cytotoxic T lymphocyte reactivity to gp 100, MelanA/MART-1, and tyrosinase, in HLA-A2-positive vitiligo patients. *J Invest Dermatol* 121:550, 2003.
10. Norris W: A case of fungoid disease. *Edinburgh Med Surg J* 16:562, 1820.
11. Clark WH Jr, et al: Origin of familial malignant melanomas from heritable melanotic lesions: the BK mole syndrome. *Arch Dermatol* 114:732, 1978.
12. Kamb A, Herlyn M: Malignant melanoma. In Vogelstein B, Kinzler K (eds.): *The Genetic Basis of Human Cancer*, New York, McGraw-Hill, 2002, pp 515–525.

13. Greene MH: Genetics of cutaneous melanoma and nevi [review]. *Mayo Clin Proc* 72:467, 1997.
  14. Monzon J, et al: *CDKN2A* mutations in multiple primary melanomas. *N Engl J Med* 338:879, 1998.
  15. Greene MH, et al: The high risk of melanoma in melanoma prone families with dysplastic nevi. *Ann Intern Med* 102:458, 1985.
  16. van Duinen CM, et al: The distribution of cellular adhesion molecules in pigmented skin lesions. *Cancer* 73:2131, 1994.
  17. Hussein MR, Wood GS: Molecular aspects of melanocytic dysplastic nevi. *J Mol Diagn* 4:71, 2002.
  18. Shannon JA, Kefford RF, Mann GJ: Responses to ultraviolet-B in cell lines from hereditary melanoma kindreds. *Melanoma Res* 11:1, 2001.
  19. Clark WH, et al: A study of tumor progression: the precursor lesions of superficial spreading and nodular melanoma. *Hum Pathol* 15:1147, 1985.
  20. Crowson AN, et al: The precursors of malignant melanoma. *Recent Results Cancer Res* 160:75, 2002.
  21. Weedon D: Lentigines, nevi, and melanomas. In Weedon D: *Skin Pathology*, 2nd ed. Edinburgh, Churchill Livingstone, 2002, pp 803–858.
  22. Breslow A: Prognosis in cutaneous melanoma: tumor thickness as a guide to treatment. *Pathol Annu* 15:1, 1980.
  23. Kim JC, Murphy GF: Dysplastic melanocytic nevi and prognostically indeterminate nevomelanocytic proliferations ("PINM Tumors"), In *Clinics in Laboratory Medicine*, Philadelphia, WB Saunders, 2000, pp 691–712.
  24. Elder DE, Murphy GF: Melanocytic tumors of the skin. In Rosai J, Sobin LH (eds.): *Atlas of Tumor Pathology, Third Series, Fascicle 1*. Washington, DC, Armed Forces Institute of Pathology, 1991, pp. 183–185.
  25. Clark WH Jr, et al: Model predicting survival in stage I melanoma based on tumor progression. *J Natl Cancer Inst* 81:1893, 1989.
  26. Balch CM, et al: Final version of the American Joint Committee on Cancer staging system for cutaneous melanoma. *Clin Oncol* 15:3635, 2001.
  27. Chen M, et al: Acantholytic variant of seborrheic keratosis. *J Cutan Pathol* 17:27, 1990.
  28. Ellis DL, et al: Melanoma, growth factors, acanthosis nigricans, the sign of Leser-Trélat, and multiple acrochordons. A possible role for alpha-transforming growth factor in cutaneous paraneoplastic syndromes. *N Engl J Med* 317:1582, 1987.
- 

29. Torley D, Bellus GA, Munro CS: Genes, growth factors and acanthosis nigricans. *Br J Dermatol* 147:1096, 2002.
30. Murphy GF, Elder D: Non-melanocytic tumors of the skin. In Rosai J, Sobin LH (eds.): *Atlas of Tumor Pathology, Third Series, Fascicle 1*. Washington, DC, Armed Forces Institute of Pathology, 1991, pp 61–154.
31. Hanssen AM, Fryns JP: Cowden syndrome. *J Med Genet* 32:117, 1995.



32. LeBoit PE: Can we understand keratoacanthoma? *Am J Dermatopathol* 24:116, 2002.
33. Perez MI, et al: *P53* oncoprotein expression and gene mutations in some keratoacanthomas. *Arch Dermatol* 133:189, 1997.
34. Matsumura Y, Ananthaswamy HN: Short-term and long-term cellular and molecular events following UV irradiation of skin: implications for molecular medicine. *Expert Rev Mol Med* 4:1, 2002.
35. Penn I: Neoplastic consequences of transplantation and chemotherapy. *Cancer Detect Prev* 1 (suppl):149, 1987.
36. Duthie MS, Kimber I, Norval M: The effects of ultraviolet radiation on the human immune system. *Br J Dermatol* 140:995, 1999.
37. Beissert S, Schwarz T: Mechanisms involved in ultraviolet light-induced immunosuppression. *J Investig Dermatol Symp Proc* 4:61, 1999.
38. Lu S, et al: No evidence of human papillomavirus DNA in actinic keratosis. *Arch Dermatol Res* 287:649, 1995.
39. Green CL, Khavari PA: Targets for molecular therapy of skin cancer. *Semin Cancer Biol* 14:63, 2004.
40. Bale AE: The nevoid basal cell carcinoma syndrome: genetics and mechanism of carcinogenesis. *Cancer Invest* 15:180, 1997.
41. Al-Ghazal SK, et al: Merkel cell carcinoma of the skin. *Br J Plast Surg* 49:491, 1996.
42. Miller DL, Weinstock MA: Nonmelanoma skin cancer in the United States: incidence. *J Am Acad Dermatol* 30:774, 1994.
43. Ries LAG, et al: SEER Cancer Statistics Review, 1993–1997. Bethesda, MD, National Cancer Institute, 2000.
44. Tsao H: Update on familial cancer syndromes and the skin. *J Am Acad Dermatol* 42:939, 2000.
45. Gorlin RJ, Goltz RW: Multiple nevoid basal-cell epithelioma, jaw cysts and bifid rib: a syndrome. *N Engl J Med* 262:908, 1962.
46. Mirowski GW, et al: Nevoid basal cell carcinoma syndrome. *J Am Acad Dermatol* 43:1092, 2000.
47. Rees J: Skin cancer. In B Vogelstein, KW Kinzler: *The Genetic Basis of Human Cancer*, New York, McGraw-Hill, 2002, pp 539–548.
48. Hahn H, et al: Mutations of the human homologue of *Drosophila* patched in the nevoid basal cell carcinoma syndrome. *Cell* 85:841, 1996.
49. Bonifas JM, et al: Activation of expression of hedgehog target genes in basal cell carcinoma. *J Invest Dermatol* 116:739, 2001.
50. Cohen MM, Jr: The hedgehog signaling network. *Am J Med Genet* 123A:5, 2003.
51. Nilsson M, et al: Induction of basal cell carcinomas and trichoepitheliomas in mice overexpressing GLI1. *Proc Natl Acad Sci U S A* 97:3438, 2000.
52. Bale AE, Yu K-P: The hedgehog pathway and basal cell carcinomas. *Hum Mol Genet* 10:757, 2001.
53. Kim MY, et al: Mutations of the *p53* and *PTCH* gene in basal cell carcinomas: UV mutation signature and strand bias. *J Dermatol Sci* 29:1, 2002.
54. Lacour JP: Carcinogenesis of basal cell carcinomas: genetics and molecular mechanisms. *Br J Dermatol* 146 (Suppl) 61:17, 2002.
55. D'Errico M, et al: UV mutation signature in tumor suppressor genes involved in skin carcinogenesis in xeroderma pigmentosum patients. *Oncogene* 19:463, 2000.
56. Einspahr JG, Bowden GT, Alberts DS: Skin cancer chemoprevention: strategies to save our skin. *Recent Results Cancer Res* 163:151, 2003.

57. Ortonne JP: From actinic keratosis to squamous cell carcinoma. *Br J Dermatol* 146 (Suppl) 61:20, 2002.
58. Soenge H, Ananthaswamy HN: Mechanisms of induction of skin cancer by UV radiation. *Frontiers Biosci* 2:538, 1997.
59. Majewski S, et al: Epidermodysplasia verruciformis. Immunological and nonimmunological surveillance mechanisms: role in tumor progression. *Clin Dermatol* 15:321, 1997.
60. Chin L: The genetics of malignant melanoma: lessons from mouse and man. *Nat Rev Cancer* 3:559, 2003.
61. Hayward NK: Genetics of melanoma predisposition. *Oncogene* 22:3053, 2003.
62. Piepkorn M: Melanoma genetics: an update with focus on the *CDKN2A(p16)/ARF* tumor suppressors. *J Am Acad Dermatol* 42:705, 2000.
63. Chin L, et al: Malignant melanoma: modern black plague and genetic black box. *GenesDevelop* 12:3467, 1998.
64. Cannon-Albright LA, et al: Assignment of a locus for familial melanoma, MLM, to chromosome 9p13-p22. *Science* 258:1148, 1992.
65. Kannengiesser C, et al: *CDKN2A* as a uveal and cutaneous melanoma susceptibility gene. *Genes Chromosomes Cancer* 38:265, 2003.
66. Sharpless NE, Chin L: The *INK4/ARF* locus and melanoma. *Oncogene* 22:3092, 2003.
67. Hussussian CJ, et al: Germline *p16* mutations in familial melanoma. *Nature Genet* 8:15, 1994.
68. Houghton AN, Polsky D: Focus on melanoma. *Cancer Cell* 2:275, 2002.
69. Pavey SJ, et al: Loss of *p16* expression is associated with histological features of melanoma invasion. *Melanoma Res* 12:539, 2002.
70. Pomerantz J, et al: The *INK4a* tumor suppressor gene product, p19ARF, interacts with MDM2 and neutralizes MDM2's inhibition of *p53*. *Cell* 92:713, 1998.
71. Rizos H, et al: A melanoma-associated germline mutation in exon 1  $\beta$  inactivates p14ARF. *Oncogene* 20:5543, 2001.
72. Randerson-Moor JA, et al: A germline deletion of *p14ARF* but not *CDKN2A* in a melanoma-neural system tumour syndrome family. *Hum Mol Genet* 10:55, 2001.
73. Soufir N, et al: Prevalence of *p16* and *CDK4* germline mutations in 48 melanoma-prone families in France. The French Familial Melanoma Study Group. *Hum Mol Genet* 7:209, 1998.
74. Davies H, et al: Mutations of the *BRAF* gene in human cancer. *Nature* 417:949, 2002.
75. Pollock PM, et al: High frequency of *BRAF* mutations in nevi. *Nat Genet* 33:19, 2002.
76. Dong J, et al: *BRAF* oncogenic mutations correlate with progression rather than initiation of human melanoma. *Cancer Res* 63:3883, 2003.
77. Calonje E: Is cutaneous benign fibrous histiocytoma dermatofibroma a reactive inflammatory process or a neoplasm? *Histopathology* 37:278, 2000.
78. Zegler BG, et al: Dermatofibroma (fibrous histiocytoma): an inflammatory or neoplastic disorder? *Histopathology* 38:379, 2001.
79. Lever WF, Schaumburg-Lever G: *Histopathology of the Skin*. Philadelphia, JB Lippincott, 1997, p 593.
80. Laman JD, et al: Langerhans-cell histiocytosis 'insight into DC biology'. *Trends Immunol* 24:190, 2003.
81. Berger CL, Edelson RL: Current concepts of the immunobiology and immunotherapy of cutaneous T cell lymphoma: insights gained through cross-talk between the clinic and the



bench. Leuk Lymphoma 44:1697, 2003.

82. Uchiyama T: Human T cell leukemia virus type I (HTLV-1) and human disease. Ann Rev Immunol 15:15, 1997.

83. Bakels V, et al: Immunophenotyping and gene rearrangement analysis provide additional criteria to differentiate between cutaneous T-cell lymphomas and pseudo-T-cell lymphomas. Am J Pathol 150:1941, 1997.

84. Longley BJ, et al: Somatic c-*KIT* activating mutation in urticaria pigmentosa and aggressive mastocytosis: establishment of clonality in a human mast cell neoplasm. Nat Genet 12:312, 1996.

85. Longley BJ, et al: Chronically *KIT*-stimulated clonally derived human mast cells show heterogeneity in different tissue microenvironments. J Invest Dermatol 108:792, 1997.

86. Nettis E, et al: Clinical and aetiological aspects in urticaria and angio-oedema. Br J Dermatol 148:501, 2003.

87. Schon MP, Zollner TM, Boehncke WH: The molecular basis of lymphocyte recruitment to the skin: clues for pathogenesis and selective therapies of inflammatory disorders. J Invest Dermatol 121:951, 2003.

88. Haas N, Hermes B, Henz BM: Adhesion molecules and cellular infiltrate: histology of urticaria. J Invest Dermatol Symp Proc 6:137, 2001.

89. Murphy GF, et al: Topical tretinoin replenishes CD1a-positive epidermal Langerhans cells in chronically photodamaged human skin. J Cutan Pathol 25:30, 1998.

90. Steinhoff M, et al: Modern aspects of cutaneous neurogenic inflammation. Arch Dermatol 139:1479, 2003.

91. Egan CL, et al: Characterization of unmyelinated axons uniting epidermal and dermal immune cells in primate and murine skin. J Cutan Pathol 25:20, 1998.

92. Murphy GF, et al: Reaction patterns in the skin and special dermatologic techniques. In Moschella S (ed): Dermatology. Philadelphia, WB Saunders, 1984, p 104.

93. Sackstein R, Messina JL, Elfenbein GJ: In vitro adherence of lymphocytes to dermal endothelium under shear stress: implications in pathobiology and steroid therapy of acute cutaneous GVHD. Blood 101:771, 2003.

94. Binet I, Wood KJ: In vivo models of inflammation: immune rejection and skin transplantation in vivo. Methods Mol Biol 225:239, 2003.

95. Murphy GF, et al: Cytotoxic T lymphocytes and phenotypically abnormal epidermal dendritic cells in fixed cutaneous eruptions. Hum Pathol 16:1264, 1985.

96. Gilliam A, et al: Apoptosis is the predominant form of epithelial target cell injury in acute experimental graft-versus-host disease. J Invest Dermatol 107:377, 1996.

97. Kim JC, et al: Novel expression of vascular cell adhesion molecule-1 (CD106) by squamous epithelium in experimental acute graft-versus-host disease. Am J Pathol 161:763, 2002.

98. de Jong EM: Psoriasis of the nails associated with disability in a large number of patients: results of a recent interview with 1,728 patients. Dermatology 193:300, 1996.

99. Gudjonsson JE, et al: Immunopathogenic mechanisms in psoriasis. Clin Exp Immunol 135:1, 2004.

100. Bowcock AM, Cookson WO: The genetics of psoriasis, psoriatic arthritis and atopic dermatitis. Hum Mol Genet 13 (Suppl 1):R43, 2004.

101. Kreuger G, Callis K: Potential of tumor necrosis factor inhibitors in psoriasis and psoriatic arthritis. Arch Dermatol 140:218, 2004.
102. Schechtman RC, et al: HIV and *Malassezia* yeasts: a quantitative study of patients presenting with seborrheic dermatitis. Br J Dermatol 133:694, 1995.
103. Gupta A, Bluhm R: Seborrheic dermatitis. J Eur Acad Dermatol Venereol 18:13, 2004.
104. Hay RJ, Graham-Brown RA: Dandruff and seborrheic dermatitis: causes and management. Clin Exp Dermatol 22:3, 1997.
105. Fischer M, et al: Skin function and skin disorders in Parkinson's disease. J Neural Transm 108:205, 2001.
106. Franck JM, Young AW Jr: Squamous cell carcinoma in situ arising within lichen planus of the vulva. Dermatol Surg 21:890, 1995.
107. Iijima W, et al: Infiltrating CD8+ T cells in oral lichen planus predominantly express CCR5 and CXCR3 and carry respective chemokine ligands RANTES/CCL5 and IP-10/CXCL10 in their cytolytic granules: a potential self-recruiting mechanism. Am J Pathol 163:261, 2003.
108. Maddison PJ: Is it SLE? Best Pract Res Clin Rheumatol 16:167, 2002.
109. Boumpas DT, et al: Systemic lupus erythematosus: emerging concepts. Part 2: Dermatologic and joint disease, the antiphospholipid antibody syndrome, pregnancy and hormonal therapy, morbidity and mortality, and pathogenesis. Ann Intern Med 123:42, 1995.
110. Hashimoto T: Recent advances in the study of the pathophysiology of pemphigus. Arch Dermatol Res 295 (Suppl 1):S2, 2003.
111. Hacker-Foegen MK, et al: Pathogenicity and epitope characteristics of anti-desmoglein-1 from pemphigus foliaceus patients expressing only IgG1 autoantibodies. J Invest Dermatol 121:1373, 2003.
112. Koch PJ, et al: Targeted disruption of the pemphigus vulgaris antigen (desmoglein 3) gene in mice causes loss of keratinocyte cell adhesion with a phenotype similar to pemphigus vulgaris. J Cell Biol 137:1091, 1997.
113. Xue W, Hashimoto K, Toi Y: Functional involvement of urokinasetype plasminogen activator receptor in pemphigus acantholysis. J Cutan Pathol 25:469, 1998.
114. Seishima M, et al: Pemphigus IgG induces expression of urokinase plasminogen activator receptor on the cell surface of cultured keratinocytes. J Invest Dermatol 10:650, 1997.
115. Hanakawa Y, et al: Expression of desmoglein 1 compensates for genetic loss of desmoglein 3 in keratinocyte adhesion. J Invest Dermatol 119:27, 2002.
116. Yeh SW, et al: Blistering disorders: diagnosis and treatment. Dermatol Ther 16:214, 2003.
117. Imber MJ, et al: The immunopathology of bullous pemphigoid. In Ahmed AR (ed): Clinics in Dermatology-Bullous Pemphigoid. Philadelphia, JB Lippincott, 1987, p 81.
118. Liu Z, et al: A major role for neutrophils in experimental bullous pemphigoid. J Clin Invest 100:1256, 1997.
119. Duhring L: Dermatitis herpetiformis. JAMA 250:212, 1983.
120. Bickle K, Roark TR, Hsu S: Autoimmune bullous dermatoses: a review. Am Fam Physician 65: 1861, 2002.
121. Mitsuhashi Y, Hashimoto I: Genetic abnormalities and clinical classification of epidermolysis bullosa. Arch Dermatol Res 295:529, 2003.
122. Mallipeddi R, et al: Dilemmas in distinguishing between dominant and recessive forms of dystrophic epidermolysis bullosa. Br J Dermatol 149:810, 2003.
123. Harper JC, Thiboutot DM: Pathogenesis of acne: recent research advances. Adv Dermatol 19:1–10, 2003.



124. Walton S, et al: Clinical, ultrasound and hormonal markers of androgenicity in acne vulgaris. Br J Dermatol 133:249, 1995.

125. Leyden JJ: New understandings of the pathogenesis of acne. J Am Acad Dermatol 32(pt 3):S15, 1995.

126. Miskin JE, et al: Propionibacterium acnes, a resident of lipid-rich human skin, produces a 33 kDa extracellular lipase encoded by gehA. Microbiology 143:1745, 1997.

127. Berson DS, Shalita AR: The treatment of acne: the role of combination therapies. J Am Acad Dermatol 32(pt 3):S31, 1995.

128. de Villiers EM: Papillomavirus and HPV typing. Clin Dermatol 15:199, 1997.

129. Hart WR: Vulvar intraepithelial neoplasia: historical aspects and current status. Int J Gynecol Pathol 20:16, 2001.

130. Majewski S, Jablonska S: Human papillomavirus-associated tumors of the skin and mucosa. J Am Acad Dermatol 36(pt 1):659, 1997.

131. Harris AJ, et al: A novel human papillomavirus identified in epidermodysplasia verruciformis. Br J Dermatol 136:587, 1997.

132. Sadick NS: Current aspects of bacterial infections of the skin. Dermatol Clin 15:341, 1997.

133. Darmstadt GL, Lane AT: Impetigo: an overview. Pediatr Dermatol 11:293, 1994.

134. Hanakawa Y, et al: Molecular mechanisms of blister formation in bullous impetigo and staphylococcal scalded skin syndrome. J Clin Invest 110:53, 2002.

135. Leyden JJ, Aly R: Tinea pedis. Semin Dermatol 12:280, 1993.

Chapter 26 - Bones, Joints, and Soft Tissue Tumors

Andrew E. Rosenberg MD

## Normal

The skeletal system is as vital to life as any organ system because of its essential roles in mechanical support and mineral homeostasis. Importantly, the skeleton also houses the hematopoietic elements, protects viscera, and determines body size and shape. The skeletal system is composed of 206 bones that vary in size and shape (tubular, flat, cuboid). The bones are interconnected by a variety of joints that allow for a wide range of movement while maintaining structural stability.

Bone is a type of connective tissue, and it is unique because it is one of the few tissues that normally undergo mineralization. Biochemically, it is defined by its distinctive admixture of inorganic elements (65%) and organic matrix (35%). The inorganic component, calcium hydroxyapatite [ $10\text{Ca}:6(\text{PO}_4):(\text{OH})_2$ ], is the mineral that gives bone strength and hardness, and is the storehouse for 99% of the body's calcium, 85% of the body's phosphorus, and 65% of the body's sodium and magnesium. The formation of hydroxyapatite crystal in bone is a phase transformation from liquid to solid analogous to the conversion of water to ice. The process involves the initiation and induction of mineralization by the organic matrix and it is tightly regulated by numerous factors.<sup>[1]</sup> The rate of mineralization can vary, but normally there is a 12- to 15-day lag time between the formation of the matrix and its mineralization. Bone that is unmineralized is known as *osteoid*.

The organic component includes the cells of bone and the proteins of the matrix. The bone-forming cells include the osteoprogenitor cells, osteoblasts, and osteocytes. The generation and stimulation of these cells are regulated by cytokines and growth factors such as bone morphogenic proteins (BMPs), fibroblast growth factor (FGF), platelet-derived growth factor (PDGF), insulin-like growth factor, and transforming growth factor- $\beta$  (TGF- $\beta$ ).<sup>[2]</sup>

- *Osteoprogenitor* cells are pluripotent mesenchymal stem cells that are located in the vicinity of all bony surfaces. When appropriately stimulated by growth factors such as bone morphogenic proteins, which are members of the TGF- $\beta$  superfamily, they undergo cell division and produce offspring that differentiate into osteoblasts. The process of osteoblastic differentiation is initiated and governed by the transcription factor core binding factor  $\alpha 1$ , which activates osteoblast-specific gene expression.<sup>[3]</sup> The generation of osteoblasts from osteoprogenitor cells is vital to growth, remodeling, and repair of bone throughout life.
- *Osteoblasts and surface lining cells* are located on the surface of bone and synthesize, transport, and arrange

the many proteins of matrix detailed later ( Fig. 26-1). They also initiate the process of mineralization. Osteoblasts express cell-surface receptors that bind many hormones (parathyroid hormone [PTH], vitamin D, and estrogen), cytokines, growth factors, and extracellular matrix proteins. Recently, the hormone leptin and low-density lipoprotein receptor-related protein 5 have been shown to play an important role in determining osteoblastic activity, and they may represent evidence of central nervous system and cell-autonomous control of bone mass, respectively.<sup>[4][5][6]</sup> Metabolically active osteoblasts have a life span of approximately 3 months and then either undergo apoptosis, become surrounded by matrix and transform into *osteocytes*, or become quiescent, flattened, bone surface-lining cells.

- *Osteocytes* are more numerous than any other bone-forming cell and outnumber osteoblasts by about 10:1. Although encased by bone, they communicate with each other and with surface cells via an intricate network of tunnels through the matrix known as *canaliculi*. The osteocytic cell processes traverse the canaliculi, and their contacts along gap junctions allow the transfer of surface membrane potentials and substrates. The large number of osteocytic processes and their distribution throughout bone tissue enable them to be the key cells in several biologic processes. Studies have shown that this network may be important in controlling the second-to-second fluctuations in serum calcium and phosphorus levels by altering the concentration of these minerals in the local extracellular fluid compartment. Osteocytes also can detect mechanical forces and translate them into biologic activity, including the release of chemical mediators by signal transduction pathways, which activate second messengers such as cyclic adenosine monophosphate (cAMP).<sup>[7]</sup>
- The *osteoclast* is the cell responsible for bone resorption. It is derived from hematopoietic progenitor cells that also give rise to monocytes and macrophages. Information regarding the molecular regulation of osteoclast formation in humans is limited. In mice, a number of transcription factors, including PU.1 and Fos, are essential for developing an osteoclast phenotype.<sup>[8]</sup> The cytokines and growth factors crucial for osteoclast differentiation and maturation in humans include interleukin (IL)-1, IL-3, IL-6, IL-11, tumor



necrosis factor (TNF), granulocyte-macrophage colony-stimulating factor (GM-CSF), and macrophage colony-stimulating factor (M-CSF).<sup>[9]</sup> These factors work by either stimulating osteoclast progenitor cells or participating in a paracrine system in which osteoblasts and marrow stromal cells play a central role. This paracrine system is essential to bone metabolism, and its mediators include the molecules RANK (Receptor Activator for Nuclear factor  $\kappa$ B), RANK ligand (RANKL), and osteoprotegerin (OPG).<sup>[9]</sup> <sup>[10]</sup> RANK is a member of the TNF family of receptors expressed mainly on cells of macrophage/monocytic lineage such as preosteoclasts. When this receptor binds its specific ligand (RANKL) through cell-to-cell contact, osteoclastogenesis is initiated. RANKL is produced by and expressed on the cell membranes of osteoblasts and marrow stromal cells; its major role in bone metabolism is stimulation of osteoclast formation, fusion, differentiation, activation, and survival. The actions of RANKL can be blocked by another member of the TNF family of receptors, osteoprotegerin (OPG), which is a soluble protein produced by a number of tissues, including bone, hematopoietic marrow cells, and immune cells. OPG inhibits osteoclastogenesis by acting as a decoy receptor that binds to RANKL, thus preventing the interaction of RANK with RANKL. Therefore, interplay between bone cells and these molecules permits osteoblasts and stromal cells to control osteoclast development<sup>[10]</sup> ( Fig. 26-2 ). This ensures the tight coupling of bone formation and resorption vital to the success of the skeletal system, and provides a mechanism for a wide variety of biologic mediators (hormones, cytokines, growth factors) to influence the homeostasis of bone tissue.

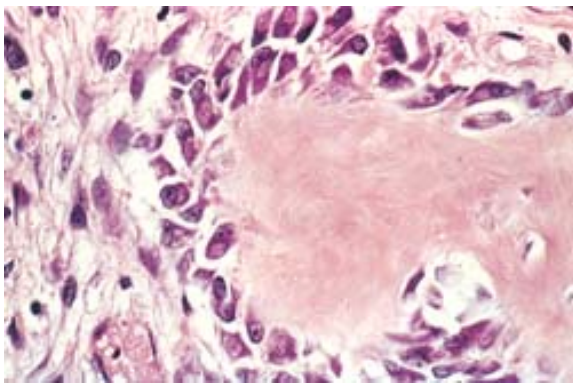
Mature multinucleated osteoclasts (containing 6 to 12 nuclei) form from fusion of circulating mononuclear precursors and have a limited life span (approximately 2 weeks). They are intimately related to the bone surface ( Fig. 26-3 ), where their activity is initiated by binding to matrix adhesion proteins. The scalloped *resorption pits* they produce, and frequently reside in, are known as *Howship lacunae*. The portion of the osteoclast cell membrane overlying the resorption surface is modified by numerous villous extensions, known as the *ruffled border*, which serve to increase the membrane surface area. The plasmalemma bordering this region is specialized and forms a seal with the underlying bone, preventing leakage of digestion products. This self-contained extracellular space is analogous to a secondary lysosome, and the osteoclast acidifies it with a hydrogen pump system that solubilizes the mineral. The osteoclast also releases into this space a multitude of enzymes that help disassemble the matrix proteins into amino acids and liberate and activate growth factors, cytokines, and enzymes (such as collagenase), which have been previously deposited and bound to the matrix by osteoblasts. *Thus, as bone is broken down to its elemental units, substances are released into the microenvironment that initiate its renewal* ( Fig. 26-4 ).

- The *proteins of bone* include type 1 collagen and a family of noncollagenous proteins that are derived mainly from osteoblasts. Type 1 collagen forms the backbone of matrix and accounts for 90% of the weight of the organic component. Osteoblasts deposit collagen either in a random weave known as *woven bone* or in an orderly layered manner designated

*lamellar bone* ( Fig. 26-5). Normally, woven bone is seen in the fetal skeleton and is formed at growth plates. Its advantages are that it is produced quickly and resists forces equally from all directions. The presence of woven bone in the adult is always indicative of a pathologic state; however, it is not diagnostic of a particular disease. For instance, in circumstances requiring rapid reparative stability, such as a fracture, woven bone is produced. It is also formed around sites of infection and composes the matrix of bone-forming tumors. *Lamellar bone, which gradually replaces woven bone during growth, is deposited much more slowly and is stronger than woven bone.* There are four different types of lamellar bone. Three are present only in the cortex—circumferential, concentric, and interstitial ( Fig. 26-6). The fourth type, trabecular lamellae, composes the bone trabeculae in which the lamellae are oriented parallel to the long axis of the trabeculum.

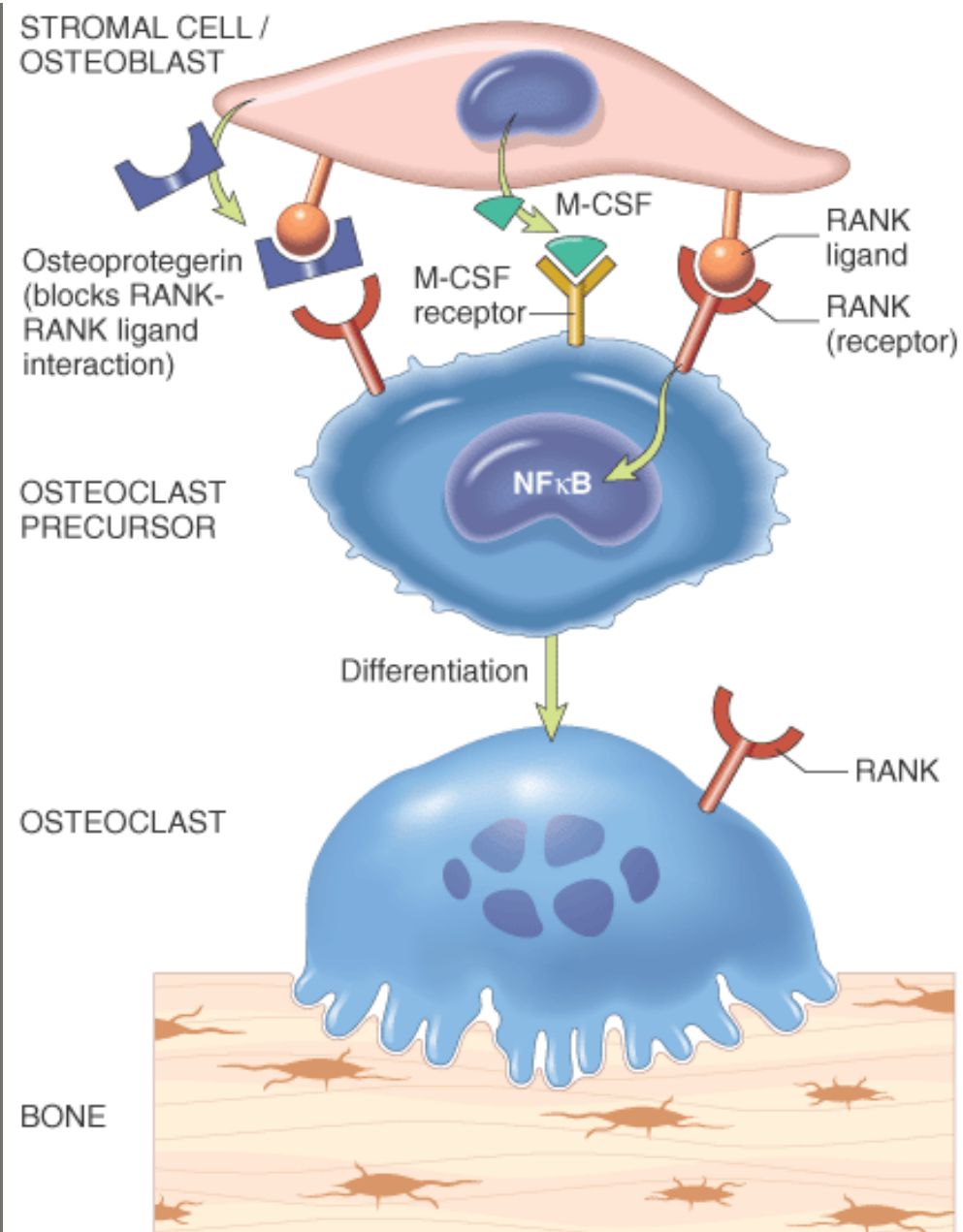
The noncollagenous proteins of bone are bound to the matrix and grouped according to their function as adhesion proteins, calcium-binding proteins, mineralization proteins, enzymes, cytokines, and growth factors ( Table 26-1).<sup>[11]</sup> Of these, only osteocalcin is unique to bone. It is used as a sensitive and specific serum marker for osteoblast activity. Cytokines and growth factors control bone cell proliferation, maturation, and metabolism.<sup>[12]</sup> They serve an important messenger function in translating mechanical and metabolic signals into local bone cell activity and eventual skeletal adaptation. In this fashion the skeleton is uniquely able to change its structure in response to new physical forces; witness the repositioning of teeth by the forces of braces.

**Figure 26-1** Active osteoblasts synthesizing bone matrix. The surrounding spindle cells represent osteoprogenitor cells.

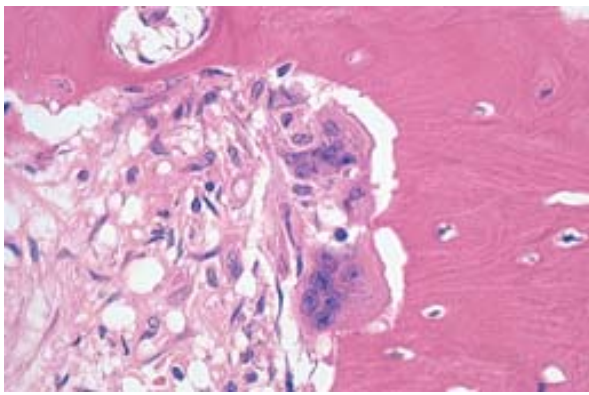


**Figure 26-2** Paracrine molecular mechanisms that regulate osteoclast formation and function. Osteoclasts are derived from the same stem cells that produce macrophages. Osteoblast/stromal cell membrane-associated RANK ligand (RANKL) binds to its receptor RANK located on the cell surface of osteoclast precursors. This interaction in the background of macrophage colony-stimulating factor (M-CSF) causes the precursor cells to produce functional osteoclasts. Stromal cells also secrete osteoprotegerin (OPG) which acts as a decoy receptor for RANKL, preventing it from binding the RANK receptor on osteoclast precursors. Consequently OPG prevents bone resorption by inhibiting osteoclast differentiation.

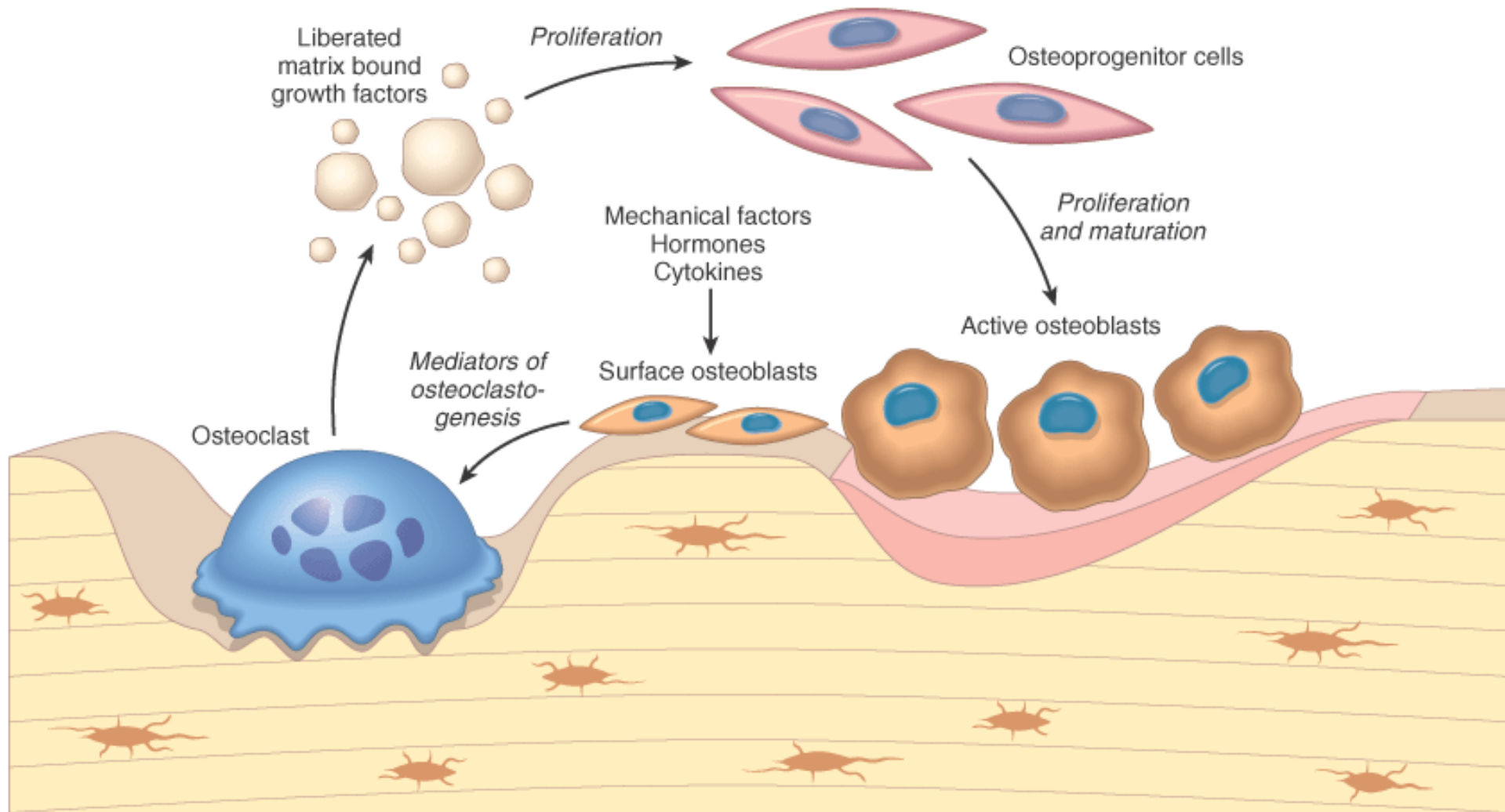




**Figure 26-3** Two osteoclasts resorbing bone.

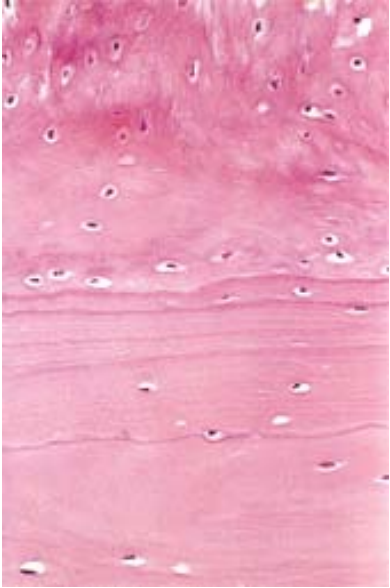


**Figure 26-4** Bone resorption and formation are coupled processes that are controlled by systemic factors and local cytokines and growth factors, some of which are deposited in the bone matrix. Cytokines, growth factors, and signal-transducing molecules are key in the communication between osteoblasts and osteoclasts.

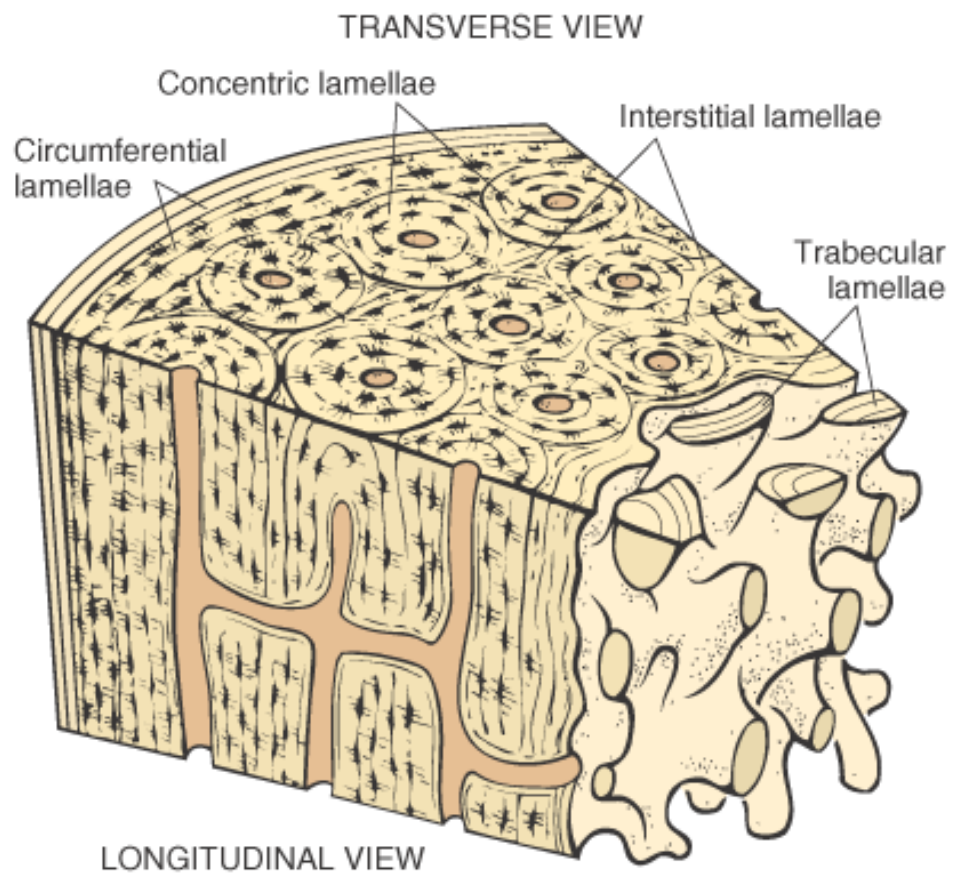




**Figure 26-5** Woven bone (*top*) deposited on the surface of pre-existing lamellar bone (*bottom*).



**Figure 26-6** The schematic of normal bone structure reveals the subperiosteal and endosteal circumferential lamellae, concentric lamellae about vascular cores creating haversian systems, and the interstitial lamellae that fill the spaces in between the haversian systems. The trabecular lamellae extend from the endosteal surface. The individual lamellae are punctuated by osteocytic lacunae with their finely ramifying and interconnecting canals, which contain cell processes.



**TABLE 26-1** -- Proteins of Bone Matrix

***Osteoblast-Derived Proteins***

Type 1 collagen

Cell adhesion proteins

••Osteopontin, fibronectin, thrombospondin

Calcium-binding proteins

••Osteonectin, bone sialoprotein

Proteins involved in mineralization

••Osteocalcin

Enzymes

••Collagenase, alkaline phosphatase

Growth factors



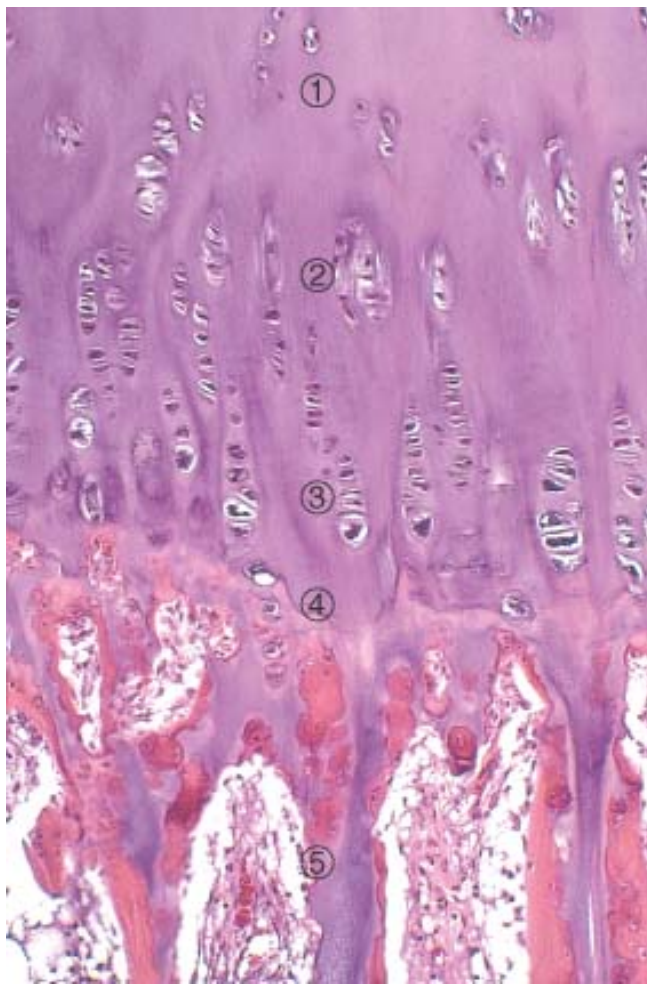
••IGF-1, TGF- $\beta$ , PDGF
Cytokines
••Prostaglandins, IL-1, IL-6, RANKL
<b><i>Proteins Concentrated from Serum</i></b>
$\beta_2$ -microglobulin
Albumin
IGF, insulin-like growth factor; TGF, transforming growth factor; PDGF, platelet-derived growth factor; IL, interleukin; RANKL, RANK ligand.

degradative changes, mineralizes, and is removed by osteoclast-type cells. This process, which progresses up and down the length of the bone, allows for the ingrowth of blood vessels and osteoprogenitor cells that provide the bone-forming cells. Concurrently, the periosteum in the midshaft of the anlage produces osteoblasts that deposit the beginnings of the cortex. This region is known as the *primary center of ossification*. In the epiphyses, a similar sequence of events leading to the removal of cartilage occurs (*secondary center of ossification*) such that a plate of the cartilage model becomes entrapped between the expanding centers of ossification; this structure is known as the *physis*, or *growth plate* ( Fig. 26-7 ). The chondrocytes within the growth plate undergo a series of events, including proliferation, growth, maturation, and necrosis. Important regulators of this sequence of chondrocyte growth and maturation are the *Indian hedgehog* gene and parathyroid hormone (PTH)-related protein (PTHrP).<sup>[5]</sup> <sup>[9]</sup> Eventually, the cartilage matrix mineralizes and this acts as a signal for its resorption by osteoclasts; however, remnant struts persist and act as scaffolding for the deposition of bone on their surfaces. These structures, composed of a core of cartilage covered by a layer of bone, are known as *primary spongiosa*. The process of enchondral ossification also occurs at the base of articular cartilage, and by this mechanism bones increase in length and articular surfaces increase in diameter. In contrast, bones derived from *intramembranous formation*, such as the cranium and portions of the clavicles, are formed by osteoblasts directly from a fibrous layer of tissue derived from mesenchyme. Because bone tissue is made only by osteoblasts, the enlargement of bones is achieved only by the deposition of new bone on a pre-existing surface. This mechanism of *appositional growth* is key to understanding the facets of bone growth and modeling.

## Pathology

The skeletal system is susceptible to circulatory, inflammatory, neoplastic, metabolic, and congenital disorders, similar to the other organ systems of the body. The complexity of

**Figure 26-7** Active growth plate with ongoing enchondral ossification. 1, Reserve zone. 2, Zone of proliferation. 3, Zone of hypertrophy. 4, Zone of mineralization. 5, Primary spongiosa.



**TABLE 26-2** -- Molecular Genetics of Diseases of the Skeleton

Human Disorder	Gene Mutation	Affected Molecule	Phenotype
<i>Defects in Transcription Factors Producing Abnormalities in Mesenchymal Condensation and Related Cell Differentiation</i>			
Synpolydactyly	HOXD-13	Transcription factor	Extra digit with fusion
Waardenburg syndrome	PAX-3	Transcription factor	Hearing loss, abnormal pigmentation, craniofacial abnormalities
Greig syndrome	GLI3	Transcription factor	Synpolydactyly, craniofacial abnormalities
Campomelic dysplasia	SOX9	Transcription factor	Sex reversal, abnormal skeletal development
Oligodontia	PAX9	Transcription factor	Congenital absence of teeth
Nail-patella syndrome	LMX1B	Transcription factor	Hypoplastic nails, hypoplastic or aplastic patellae, dislocated radial head, progressive nephropathy



Holt-Oram syndrome	TBX5	Transcription factor	Congenital abnormalities, forelimb anomalies
Ulnar-mammary syndrome	TBX3	Transcription factor	Hypoplasia or absent ulna, 3rd–5th digits, breast, and teeth, delayed puberty
Cleidocranial dysplasia	CBFA1	Transcription factor	Abnormal clavicles, wormian bones, supernumerary teeth
<b><i>Defects in Extracellular Structural Proteins</i></b>			
Osteogenesis imperfecta types 1–4	COL1A1	Type 1 collagen	Bone fragility, hearing loss, blue sclerae
	COL1A2		Dentinogenesis imperfecta
Achondrogenesis II	COL2A1	Type 2 collagen	Short trunk, severely shortened extremities, relatively enlarged cranium, flattened face
Hypochondrogenesis	COL2A1		Short trunk, shortened extremities, relatively enlarged cranium, flattened face
Stickler syndrome	COL2A1	Type 2 collagen	Myopia, retinal detachment, hearing loss, flattened face, premature osteoarthritis
Multiple epiphyseal dysplasia	COL9A2	Type 9 collagen	Short or normal stature, small epiphyses, early onset osteoarthritis
Schmid metaphyseal chondrodysplasia	COL10A1	Type 10 collagen	Mild short stature, bowing of lower extremities, coxa vara, metaphyseal flaring
<b><i>Defects in Hormones and Signal Transduction Mechanisms Producing Abnormal Proliferation or Maturation of Chondrocytes and Osteoblasts</i></b>			
Brachydactyly type C	CDMP1	Signaling molecule	Shortened metacarpals and phalanges
Jansen metaphyseal chondroplasia	PTHrp receptor	Receptor	Short bowed limbs, clinodactyly, facial abnormalities, hypercalcemia, hypophosphatemia
Achondroplasia	FGFR3	Receptor	Short stature, rhizomelic shortening of limbs, frontal bossing, midface deficiency
Hypochondroplasia	FGFR3	Receptor	Disproportionate short stature, micromelia, relative macrocephaly
Thanatophoric dwarfism	FGFR3	Receptor	Severe limb shortening and bowing, frontal bossing, depressed nasal bridge
Crouzon syndrome	FGFR2	Receptor	Craniosynostosis
<i>Adapted from Mundlos S, Olsen BR: Heritable diseases of the skeleton. Part I: Molecular insights into skeletal development—transcription factors and signaling pathways. Faseb J 11:125–132, 1997; Mundlos S, Olsen BR: Heritable diseases of the skeleton. Part II: Molecular insights into skeletal development—matrix components and their homeostasis. Faseb J 11:227–233, 1997; Superti-Furga A, Bonafe L, Rimoin DL: Molecular-pathogenetic classification of genetic disorders of the skeleton. Am J Med Genet 106:282–293, 2001.</i>			

( Table 26-3 ). The *type II variant* is at one end of the spectrum and is uniformly fatal in utero or during the perinatal period. It is characterized by extraordinary bone fragility with multiple fractures occurring when the fetus is still within the womb ( Fig. 26-8 ). In contrast, the *type I form*, which is more often due to an acquired rather than an inherited mutation, permits a normal life span but with an increased number of fractures during childhood that decrease in frequency after puberty. Other findings include *blue sclerae* caused by a decrease in collagen content, making the sclera translucent and allowing partial visualization of the underlying choroid; *hearing loss* related to both a sensorineural deficit and impaired conduction owing to abnormalities in the bones of the middle and inner ear; and *dental imperfections* (small, misshapen, and blue-yellow teeth) secondary to a deficiency in dentin. In some variants, the skeleton fails to model properly, and there are persistent foci of hypercellular woven bone.<sup>[18]</sup> New and less well-characterized variants are still being identified. The recognition of particular variants and their modes of inheritance is important in genetic counseling.

#### **Types 2, 10, and 11 Collagen Diseases**

Types 2, 10, and 11 collagens are important structural components of hyaline cartilage. Mutations that result in their abnormal metabolism, although uncommon, produce a spectrum of

disorders ranging from those that are fatal to those compatible with life but associated with early destruction of joints (see Table 26-2 ). More than 30 mutations have been identified in the type 2 collagen gene, and all have affected the triple helical component of the molecule. In severe disorders, the type 2 collagen molecules are not secreted by the chondrocytes, and insufficient bone formation occurs. In the milder phenotypes, a nonfunctioning or null collagen gene

TABLE 26-3 -- Osteogenesis Imperfecta

	Subtype	Inheritance	Collagen Defect	Major Clinical Features
OI I	Postnatal fractures, blue sclerae	Autosomal dominant	Decreased synthesis pro- $\alpha$ 1(1) chain	Compatible with survival
			Abnormal pro- $\alpha$ 1(1) or pro- $\alpha$ 2(1) chains	Normal stature
				Skeletal fragility
				Dentinogenesis imperfecta
				Hearing impairment
				Joint laxity
				Blue sclerae
OI II	Perinatal lethal	Most autosomal recessive	Abnormally short pro- $\alpha$ 1(1) chain	Death in utero or within days of birth
		Some autosomal dominant	Unstable triple helix	Skeletal deformity with excessive fragility and multiple fractures
		?New mutations	Abnormal or insufficient pro- $\alpha$ 2(1)	Blue sclerae
OI III	Progressive deforming	Autosomal dominant (75%)	Altered structure of pro-peptides of pro- $\alpha$ 2(1)	Compatible with survival
		Autosomal recessive (25%)	Impaired formation of triple helix	Growth retardation
				Multiple fractures
				Progressive kyphoscoliosis
				Blue sclerae at birth that become white
				Hearing impairment
				Dentinogenesis imperfecta
OI IV	Postnatal fractures, normal sclerae	Autosomal dominant	Short pro- $\alpha$ 2(1) chain	Compatible with survival
			Unstable triple helix	Moderate skeletal fragility

				Short stature
				Sometimes dentinogenesis imperfecta

OI, osteogenesis imperfecta.

allele is formed, leading to a reduced content of type 2 collagen in the cartilage. [12]

DISEASES ASSOCIATED WITH DEFECTS IN FOLDING AND DEGRADATION OF MACROMOLECULES

Mucopolysaccharidoses

The mucopolysaccharidoses, as discussed in Chapter 5 , are a group of lysosomal storage diseases caused by deficiencies in the enzymes that degrade dermatan sulfate, heparan sulfate, and keratan sulfate. The implicated enzymes are mainly acid hydrolases. Mesenchymal cells, especially chondrocytes, play an important role in the metabolism of extracellular matrix mucopolysaccharides and therefore are most severely affected. Consequently, many of the skeletal manifestations of the mucopolysaccharidoses result from abnormalities in hyaline cartilage, including the cartilage anlage, growth plates, costal cartilages, and articular surfaces. It is not surprising therefore that patients with mucopolysaccharidoses are frequently of short stature and have chest wall abnormalities and malformed bones.

DISEASES ASSOCIATED WITH DEFECTS IN METABOLIC PATHWAYS (ENZYMES, ION CHANNELS, AND TRANSPORTERS)

Osteopetrosis

*Osteopetrosis* refers to a group of rare genetic diseases that are characterized by reduced osteoclast bone resorption, resulting in diffuse symmetric skeletal sclerosis ( Fig. 26-9 ). The term *osteopetrosis* was coined because of the stonelike quality of the bones; however, the bones are abnormally brittle and fracture like a piece of chalk. Osteopetrosis, which is also known as *marble bone disease* and *Albers-Schönberg disease*, is classified into variants based on both the mode of inheritance and the clinical findings. The autosomal recessive malignant type and the autosomal dominant benign type are the most common variants.

Pathogenesis.

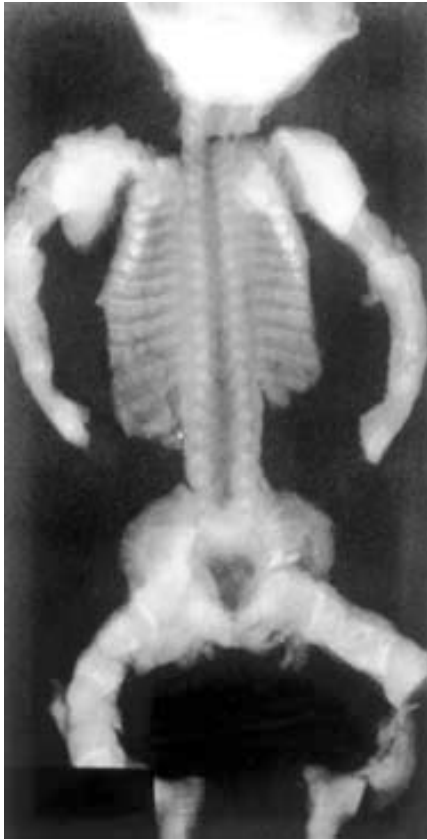Four types of osteopetrosis have been identified: infantile malignant osteopetrosis, type II carbonic anhydrase deficiency, and autosomal-dominant types I and II. However, the precise nature of the osteoclast dysfunction in many cases remains unknown. An example of a form of the disease in which the molecular mechanism is understood is the variant associated with *carbonic anhydrase II* deficiency.[19] Carbonic anhydrase II is required by osteoclasts and renal tubular cells to excrete hydrogen ions and acidify their environment. The absence of this enzyme prevents osteoclasts from acidifying the resorption pit and solubilizing the hydroxyapatite crystals and also blocks the acidification of urine by renal tubular cells. In another form of the disease, a mutation in the *CLIC-7* chloride channel gene causes osteoclast dysfunction by interfering with the chloride channel that is important in the proton pump of the H<sup>+</sup> - ATPase located on the osteoclast ruffled border. Consequently, osteoclasts cannot acidify the resorption pit, thus preventing the digestion of bone.[20] In mice, osteopetrosis can also be caused by targeted mutations in the genes coding for M-CSF, *c-src*, RANK, and OPG.[19] It is possible that some of these genes will be linked to the human disease.

Morphology.

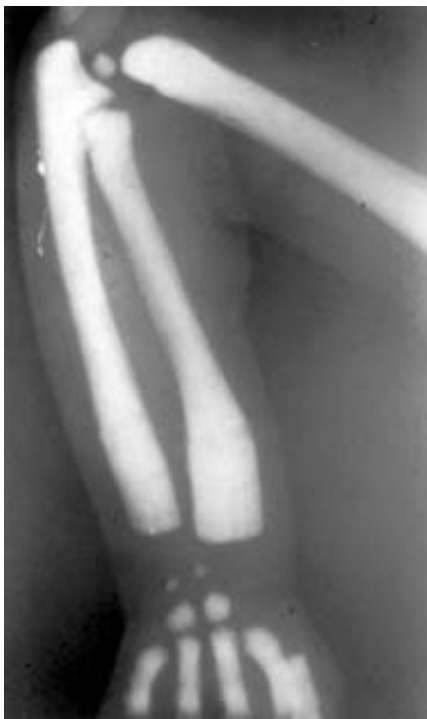The morphologic changes of osteopetrosis are explained by deficient osteoclast activity. Grossly the bones lack a medullary canal, and the



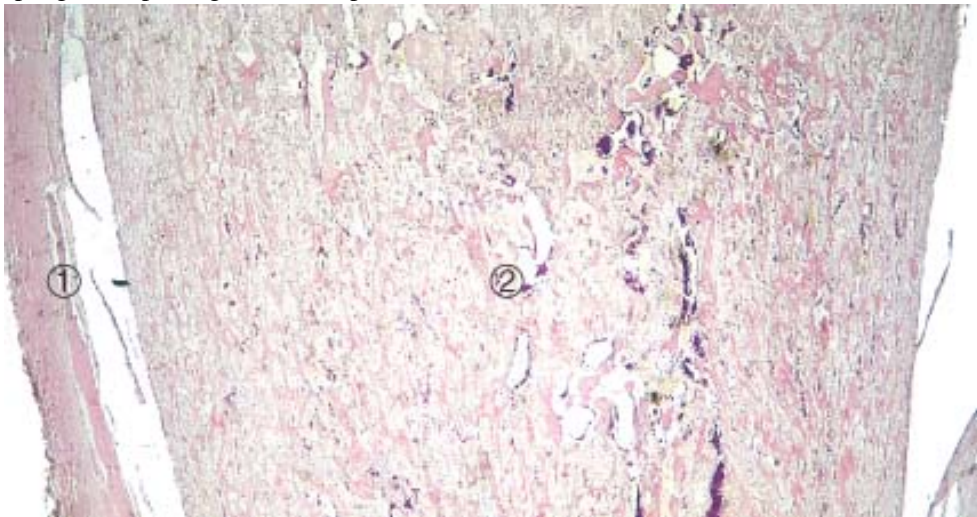
**Figure 26-8** Skeletal radiograph of a fetus with lethal type II osteogenesis imperfecta. Note the numerous fractures of virtually all bones, resulting in accordion-like shortening of the limbs.



**Figure 26-9** Radiograph of the upper extremity in a patient with osteopetrosis. The bones are diffusely sclerotic, and the distal metaphyses of the ulna and radius are poorly formed (Erlenmeyer flask deformity).



**Figure 26-10** Section of proximal tibial diaphysis from a fetus with osteopetrosis. The cortex (1) is being formed, and the medullary cavity (2) is abnormally filled with primary spongiosa replacing the hematopoietic elements.



**TABLE 26-4** -- Categories of Generalized Osteoporosis

<i>Primary</i>	
Postmenopausal	••Idiopathic

Senile	
<i>Secondary</i>	
<b>Endocrine disorders</b>	<b>Rheumatologic disease</b>
••Hyperparathyroidism	<b>Drugs</b>
••Hypo-hyperthyroidism	••Anticoagulants
••Hypogonadism	••Chemotherapy
••Pituitary tumors	••Corticosteroids
••Diabetes, type 1	••Anticonvulsants
••Addison disease	••Alcohol
<b>Neoplasia</b>	<b>Miscellaneous</b>
••Multiple myeloma	••Osteogenesis imperfecta
••Carcinomatosis	••Immobilization
<b>Gastrointestinal</b>	••Pulmonary disease
••Malnutrition	••Homocystinuria
••Malabsorption	••Anemia
••Hepatic insufficiency	
••Vitamin C, D deficiencies	

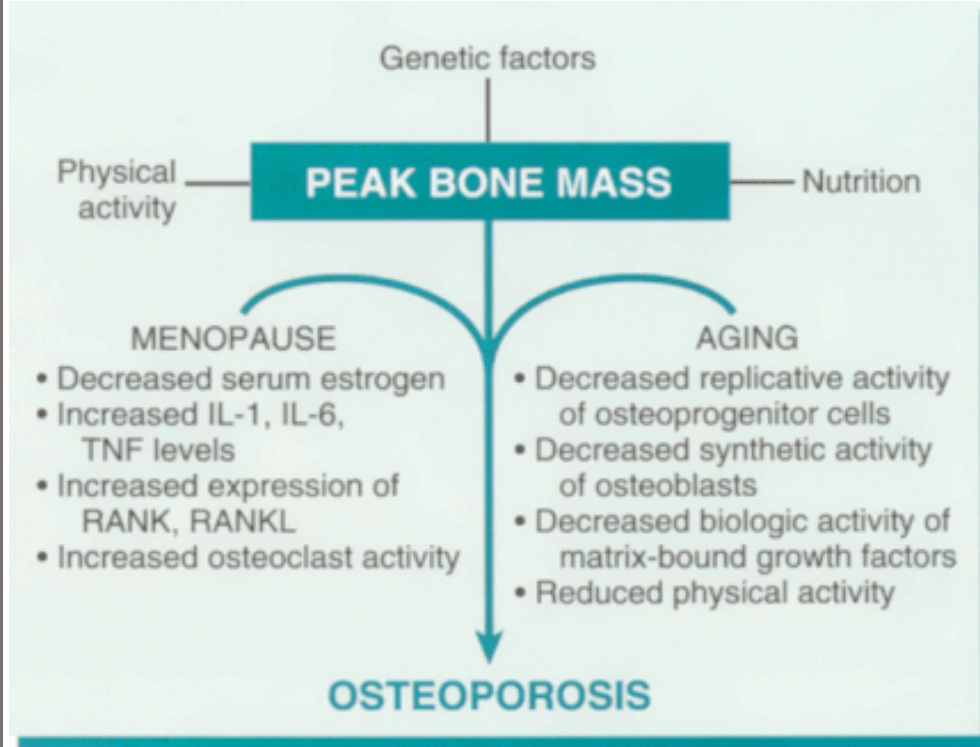
new hypotheses in the pathogenesis of osteoporosis ( Fig. 26-11 ):

- *Age-related changes* in bone cells and matrix have a strong impact on bone metabolism. Osteoblasts from elderly individuals have reduced replicative and biosynthetic potential when compared with osteoblasts from younger individuals.<sup>[22]</sup> Also, proteins bound to the extracellular matrix (such as growth factors, which are mitogenic to osteoprogenitor cells and stimulate osteoblastic synthetic activity) lose their biologic potency over time. The end result is a skeleton populated by bone-forming cells that have a diminished capacity to make bone. This form of osteoporosis, also known as *senile osteoporosis*, is categorized as a *low turnover variant*.
- *Reduced physical activity* increases the rate of bone loss in experimental animals and humans because mechanical forces are important stimuli for normal bone remodeling. The bone loss seen in an immobilized or paralyzed extremity, the reduction of skeletal mass observed in astronauts subjected to a gravity-free environment for prolonged periods, and the higher bone density in athletes as compared with nonathletes all support a role for physical activity in preventing bone loss. The type of exercise is important because load magnitude influences bone density more than the number of load cycles. Because muscle contraction is the dominant source of skeletal loading, it is logical that resistance exercises such as weight training are more effective stimuli for increasing bone mass than repetitive endurance activities such as jogging. Certainly the decreased physical activity that is associated with aging contributes to senile osteoporosis.
- *Genetic factors are also important*, as noted previously. The type of vitamin D receptor molecule that is inherited accounts for approximately 75% of the maximal peak mass achieved. Polymorphism in the vitamin D receptor molecule is associated with either a higher or lower maximal bone mass. Calcium deficiency, increased PTH levels, and reduced levels of vitamin D also may play a role in the development of senile osteoporosis.

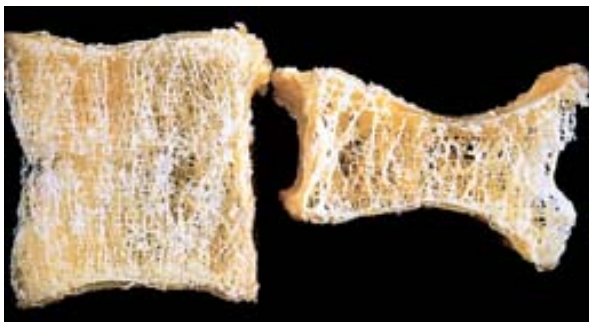


- The body's calcium *nutritional state* is important. It has been shown that adolescent girls (but not boys) have insufficient calcium intake in the diet. This calcium deficiency occurs during a period of rapid bone growth, stunting the peak bone mass ultimately achieved; thus, these individuals are at greater risk of developing osteoporosis.
- *Hormonal influences.* In the decade after menopause, yearly reductions in bone mass may reach up to 2% of cortical bone and 9% of cancellous bone. Women may lose as much as 35% of their cortical bone and 50% of their trabecular bone within the 30 to 40 years after menopause. It is thus no surprise that 1 out of every 2 women suffers an osteoporotic fracture, in contrast to 1 in 40 men. *Postmenopausal osteoporosis* is characterized by a hormone-dependent acceleration of bone loss that occurs during the decade after menopause. *Estrogen deficiency plays the major role in this phenomenon, and estrogen replacement at menopause is protective against bone loss.* The effects of estrogen on bone mass are mediated by cytokines. Decreased estrogen levels result in increased secretion of IL-1, IL-6, and TNF by blood monocytes and bone marrow cells.<sup>[23]</sup> These cytokines are potent stimulators of osteoclast recruitment and activity; they act, in part, by increasing the levels of RANK and RANKL and diminishing the quantity of OPG. Compensatory osteoblastic activity occurs, but it does not keep pace, leading to what is classified as a *high turnover form* of osteoporosis.

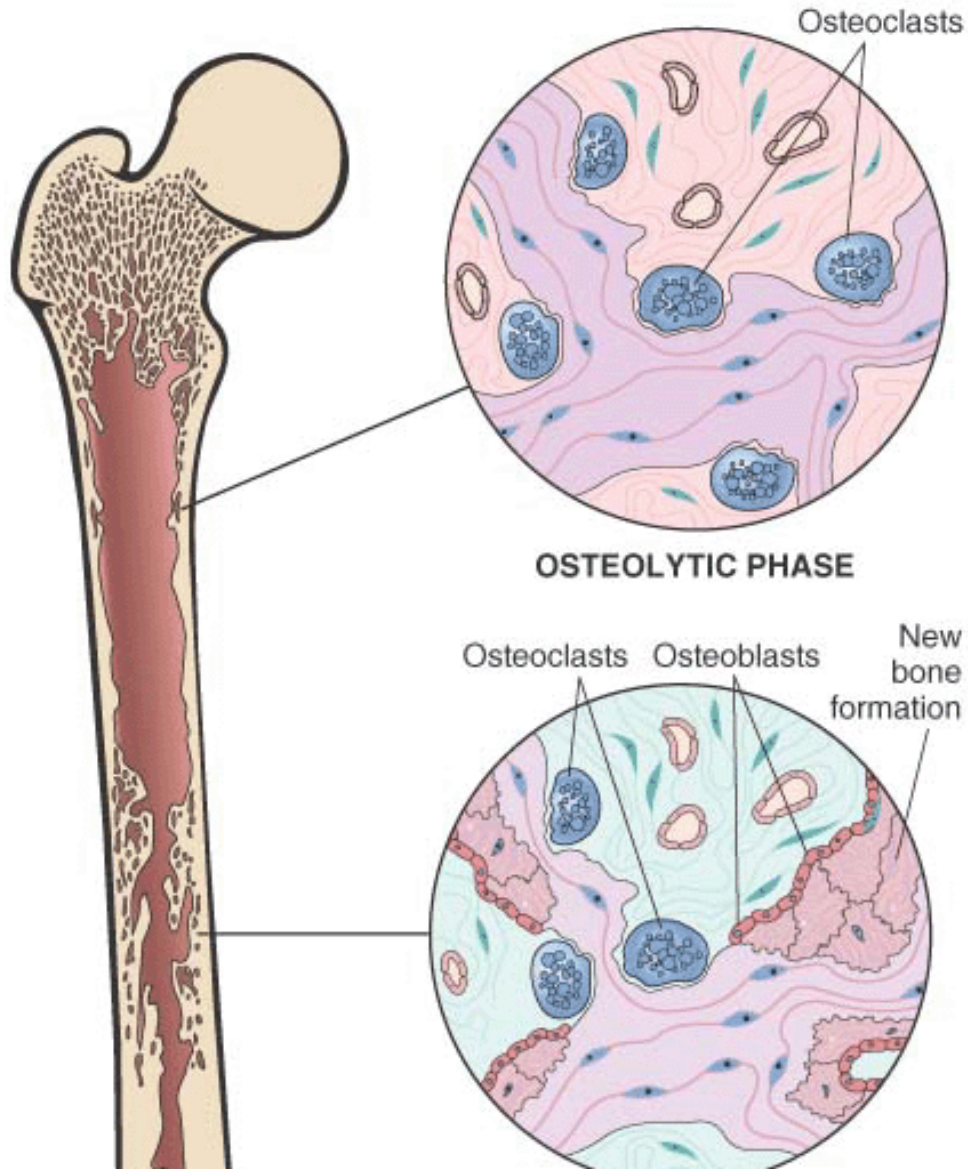
**Figure 26-11** Pathophysiology of postmenopausal and senile osteoporosis (see text).

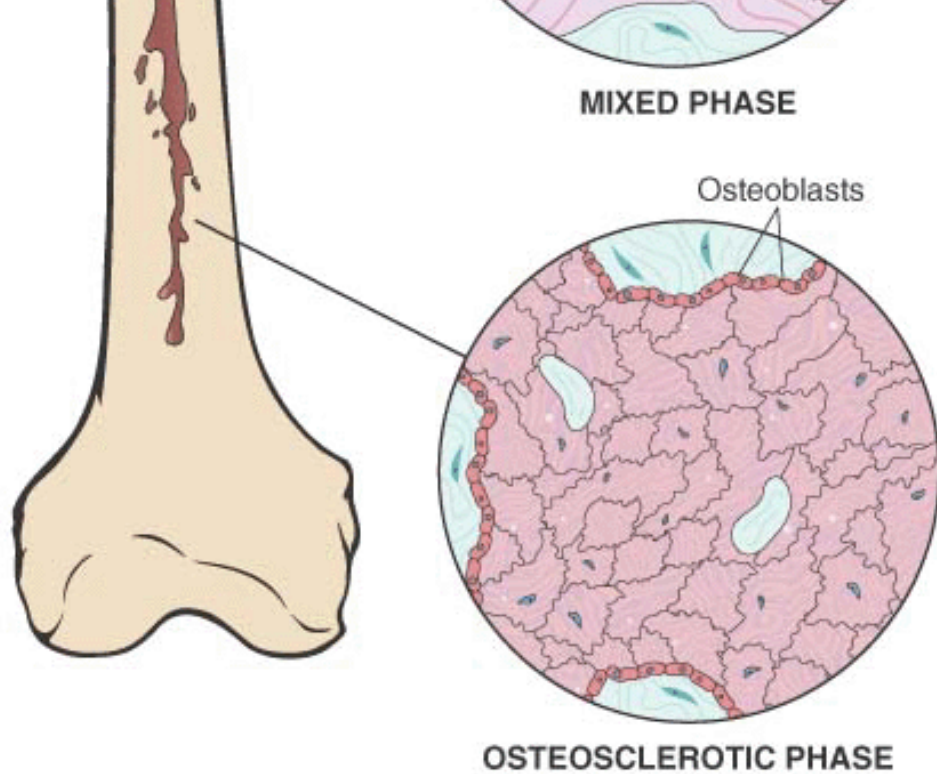


**Figure 26-12** Osteoporotic vertebral body (*right*) shortened by compression fractures, compared with a normal vertebral body. Note that the osteoporotic vertebra has a characteristic loss of horizontal trabeculae and thickened vertical trabeculae.

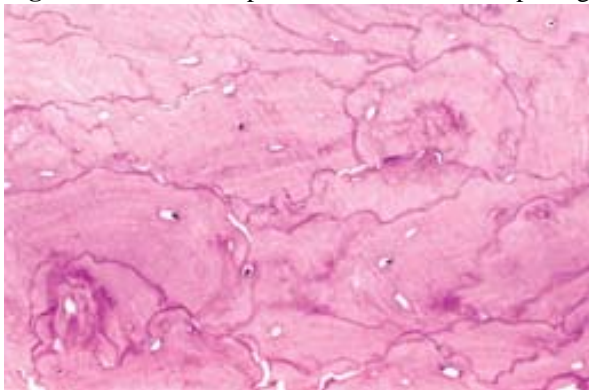


**Figure 26-13** Diagrammatic representation of Paget disease of bone, demonstrating the three phases in the evolution of the disease.



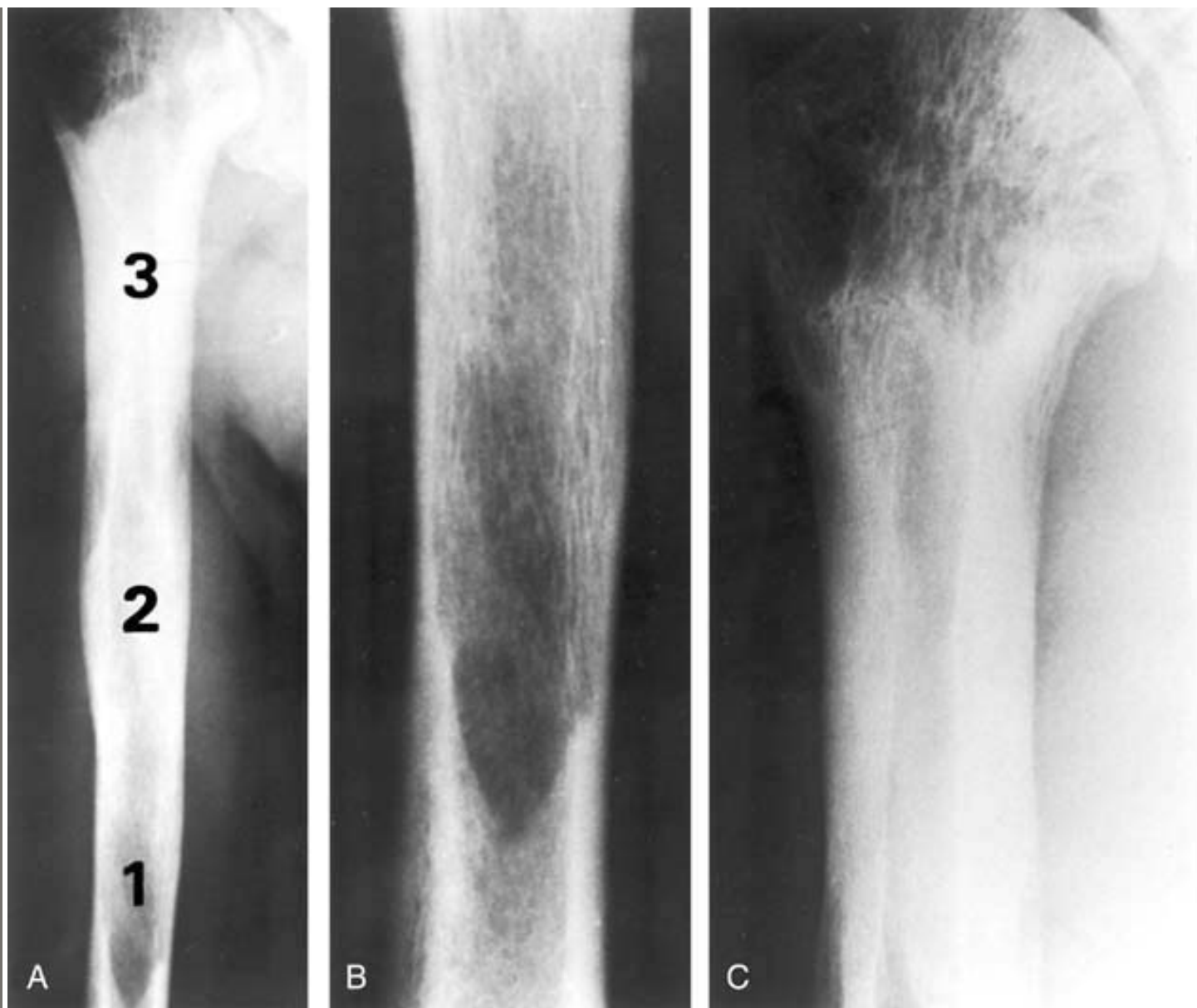

**Figure 26-14** Mosaic pattern of lamellar bone pathognomonic of Paget disease.

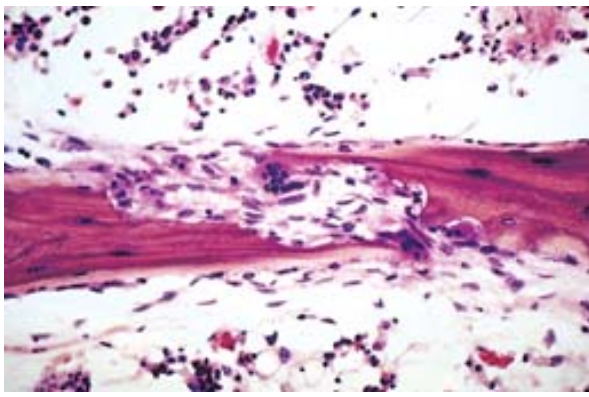


**Figure 26-15** Paget disease of the humerus. *A*, The three sequential stages: (1) lytic, (2) mixed, and (3) sclerotic. *B*, Area 1, the lytic stage, is seen in close-up. Area 2, the mixed stage (upper portion of *B*) reveals central and endosteal cortical resorption and replacement by less compact new bone. *C*, Area 3, the sclerotic stage, with irregular thickening of both cortical and trabecular bone. (From Maldague B, Malghem J: *Dynamic radiologic pattern of Paget's disease of bone*. Clin Orthop 217:127, 1987.)

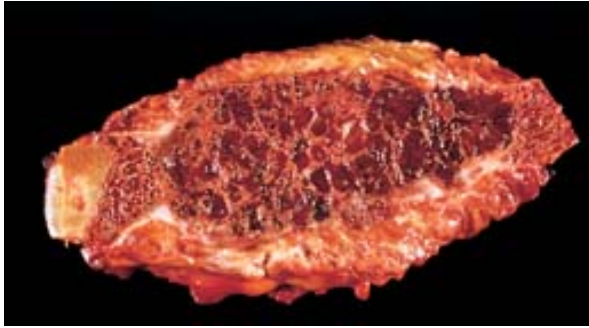



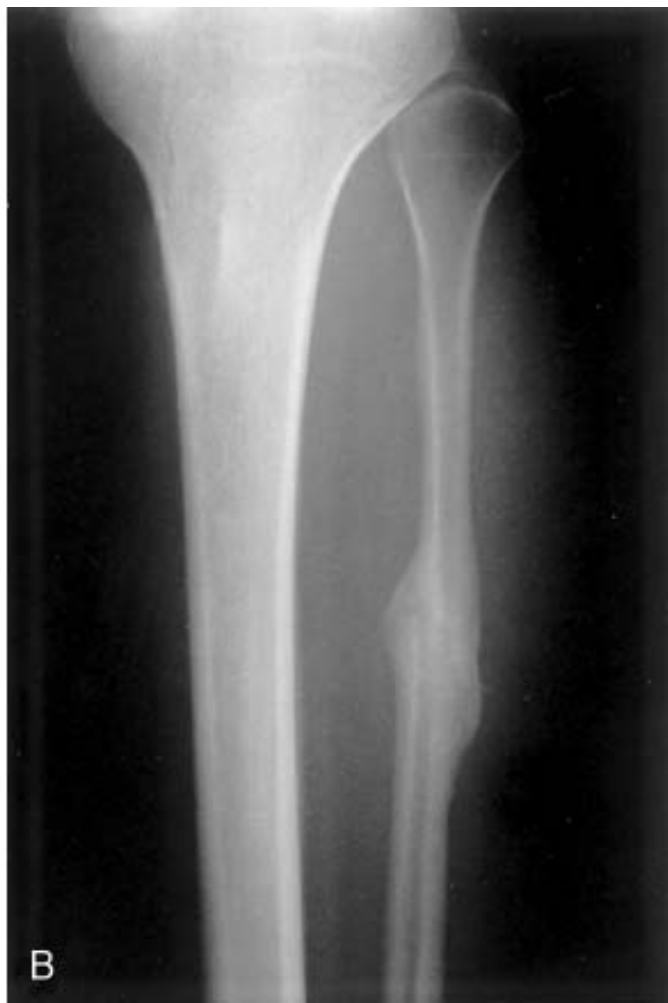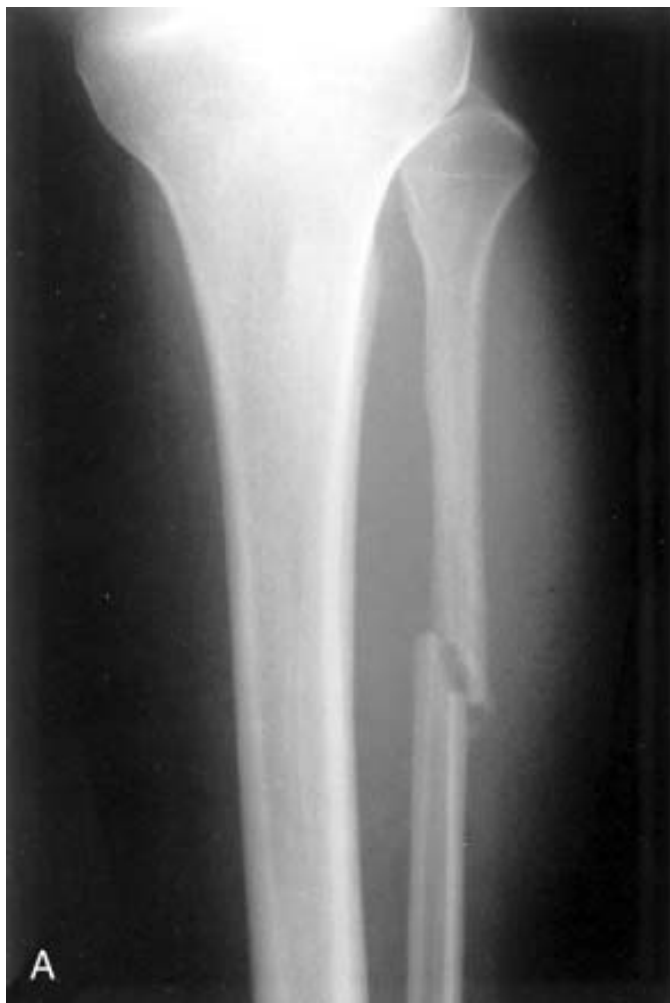**Figure 26-16** Hyperparathyroidism with osteoclasts boring into the center of the trabeculum (dissecting osteitis).



**Figure 26-17** Resected rib, harboring an expansile brown tumor adjacent to the costal cartilage.



**Figure 26-18** A, Recent fracture of the fibula. B, Marked callus formation 6 weeks later. (*Courtesy of Dr. Barbara Weissman, Brigham and Women's Hospital, Boston, MA.*)



**TABLE 26-5** -- Disorders Associated with Osteonecrosis

Idiopathic	Pregnancy
Trauma	Gaucher disease
Corticosteroid administration	Sickle cell and other anemias
Infection	Alcohol abuse
Dysbarism	Chronic pancreatitis
Radiation therapy	Tumors
Connective tissue disorders	Epiphyseal disorders



pathophysiology underlying steroid-induced bone infarcts is obscure. The infarcts follow high-dose steroid therapy for short periods, long-term administration of smaller doses, and even intra-articular injections.

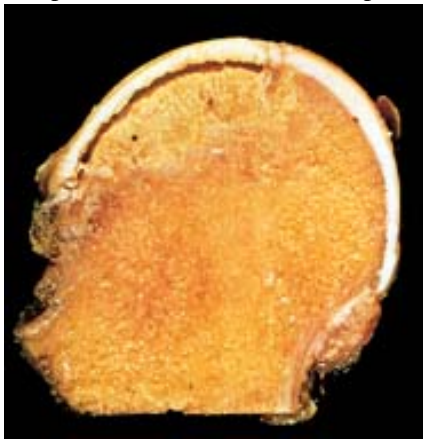#### **Morphology.**

The pathologic features of bone necrosis are the same regardless of the cause. In medullary infarcts, the necrosis is geographic and involves the cancellous bone and marrow. The cortex is usually not affected because of its collateral blood flow. In subchondral infarcts, necrosis involves a triangular or wedge-shaped segment of tissue that has the subchondral bone plate as its base and the center of the epiphysis as its apex. The overlying articular cartilage remains viable because it receives nutrition from the synovial fluid. The dead bone, recognized by its empty lacunae, is surrounded by necrotic adipocytes that frequently rupture, releasing their fatty acids, which bind calcium and form insoluble calcium soaps that may remain for life. In the healing response, osteoclasts resorb the necrotic trabeculae; however, those that remain act as scaffolding for the deposition of new living bone in a process known as **creeping substitution**. In subchondral infarcts, the pace of creeping substitution is too slow to be effective so there is eventual collapse of the necrotic cancellous bone and distortion, fracture, and even sloughing of the articular cartilage ( Fig. 26-19 ).

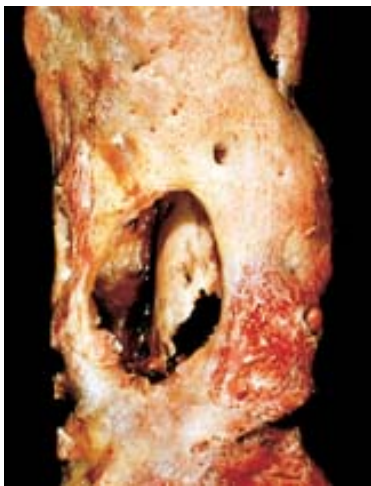#### **Clinical Course.**

The symptoms depend on the location and extent of infarction. Typically, subchondral infarcts cause chronic pain that is initially associated only with physical activity but then becomes progressively more constant as secondary changes supervene. In contrast, medullary infarcts are clinically silent except for large ones occurring in Gaucher disease, dysbarism, and hemoglobinopathies. Medullary infarcts usually remain stable over time and rarely are the site of malignant transformation. Subchondral infarcts, however, often collapse and may predispose to severe, secondary

**Figure 26-19** Femoral head with a subchondral, wedge-shaped pale yellow area of osteonecrosis. The space between the overlying articular cartilage and bone is caused by trabecular compression fractures without repair.



**Figure 26-20** Resected femur in a patient with draining osteomyelitis. The drainage tract in the subperiosteal shell of viable new bone (involucrum) reveals the inner native necrotic cortex (sequestrum).



**TABLE 26-6 -- Classification of Primary Tumors Involving Bones**

Histologic Type	Benign	Malignant
Hematopoietic (40%)		Myeloma
		Malignant lymphoma
Chondrogenic (22%)	Osteochondroma	Chondrosarcoma
	Chondroma	Dedifferentiated chondrosarcoma
	Chondroblastoma	Mesenchymal chondrosarcoma
	Chondromyxoid fibroma	
Osteogenic (19%)	Osteoid osteoma	Osteosarcoma
	Osteoblastoma	
Unknown origin (10%)	Giant cell tumor	Ewing tumor
		Giant cell tumor
		Adamantinoma
Histiocytic origin	Fibrous histiocytoma	Malignant fibrous histiocytoma
Fibrogenic	Metaphyseal fibrous defect (fibroma)	Desmoplastic fibroma
		Fibrosarcoma
Notochordal		Chordoma
Vascular	Hemangioma	Hemangioendothelioma
		Hemangiopericytoma

Lipogenic	Lipoma	Liposarcoma
Neurogenic	Neurilemmoma	

*Data on percentage of each type from Unni KK: Dahlin's Bone Tumors, 5th ed. Philadelphia, Lippincott-Raven, 1996, p 4; by permission of Mayo Foundation.*

acquired syphilis. Gummata also occur in the acquired disease. The spirochetes can be demonstrated in the inflammatory tissue with special silver stains.

### Bone Tumors and Tumor-Like Lesions

Bone tumors are diverse in their gross and morphologic features and range in their biologic potential from the innocuous to the rapidly fatal. This diversity makes it critical to accurately diagnose and stage tumors, and treat them appropriately, so that the patients can not only survive, but also maintain optimal function of the affected body parts.

Most bone tumors are classified according to the normal cell or tissue of origin. Lesions that do not have normal tissue counterparts are grouped according to their distinct clinicopathologic features ( Table 26-6 ). Overall, matrix-producing and fibrous tumors are the most common, and among the benign tumors, osteochondroma and fibrous cortical defect are most frequent. Excluding malignant neoplasms of marrow origin (myeloma, lymphoma, and leukemia), osteosarcoma is the most common primary cancer of bone, followed by chondrosarcoma and Ewing sarcoma.

The precise incidence of different bone tumors is not known because many benign lesions are not biopsied. Benign tumors outnumber their malignant counterparts, however, by at least several hundredfold. Benign tumors have their greatest frequency within the first three decades of life, whereas in the elderly a bone tumor is likely to be malignant. In the United States, about 2,100 new cases of bone sarcoma are

diagnosed annually, and approximately 1,300 deaths from bone sarcoma occur each year.

As a group these neoplasms affect all ages and arise in virtually every bone, but most develop during the first several decades of life and have a propensity to originate in the long bones of the extremities. However, specific types of tumors target certain age groups and anatomic sites.<sup>[32]</sup> For instance, most osteosarcomas occur during adolescence, and about half of them arise in the metaphysis around the knee, either in the distal femur or proximal tibia. These are the sites of greatest skeletal growth activity. In contrast, chondrosarcomas tend to develop during mid- to late adulthood and frequently involve the trunk, limb girdles, and proximal long bones. Chondro-blastomas and giant cell tumors almost always arise in the epiphysis of long bones; by comparison, Ewing sarcoma, osteofibrous dysplasia, and adamantinoma most often are centered in the diaphysis. Thus, the location of a tumor provides important diagnostic information.

Although the cause of most bone tumors is unknown, genetic alterations similar to those that occur in other tumors clearly play a role. For instance, bone sarcomas occur in the Li-Fraumeni and hereditary retinoblastoma cancer syndromes, which are linked to mutations in *p53* and *RB* ( Chapter 7 ). Bone infarcts, chronic osteomyelitis, Paget disease, radiation, and metal prostheses are also associated with an increased incidence of bone neoplasia. Such secondary neoplasms, however, account for only a small fraction of all skeletal tumors.

Clinically, bone tumors present in various ways. The more common benign lesions are frequently asymptomatic and are detected as incidental findings. Many tumors, however, produce pain or are noticed as a slow-growing mass. Sometimes, the first hint of a tumor's presence is a sudden pathologic fracture. Radiographic analysis plays an important role in diagnosing these lesions. In addition to providing the exact location and extent of the tumor, imaging studies can detect features that help limit diagnostic possibilities and give clues to the aggressiveness of the tumor. Ultimately, in most instances, biopsy and histologic study are necessary. In addition to classifying the tumor, histologic grade must also be determined in



most primary malignancies. *The histologic grade has been shown to be the most important prognostic feature of a bone sarcoma* and is a key component of the major staging systems of bone neoplasms.

## BONE-FORMING TUMORS

Common to all these neoplasms is the production of bone by the neoplastic cells. The tumor bone is usually deposited as woven trabeculae (except in osteomas) and is variably mineralized.

### Osteoma

Osteomas are bosselated, round to oval sessile tumors that project from the subperiosteal or endosteal surfaces of the cortex. Subperiosteal osteomas most often arise on or inside the skull and facial bones. They are usually solitary and are detected in middle-aged adults. Multiple osteomas are seen in the setting of *Gardner syndrome* ( Chapter 17 ). They are composed of woven and lamellar bone that is frequently deposited in a cortical pattern with haversian-like systems. Some variants contain a component of trabecular bone in which the intertrabecular spaces are filled with hematopoietic marrow. Histologically the reactive bone induced by infection, trauma, or hemangiomas may simulate an osteoma and should be considered in the differential diagnosis.

Osteomas are generally slow-growing tumors of little clinical significance except when they cause obstruction of a sinus cavity, impinge on the brain or eye, interfere with function of the oral cavity, or produce cosmetic problems. Osteomas do not transform into osteosarcoma.

### Osteoid Osteoma and Osteoblastoma

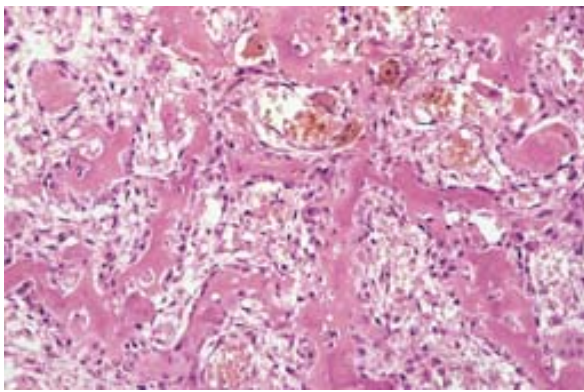
*Osteoid osteoma* and *osteoblastoma* are terms used to describe benign bone tumors that have identical histologic features but that differ in size, sites of origin, and symptoms. *Osteoid osteomas* are, by definition, less than 2 cm in greatest dimension and usually occur in patients in their teens and twenties. Seventy-five per cent of patients are under age 25, and men outnumber women 2:1. Osteoid osteomas can arise in any bone but have a predilection for the appendicular skeleton. Fifty percent of cases involve the femur or tibia, where they commonly arise in the cortex and less frequently within the medullary cavity. Osteoid osteomas are painful lesions. The pain, which is caused by excess prostaglandin E<sub>2</sub> produced by

the proliferating osteoblasts, is severe in relation to the small size of the lesion, is characteristically nocturnal, and is dramatically relieved by aspirin.<sup>[33]</sup> *Osteoblastoma* differs from osteoid osteoma in that it more frequently involves the spine; the pain is dull, achy, and not responsive to salicylates; and it does not induce a marked bony reaction.

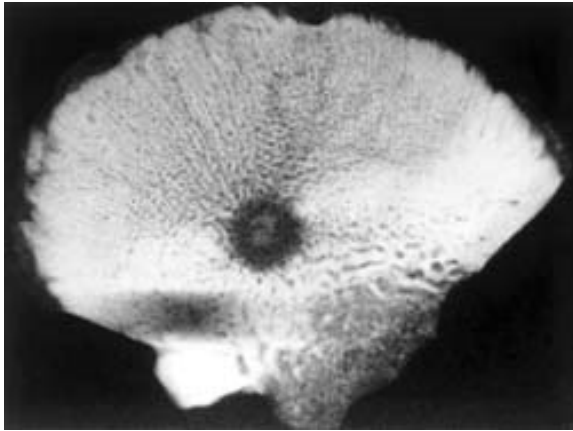
### Morphology.

Grossly, both osteoid osteoma and osteoblastoma are round to oval masses of hemorrhagic gritty tan tissue. Histologically, they are well circumscribed and composed of a morass of randomly interconnecting trabeculae of woven bone prominently rimmed by osteoblasts ( Fig. 26-21 ). The stroma surrounding the tumor bone consists of loose connective tissue that contains many dilated and congested capillaries. The relatively small size and well-defined margins of these tumors in combination

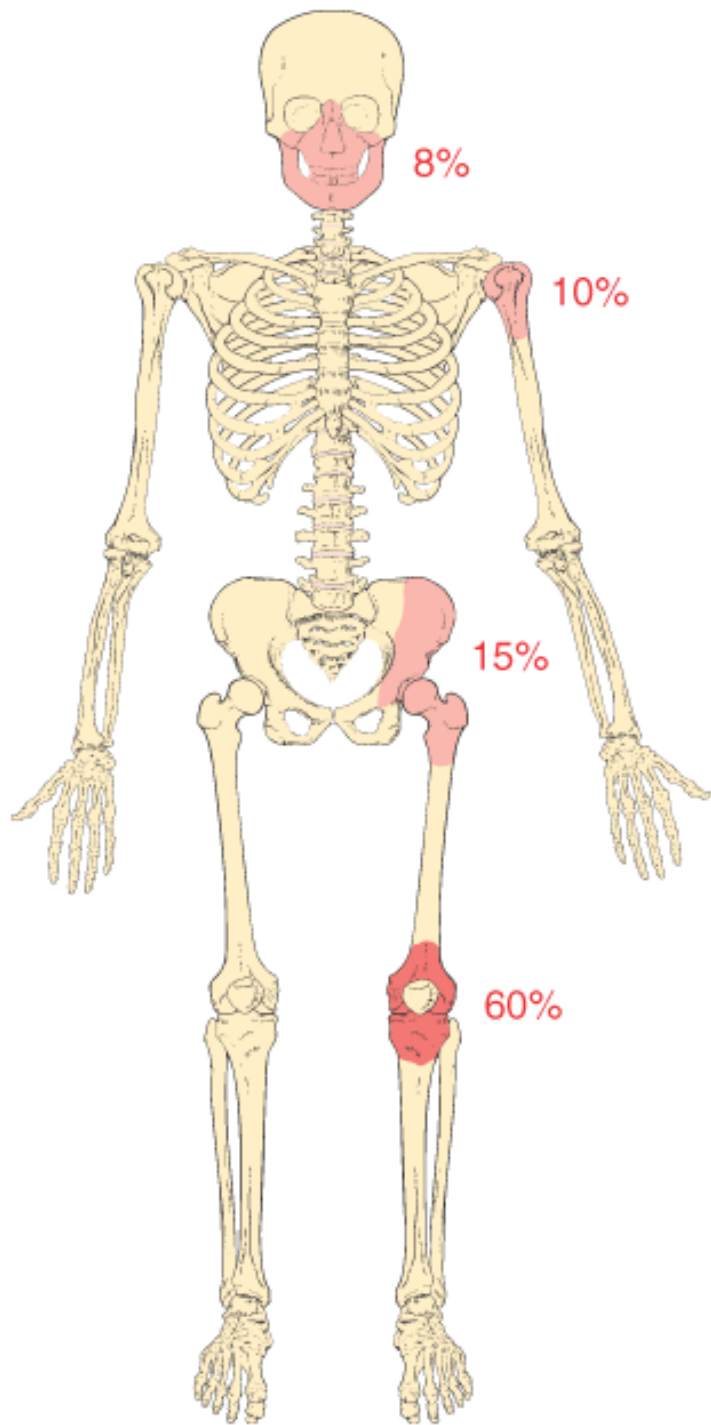
**Figure 26-21** Osteoid osteoma composed of haphazardly interconnecting trabeculae of woven bone that are rimmed by prominent osteoblasts. The intertrabecular spaces are filled by vascular loose connective tissue.



**Figure 26-22** Specimen radiograph of intracortical osteoid osteoma. The round radiolucency with central mineralization represents the lesion and is surrounded by abundant reactive bone that has massively thickened the cortex.

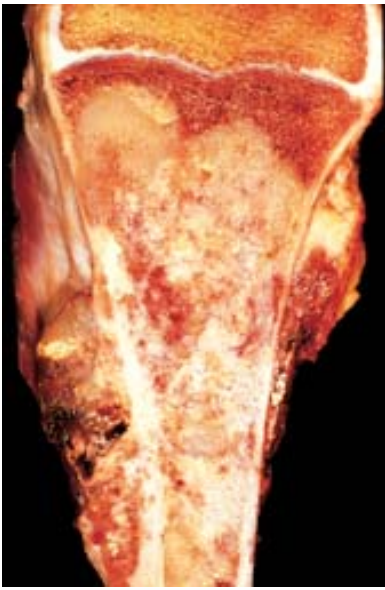

**Figure 26-23** Major sites of origin of osteosarcomas. The numbers are approximate percentages.

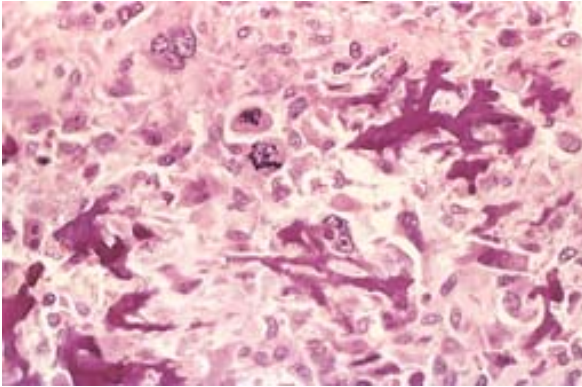


**Figure 26-24** Osteosarcoma of the upper end of the tibia. The tan-white tumor fills most of the medullary cavity of the metaphysis and proximal diaphysis. It has infiltrated through the cortex, lifted the periosteum, and formed soft tissue masses on both sides of the bone.

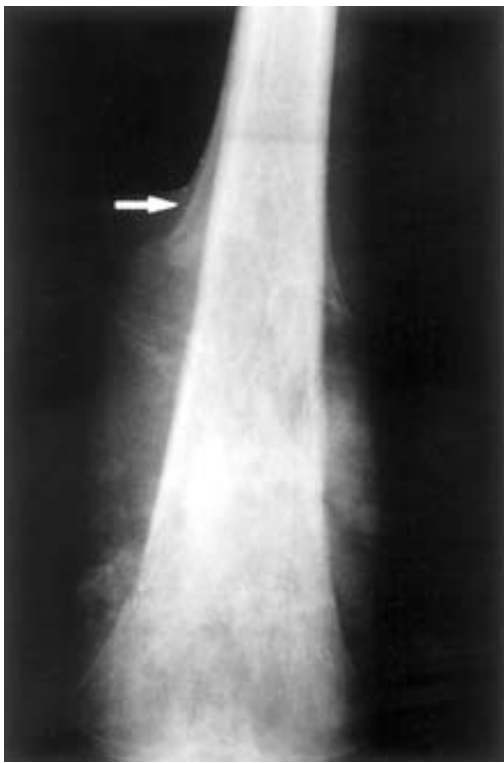



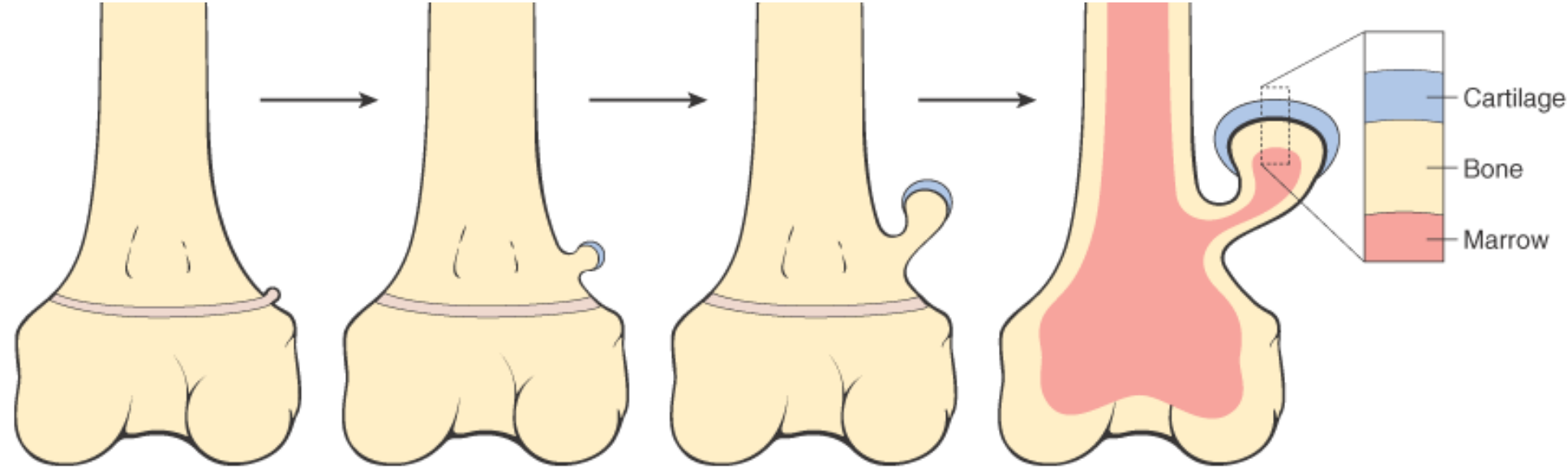
**Figure 26-25** Osteosarcoma. Coarse, lacelike pattern of neoplastic bone produced by anaplastic malignant tumor cells. Note the mitotic figures.



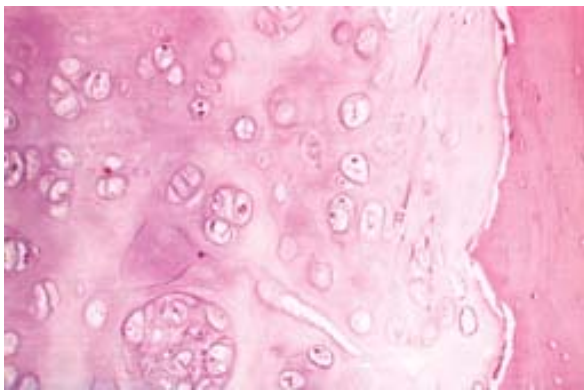
**Figure 26-26** Distal femoral osteosarcoma with prominent bone formation extending into the soft tissues. The periosteum, which has been lifted, has laid down a proximal triangular shell of reactive bone known as a Codman triangle (*arrow*).



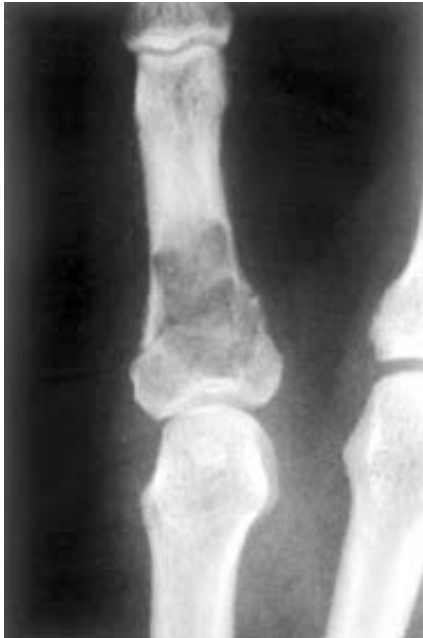**Figure 26-27** Schematic of the development over time of an osteochondroma, beginning with an outgrowth from the epiphyseal cartilage.



**Figure 26-28** Enchondroma with a nodule of hyaline cartilage encased by a thin layer of reactive bone.

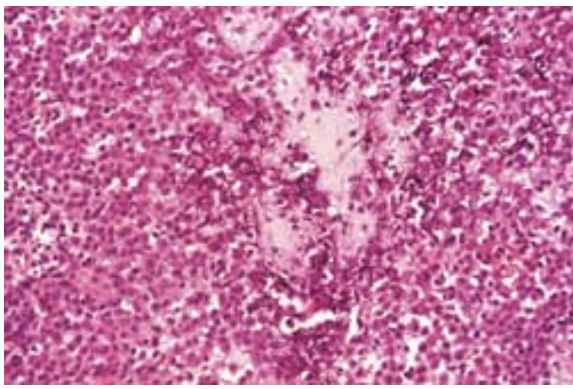


**Figure 26-29** Enchondroma of the phalanx with a pathologic fracture. The radiolucent nodules of hyaline cartilage scallop the endosteal surface.

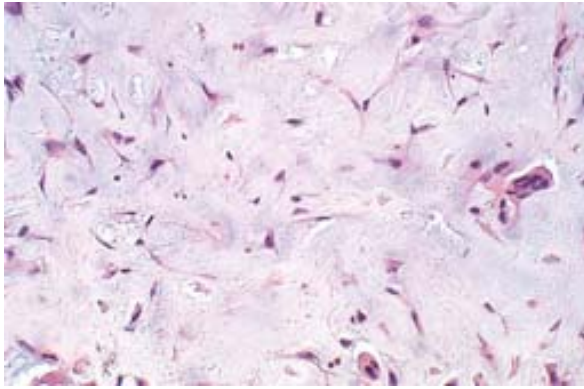


**Figure 26-30** Chondroblastoma with scant mineralized matrix surrounding chondroblasts in a chicken wire-like fashion.

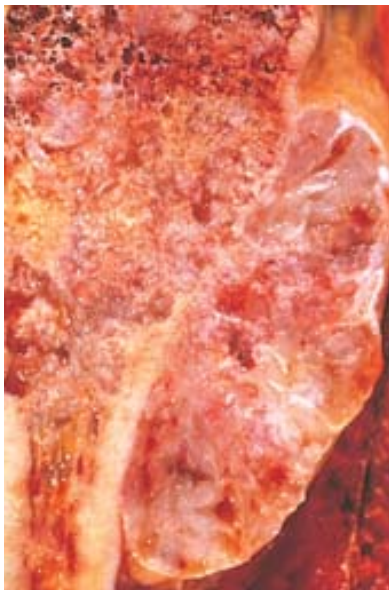



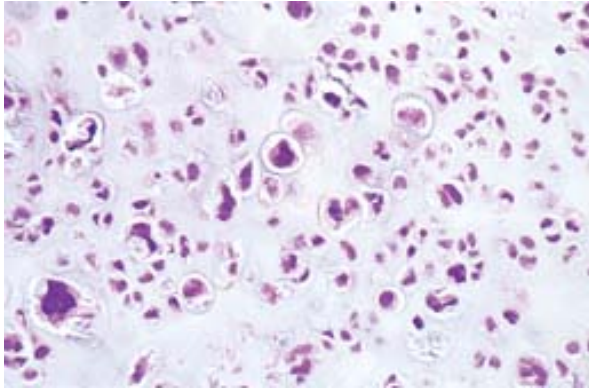
**Figure 26-31** Chondromyxoid fibroma with prominent stellate and spindle cells surrounded by myxoid matrix. Occasional osteoclast-type giant cells are also present.



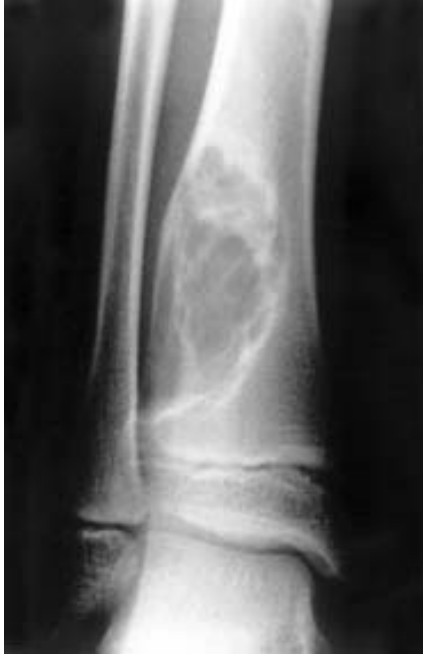**Figure 26-32** Chondrosarcoma with lobules of hyaline and myxoid cartilage permeating throughout the medullary cavity, growing through the cortex, and forming a relatively well-circumscribed soft tissue mass.



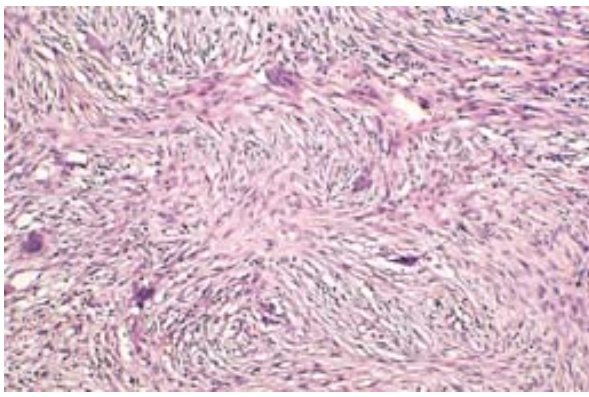
**Figure 26-33** Anaplastic chondrocytes within a chondrosarcoma.



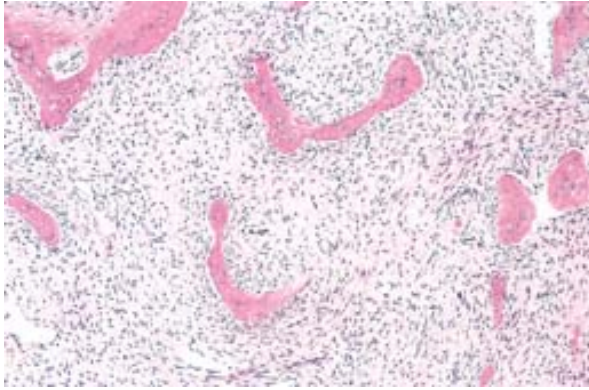
**Figure 26-34** Nonossifying fibromas of the distal tibial metaphysis, producing an eccentric lobulated radiolucency surrounded by a sclerotic margin.



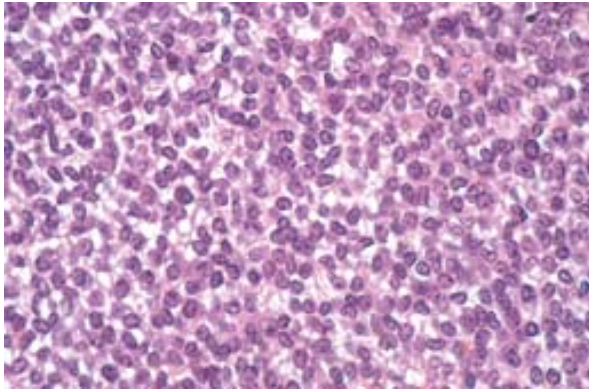
**Figure 26-35** Storiform pattern created by benign spindle cells with scattered osteoclast-type giant cells characteristic of a fibrous cortical defect and nonossifying fibroma.



**Figure 26-36** Fibrous dysplasia composed of curvilinear trabeculae of woven bone that lack conspicuous osteoblastic rimming and arise in a background of fibrous tissue.

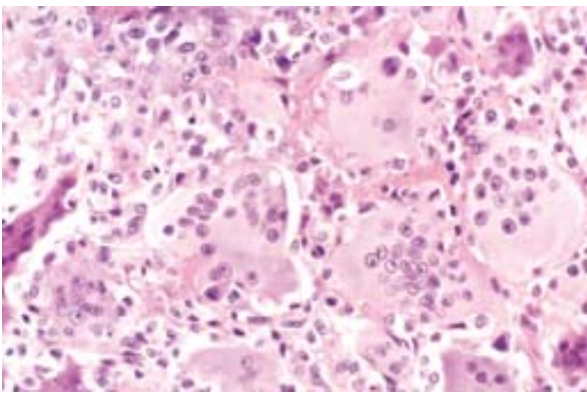


**Figure 26-37** Ewing sarcoma composed of sheets of small round cells with small amounts of clear cytoplasm.

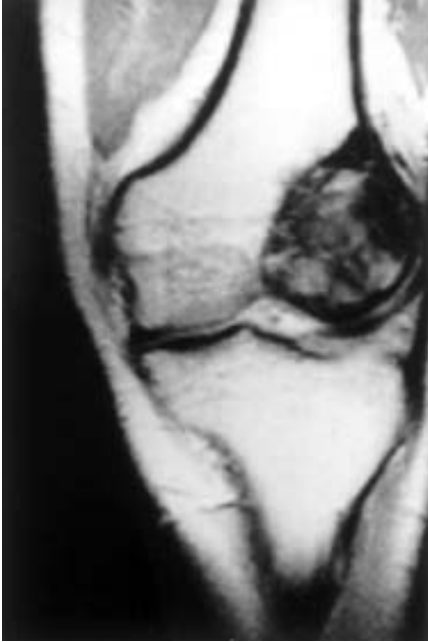

**Figure 26-38** Benign giant cell tumor illustrating an abundance of multinucleated giant cells with background mononuclear stromal cells.

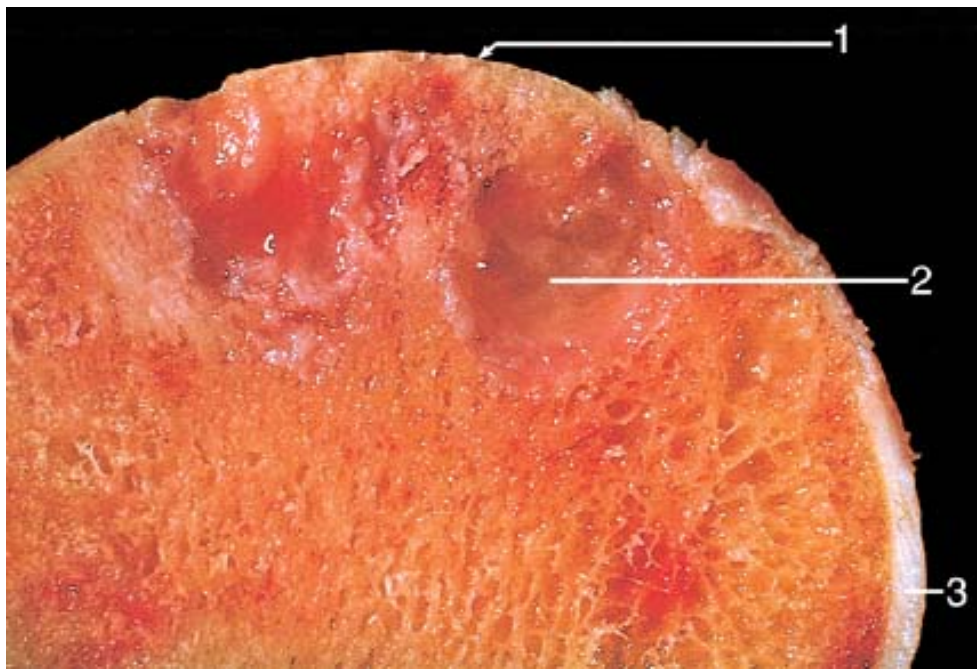




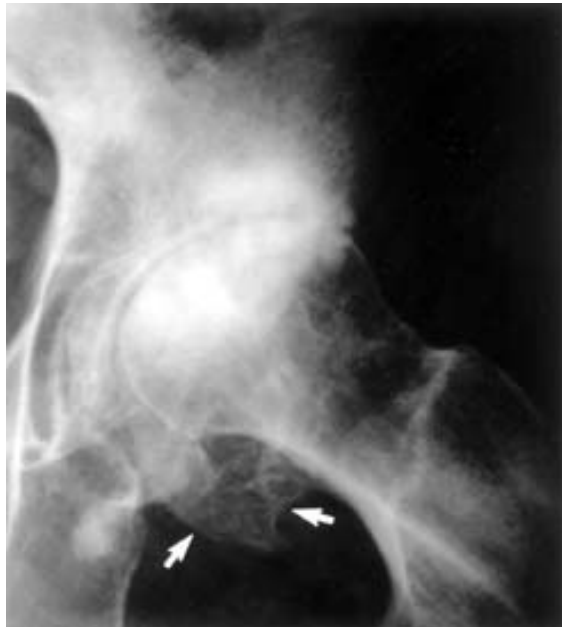**Figure 26-39** Magnetic resonance image of a giant cell tumor that replaces most of the femoral condyle and extends to the sub-chondral bone plate.



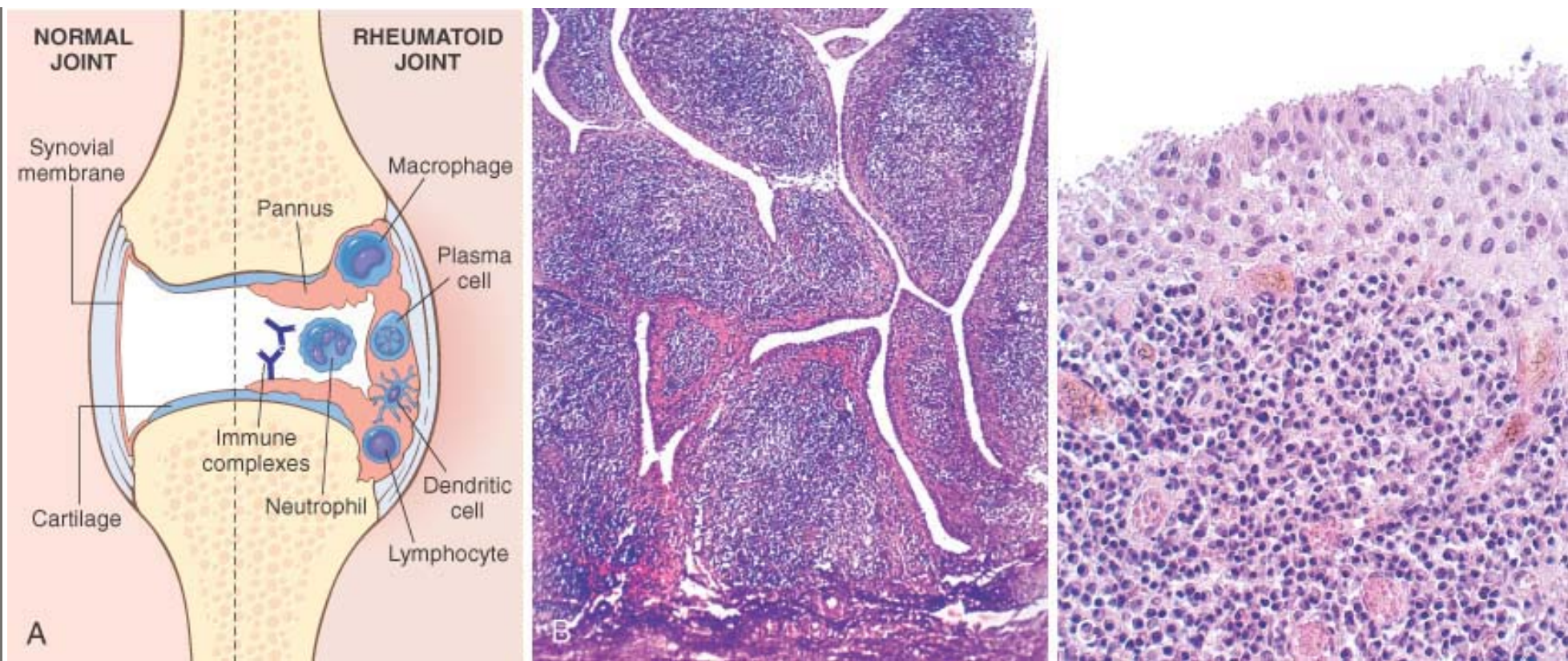
**Figure 26-40** Severe osteoarthritis with small islands of residual articular cartilage next to exposed subchondral bone. 1, Eburnated articular surface. 2, Subchondral cyst. 3, Residual articular cartilage.



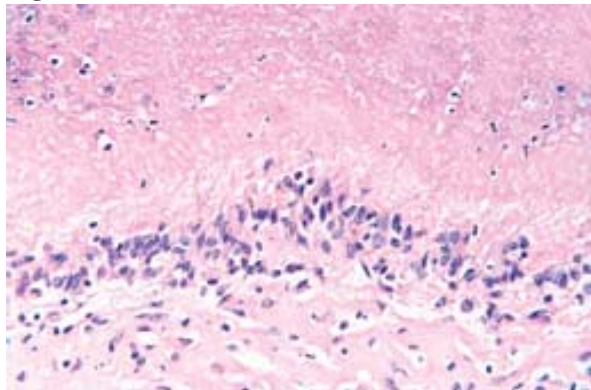
**Figure 26-41** Severe osteoarthritis of the hip. The joint space is narrowed, and there is subchondral sclerosis with scattered oval radiolucent cysts and peripheral osteophyte lipping (arrows).



**Figure 26-42** Rheumatoid arthritis. A, Schematic view of the joint lesion. (Modified from Feldmann M: Development of anti-TNF therapy for rheumatoid arthritis. *Nat Rev Immunol* 2:364, 2002.) B, Low magnification reveals marked synovial hypertrophy with formation of villi. C, At higher magnification, subsynovial tissue containing a dense lymphoid aggregate is seen.

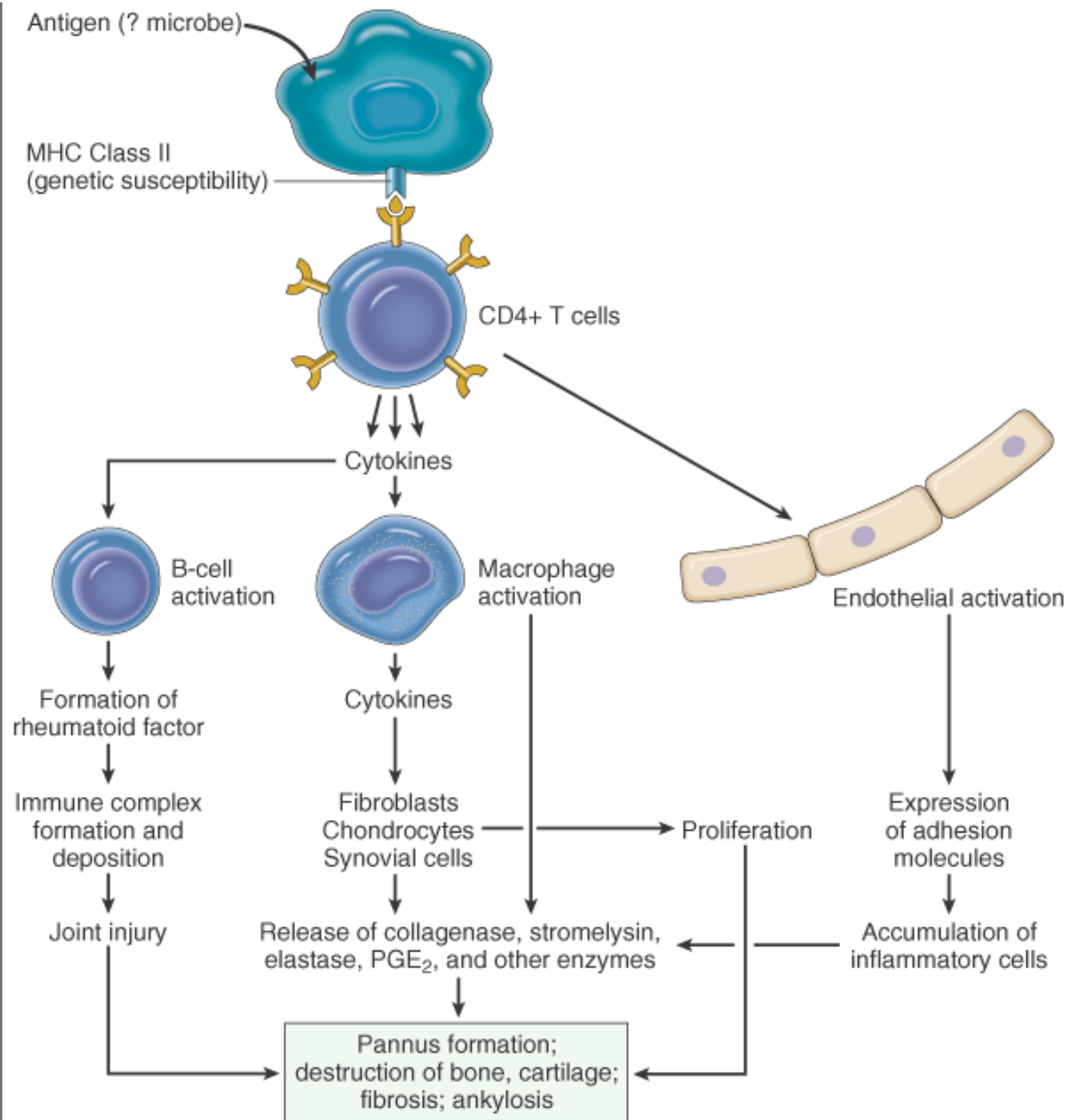


**Figure 26-43** Subcutaneous rheumatoid nodule with an area of necrosis (*top*) surrounded by a palisade of macrophages and scattered chronic inflammatory cells.



**Figure 26-44** Immunopathogenesis of rheumatoid arthritis.





**Figure 26-45** Rheumatoid arthritis. A, Early disease, most marked in the second metacarpophalangeal joint, where there is narrowing of joint space and marginal erosions on both radial

and ulnar aspects of the proximal phalanx (*see inset*). *B*, More advanced disease with loss of articular cartilage, narrowing of joint spaces of virtually all the small joints, and ulnar deviation of the fingers. There is dislocation of the second, third, and fourth proximal phalanges produced by advanced articular disease. (*Courtesy of Dr. John O'Connor, Boston University Medical Center, Boston, MA.*)

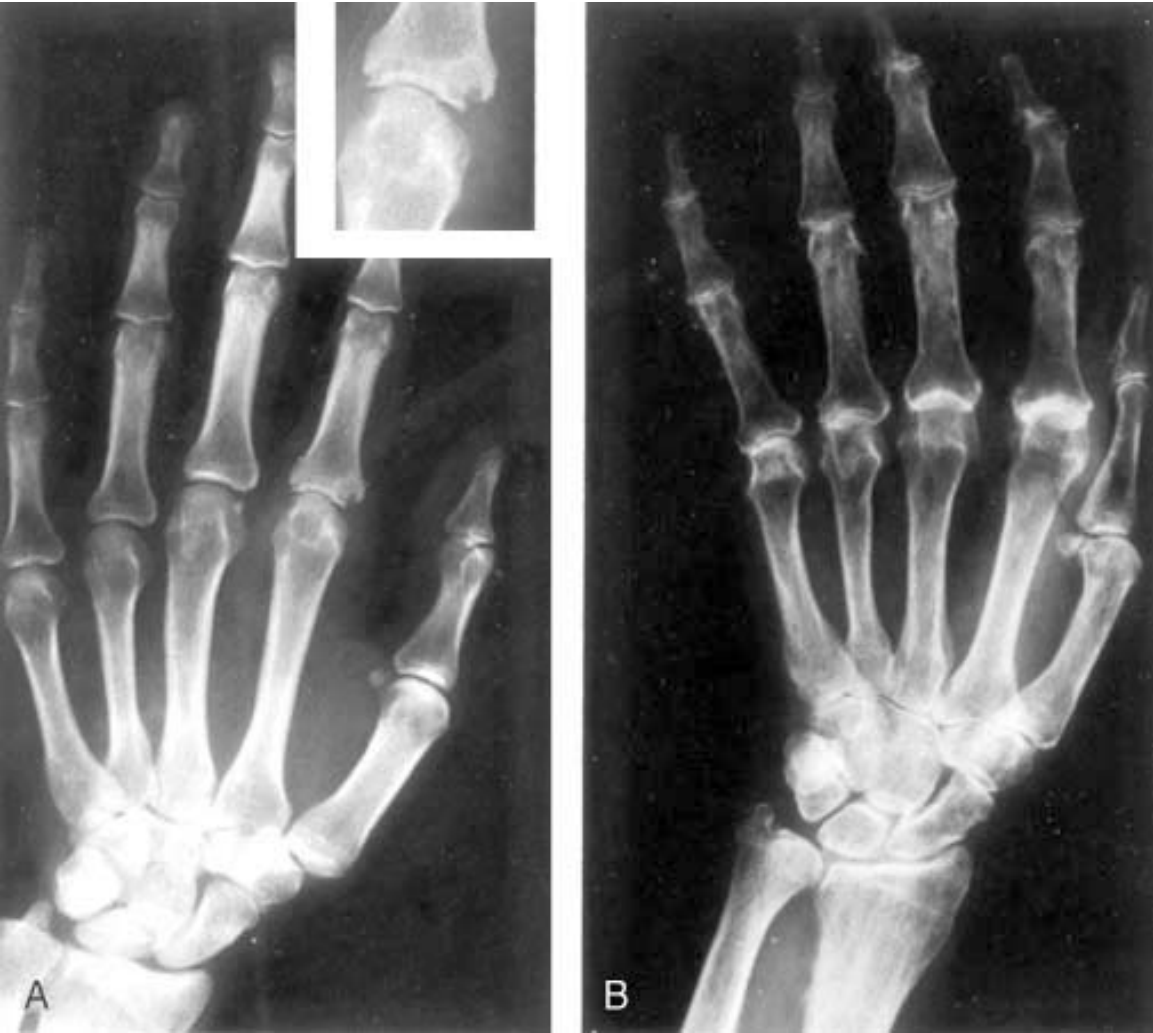

TABLE 26-7 -- Classification of Gout

Clinical Category	Metabolic Defect
<b>Primary Gout (90% of cases)</b>	
Enzyme defects unknown (85%–90% of primary gout)	■ Overproduction of uric acid
	••Normal excretion (majority)
	••Increased excretion (minority)
	••Underexcretion of uric acid with normal production

Known enzyme defects—e.g., partial HGPRT deficiency (rare)	■ Overproduction of uric acid
<b>Secondary Gout (10% of cases)</b>	
Associated with increased nucleic acid turnover—e.g., leukemias	■ Overproduction of uric acid with increased urinary excretion
Chronic renal disease	■ Reduced excretion of uric acid with normal production
Inborn errors of metabolism—e.g., complete HGPRT deficiency (Lesch-Nyhan syndrome)	■ Overproduction of uric acid with increased urinary excretion
HGPRT, hypoxanthine guanine phosphoribosyl transferase.	

and in some cases gouty arthritis. Less severe deficiencies of the enzyme may also induce hyperuricemia and gouty arthritis with only mild neurologic deficits, but together these causes of gout are uncommon. The great majority of cases of gout are primary, in which the metabolic defect underlying the increased levels of uric acid is unknown.

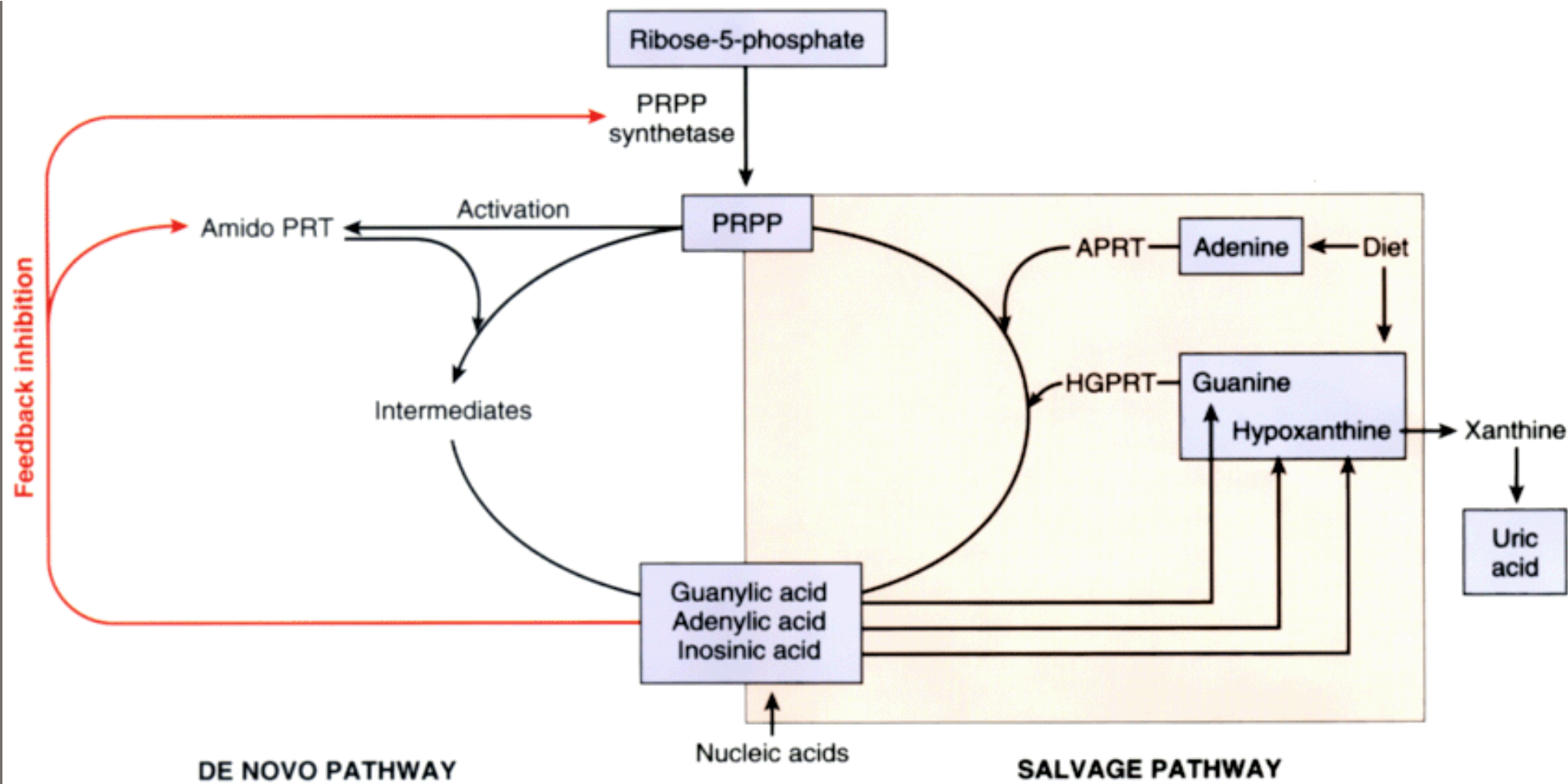
As stated earlier, hyperuricemia does not necessarily lead to gouty arthritis. Many factors contribute to the conversion of asymptomatic hyperuricemia into primary gout, including the following:

- *Age* of the individual and duration of the hyperuricemia are factors. Gout rarely appears before 20 to 30 years of hyperuricemia.
- *Genetic predisposition* is another factor. In addition to the well-defined X-linked abnormalities of HGPRT, primary gout follows multifactorial inheritance and runs in families.
- Heavy *alcohol* consumption predisposes to attacks of gouty arthritis.
- *Obesity* increases the risk of asymptomatic gout.
- Certain *drugs* (e.g., thiazides) predispose to the development of gout.
- *Lead toxicity* increases the tendency to develop saturnine gout ( Chapter 9 ).

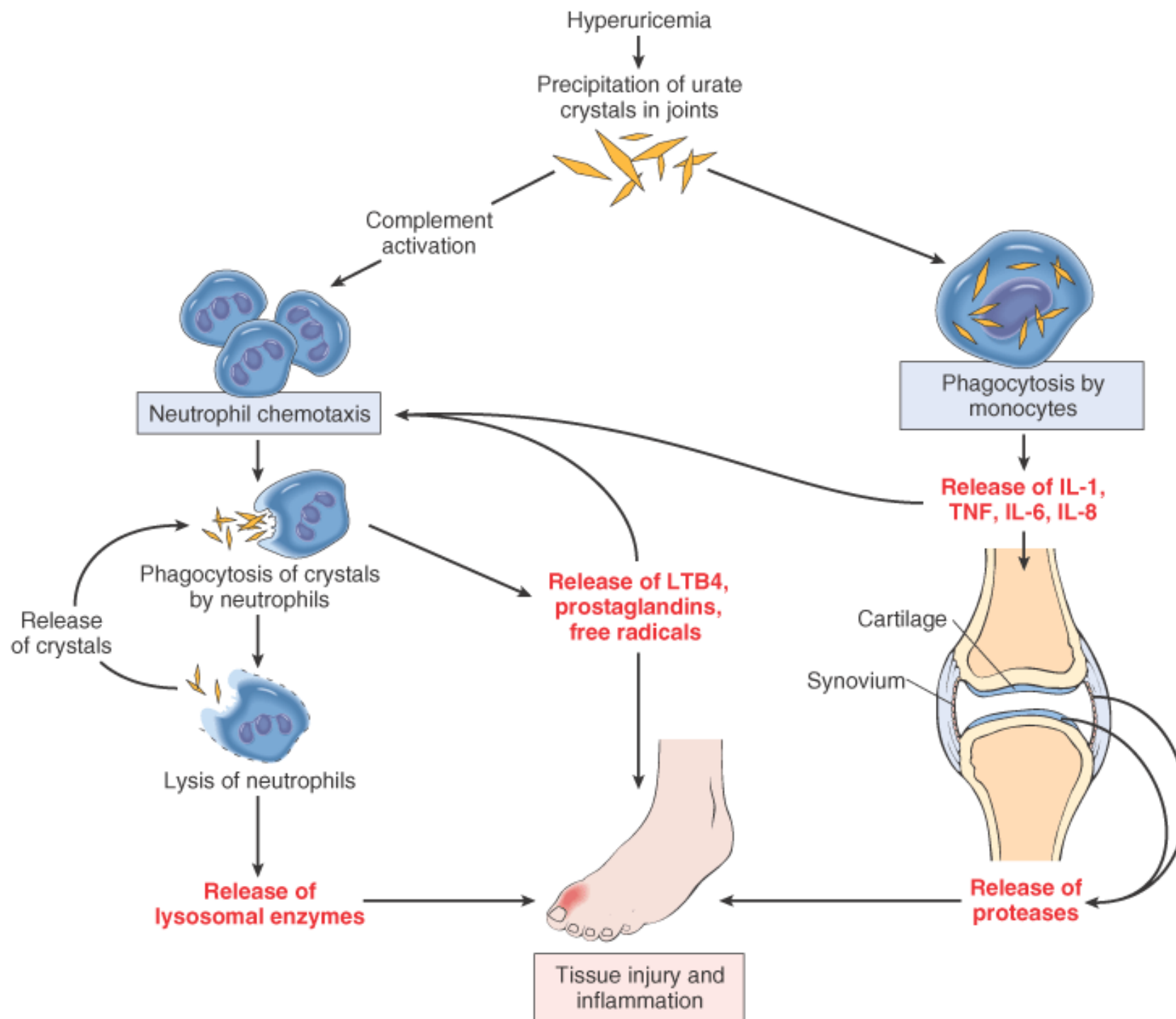
*Central to the pathogenesis of the arthritis is precipitation of monosodium urate crystals into the joints* ( Fig. 26-47 ). Synovial fluid is a poorer solvent for monosodium urate than plasma, and so with hyperuricemia the urates in the joint fluid become supersaturated, particularly in the peripheral joints (ankle), which may have temperatures as low as 20°C. With prolonged hyperuricemia, crystals and microtophi of urates develop in the synovium and in the joint cartilage. Some unknown event, possibly trauma, then initiates release of crystals into the synovial fluid, which begins a cascade of events. The released crystals are chemotactic to leukocytes and also activate complement,

**Figure 26-46** Purine metabolism. The conversion of PRPP to purine nucleotides is catalyzed by amido PRT in the de novo pathway and by APRT and HGPRT in the salvage pathway. APRT, amido-phosphoribosyltransferase; HGPRT, hypoxanthine-guanine phosphoribosyltransferase; PRPP, phosphoribosyl pyrophosphate; PRT, phosphoribosyltransferase.

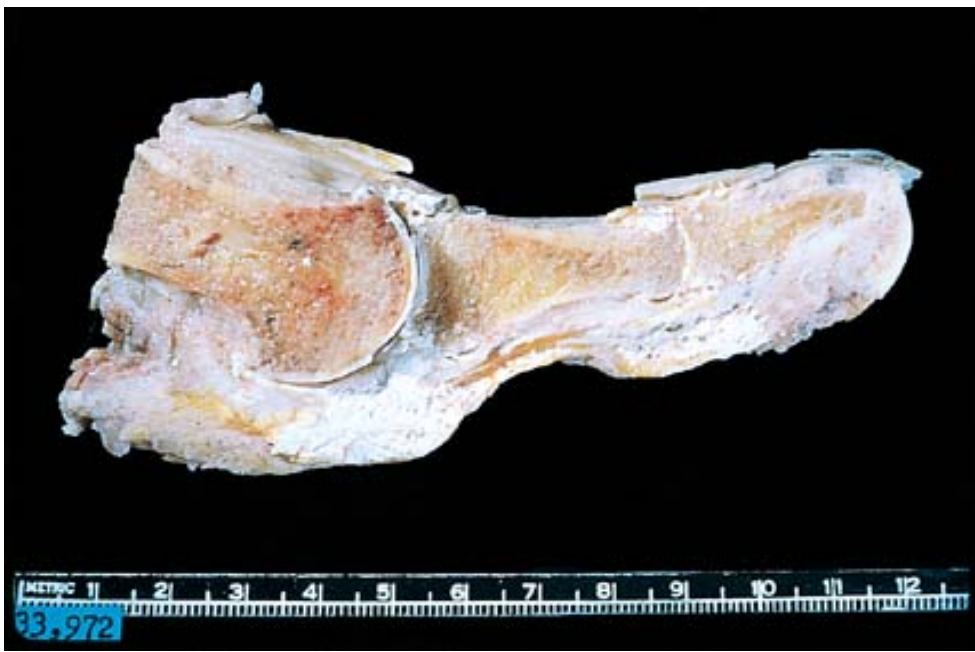



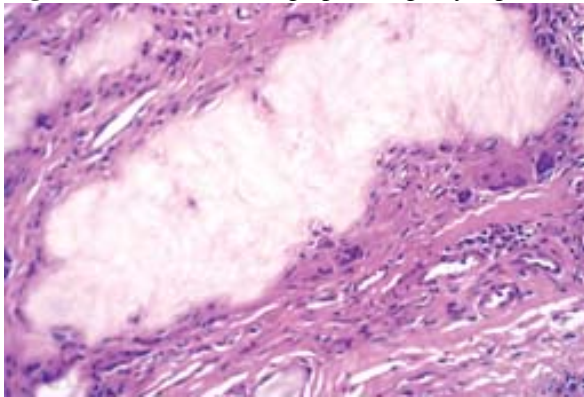
**Figure 26-47** Pathogenesis of acute gouty arthritis.



**Figure 26-48** Amputated great toe with white tophi involving the joint and soft tissues.

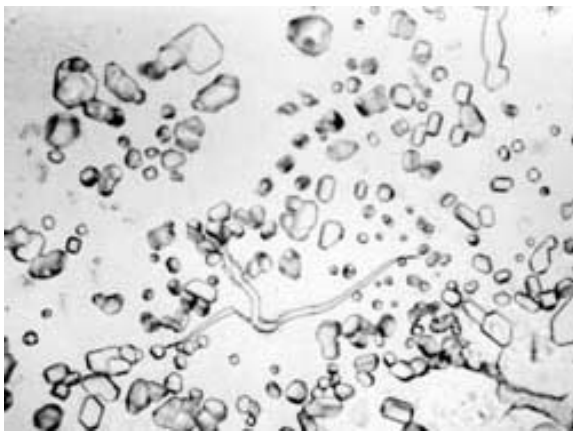


**Figure 26-49** Photomicrograph of a gouty tophus. An aggregate of dissolved urate crystals is surrounded by reactive fibroblasts, mononuclear inflammatory cells, and giant cells.

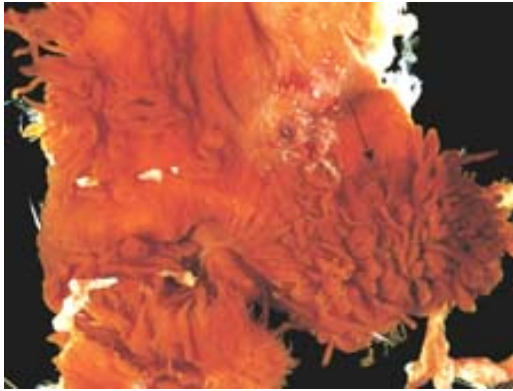

**Figure 26-50** Smear preparation of synovial fluid containing calcium pyrophosphate crystals.

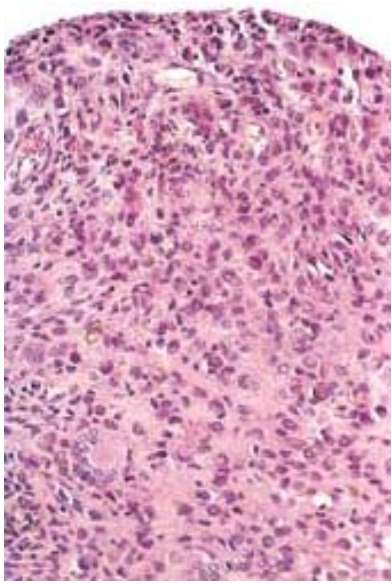




**Figure 26-51** Excised synovium with fronds and nodules typical of pigmented villonodular synovitis (PVNS) (*arrow*).



**Figure 26-52** Sheets of proliferating cells in PVNS bulging the synovial lining.



**TABLE 26-8** -- Soft Tissue Tumors

■ <i>Tumors of adipose tissue</i>
••Lipomas
••Liposarcoma
■ <i>Tumors and tumor-like lesions of fibrous tissue</i>
••Nodular fasciitis
••Fibromatoses
•••Superficial fibromatoses
•••Deep fibromatoses
••Fibrosarcoma
■ <i>Fibrohistiocytic tumors</i>
••Fibrous histiocytoma
••Dermatofibrosarcoma protuberans
••Malignant fibrous histiocytoma
■ <i>Tumors of skeletal muscle</i>
••Rhabdomyoma
••Rhabdomyosarcoma

■ <i>Tumors of smooth muscle</i>
••Leiomyoma
••Smooth muscle tumors of uncertain malignant potential
••Leiomyosarcoma
■ <i>Vascular tumors</i>
••Hemangioma
••Lymphangioma
••Hemangioendothelioma
••Hemangiopericytoma
••Angiosarcoma
■ <i>Peripheral nerve tumors</i>
••Neurofibroma
••Schwannoma
••Granular cell tumor
••Malignant peripheral nerve sheath tumors
■ <i>Tumors of uncertain histogenesis</i>
••Synovial sarcoma
••Alveolar soft part sarcoma
••Epithelioid sarcoma

at least 100:1. In the United States, little more than 8000 sarcomas are diagnosed annually (0.8% of invasive malignancies), yet they are responsible for 2% of all cancer deaths, reflecting their lethal nature.

### Pathogenesis and General Features

The cause of most soft tissue tumors is unknown. There are documented associations, however, between radiation therapy and rare instances in which chemical burns, thermal burns, or trauma were associated with subsequent development of a sarcoma. Exposure to phenoxyherbicides and chlorophenols has also been implicated in some cases. Kaposi sarcoma is causally associated with the human herpesvirus 8; however, viruses are probably not important in the pathogenesis of most sarcomas. The majority of soft tissue tumors occur sporadically, but a small minority is associated with genetic syndromes, the most notable of which are neurofibromatosis type 1 (neurofibroma, malignant schwannoma), Gardner syndrome (fibromatosis), Li-Fraumeni syndrome (soft tissue sarcoma), and Osler-Weber-Rendu syndrome (telangiectasia). Cytogenetic and molecular analyses of soft tissue tumors have provided significant insight into their biology. Specific chromosomal abnormalities and genetic derangements can not only be used as diagnostic markers, but also provide important clues about the genesis of the neoplasms.<sup>[60]</sup> For example, many of the mutations target oncogenes that encode transcription factors or cell-cycle regulators, and their dysfunction results in uncontrolled cell proliferation ( Table 26-9 ).



Soft tissue tumors may arise in any location, although approximately 40% occur in the lower extremities, especially the thigh; 20% in the upper extremities; 10% in the head and neck; and 30% in the trunk and retroperitoneum. Regarding sarcomas, males are affected more frequently than females (1.4:1), and the incidence generally increases with age. Fifteen per cent arise in children; they constitute the fourth most common malignancy in this age group, following brain tumors, hematopoietic cancers, and Wilms tumor in frequency. Specific sarcomas tend to appear in certain age groups (e.g., rhabdomyosarcoma in children, synovial sarcoma in young adulthood, and liposarcoma and malignant fibrous histiocytoma in mid- to late adult life).

Several features of soft tissue tumors influence their prognosis:

- Accurate histologic classification contributes significantly to establishing the prognosis of a sarcoma. Important diagnostic features are cell morphology and architectural arrangement ( Table 26-10 and Table 26-11 ). Often these features are not sufficient to distinguish one sarcoma

1317

from another, particularly with poorly differentiated aggressive tumors. Great reliance must, therefore, be placed on immunohistochemistry, electron microscopy, cytogenetics, and molecular genetics.

- Whatever the type, the *grade* of a soft tissue sarcoma is important for predicting its behavior. Grading, usually I to III, is based largely on the degree of differentiation, the average number of mitoses per high-power field, cellularity, pleomorphism, and an estimate of the extent of necrosis (presumably a reflection of rate of growth). Mitotic activity and extent of necrosis are thought to be particularly significant. The size, depth, and stage of the tumor also provide important diagnostic and prognostic information.<sup>[61]</sup>
- Staging helps determine the prognosis and chance of successful excision of a tumor. Several staging systems are utilized in treating sarcomas.
- In general, tumors arising in superficial locations (e.g., skin and subcutis) have a better prognosis than deep-seated lesions. In patients with deep-seated, high-grade sarcomas, metastatic disease develops in 80% of those with a tumor larger than 20 cm and 30% of those with a tumor larger than 5 cm. Overall the 10-year survival rate for sarcomas is approximately 40%.

TABLE 26-9 -- Chromosomal and Genetic Abnormalities in Soft Tissue Sarcomas

Tumor	Cytogenetic Abnormality	Genetic Abnormality
Extraosseous Ewing sarcoma and primitive neuroectodermal tumor	t(11;22)(q24;q12)	FLI-1-EWS fusion gene
	t(21;22)(q22;q12)	ERG-EWS fusion gene
	t(7;22)(q22;q12)	ETV1-EWS fusion gene
Liposarcoma—myxoid and round cell type	t(12;16)(q13;p11)	CHOP/TLS fusion gene
Synovial sarcoma	t(x;18)(p11;q11)	SYT-SSX fusion gene
Rhabdomyosarcoma—alveolar type	t(2;13)(q35;q14)	PAX3-FKHR fusion gene
	t(1;13)(p36;q14)	PAX7-FKHR fusion gene
Extraskeletal myxoid chondrosarcoma	t(9;22)(q22;q12)	CHN-EWS fusion gene
Desmoplastic small round cell tumor	t(11;22)(p13;q12)	EWS-WT1 fusion gene
Clear cell sarcoma	t(12;22)(q13;q12)	EWS-ATF1 fusion gene

Dermatofibrosarcoma protuberans	t(17;22)(q22;q15)	COLA1-PDGFB fusion gene
Alveolar soft part sarcoma	t(X;17)(p11.2;q25)	TFE3-ASPL fusion gene
Congenital fibrosarcoma	t(12;15)(p13;q23)	ETV6-NTRK3 fusion gene

**TABLE 26-10** -- Morphology of Cells in Soft Tissue Tumors

Cell Type	Features	Tumor Type
Spindle cell	Rod-shaped, long axis twice as great as short axis	Fibrous, fibrohistiocytic, smooth muscle, Schwann cell
Small round cell	Size of a lymphocyte with little cytoplasm	Rhabdomyosarcoma, primitive neuroectodermal tumor
Epithelioid	Polyhedral with abundant cytoplasm, nucleus is centrally located	Smooth muscle, Schwann cell endothelial, epithelioid sarcoma

**TABLE 26-11** -- Architectural Patterns in Soft Tissue Tumors

Pattern	Tumor Type
Fascicles of eosinophilic spindle cells intersecting at right angles	Smooth muscle
Short fascicles of spindle cells radiating from a central point (like spokes on a wheel)—storiform	Fibrohistiocytic
Nuclei arranged in columns—palisading	Schwann cell
Herringbone	Fibrosarcoma
Mixture of fascicles of spindle cells and groups of epithelioid cells—biphasic	Synovial sarcoma

With this brief background, we now turn to the individual tumors and tumor-like lesions. Some of the soft tissue tumors are presented elsewhere—tumors of peripheral nerve ( Chapter 27 ); and tumors of vascular origin, including Kaposi sarcoma ( Chapter 11 ).

### Fatty Tumors

#### LIPOMA

Benign tumors of fat, known as *lipomas*, are the most common soft tissue tumor of adulthood. They are subclassified according to particular morphologic features as conventional lipoma, fibrolipoma, angiolipoma, spindle cell lipoma, myelolipoma, and pleomorphic lipoma. Some of the variants have characteristic chromosomal abnormalities; for example, conventional lipomas often show rearrangements of 12q14-15, 6p, and 13q, and spindle cell and pleomorphic lipomas have rearrangements of 16q and 13q.

#### Morphology.

The conventional lipoma, the most common subtype, is a well-encapsulated mass of mature adipocytes that varies considerably in size. It arises in the subcutis of the proximal extremities and trunk, most frequently during mid-adulthood. Infrequently, lipomas are large, intramuscular, and poorly circumscribed. Histologically, they consist of mature white fat cells with no pleomorphism.

Lipomas are soft, mobile, and painless (except angiolipoma) and are usually cured by simple excision.

1318

## LIPOSARCOMA

Liposarcomas are one of the most common sarcomas of adulthood and appear in those in their forties to sixties; they are uncommon in children. They usually arise in the deep soft tissues of the proximal extremities and retroperitoneum and are notorious for developing into large tumors.

### Morphology.

Histologically, liposarcomas can be divided into well-differentiated, myxoid, round cell, and pleomorphic variants. The cells in well-differentiated liposarcomas are readily recognized as lipocytes. In the other variants, most of the tumor cells are not obviously adipogenic, but some cells indicative of fatty differentiation are almost always present. These cells are known as **lipoblasts**; they mimic fetal fat cells and contain round clear cytoplasmic vacuoles of lipid that scallop the nucleus ( Fig. 26-53 ). The myxoid and round cell variant of liposarcoma has a t(12;16) chromosomal abnormality in most cases ( Table 26-9 ).

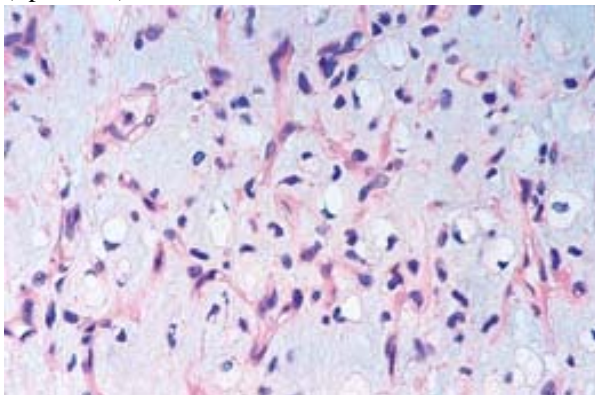
The well-differentiated variant is relatively indolent, the myxoid type is intermediate in its malignant behavior, and the round cell and pleomorphic variants usually are aggressive and frequently metastasize. All types of liposarcoma recur locally and often repeatedly unless adequately excised.

## Fibrous Tumors and Tumor-Like Lesions

### REACTIVE PSEUDOSARCOMATOUS PROLIFERATIONS

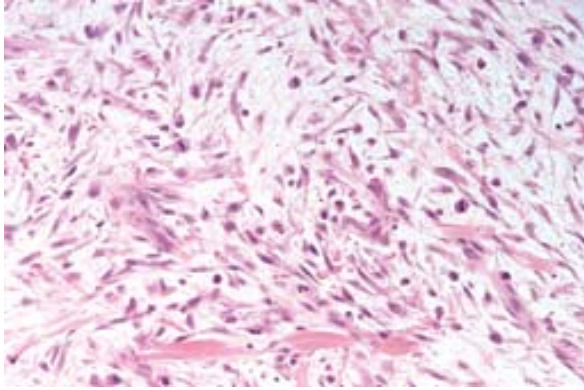
Reactive pseudosarcomatous proliferations are nonneoplastic lesions that either develop in response to some form of local trauma (physical or ischemic) or are idiopathic. They are composed of plump reactive fibroblasts or related mesenchymal cells. Clinically, they are alarming because they develop suddenly and grow rapidly; histologically, they cause concern because they mimic sarcomas owing to their hypercellularity,

**Figure 26-53** Myxoid liposarcoma with abundant ground substance in which are scattered adult-appearing fat cells and more primitive cells, some containing small lipid vacuoles (lipoblasts).

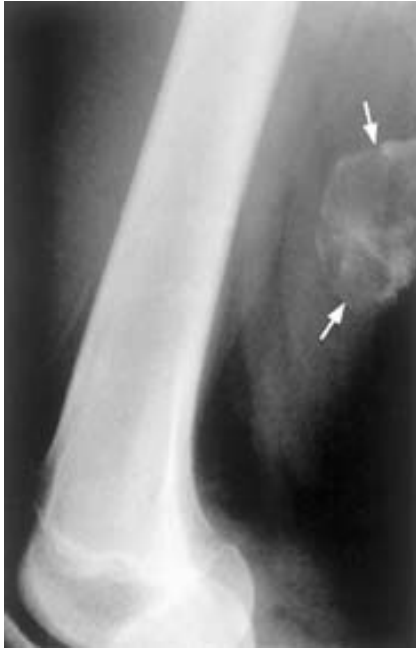



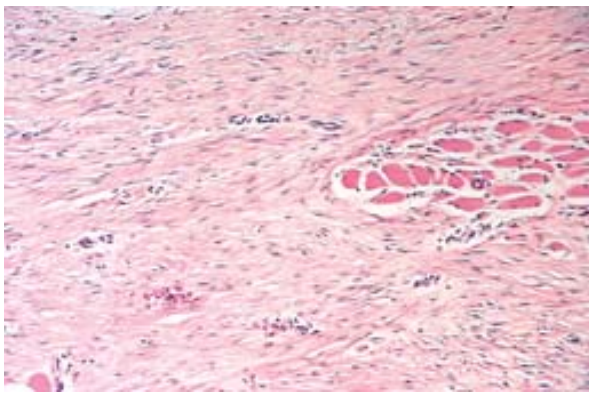
**Figure 26-54** Nodular fasciitis with plump, randomly oriented spindle cells surrounded by myxoid stroma. Note the mitotic activity and extravasated red blood cells.



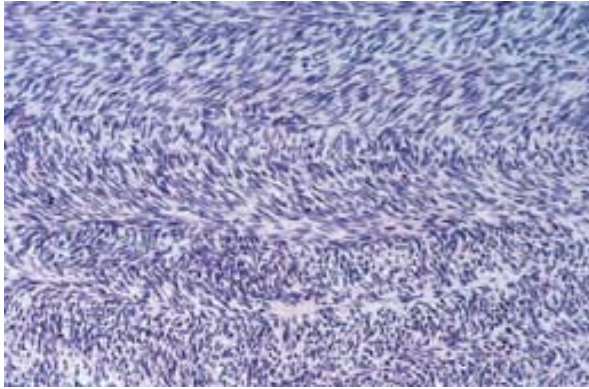
**Figure 26-55** Peripherally mineralized myositis ossificans (*arrows*) involving the posterior thigh.



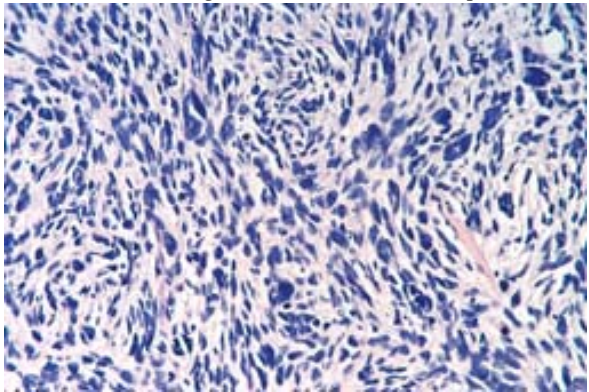
**Figure 26-56** Fibromatosis infiltrating between skeletal muscle cells.



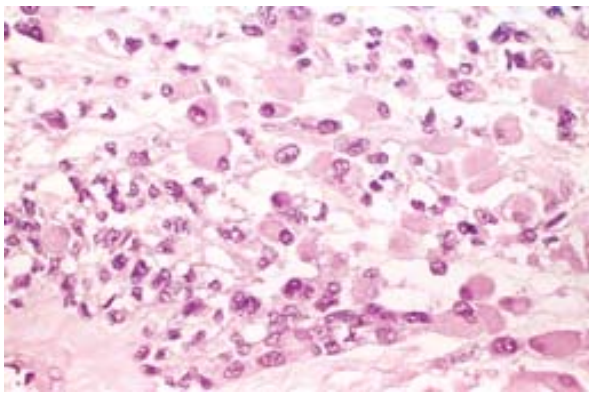
**Figure 26-57** Fibrosarcoma composed of malignant spindle cells arranged in a herringbone pattern.



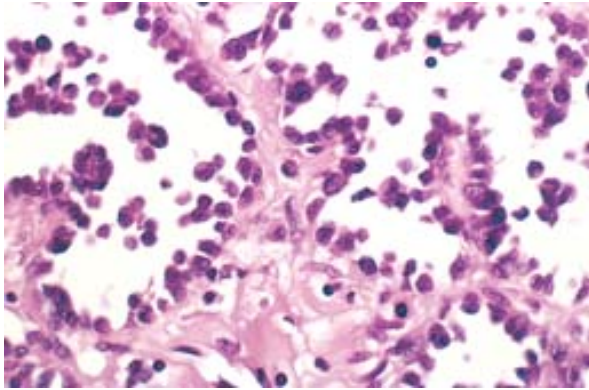
**Figure 26-58** Malignant fibrous histiocytoma revealing fascicles of plump spindle cells in a swirling (storiform) pattern, typical but not pathognomonic of this neoplasm. (*Courtesy of Dr. J. Corson, Brigham and Women's Hospital, Boston, MA.*)



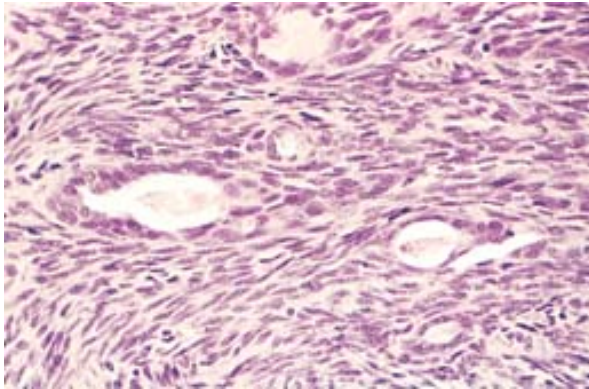
**Figure 26-59** Rhabdomyosarcoma composed of malignant small round cells. The rhabdomyoblasts are large and round and have abundant eosinophilic cytoplasm; no cross-striations are evident.



**Figure 26-60** Alveolar rhabdomyosarcoma with numerous spaces lined by tumor cells.



**Figure 26-61** Synovial sarcoma revealing the classic biphasic spindle cell and glandular-like histologic appearance.



## References

1. Glimcher MJ, ed: Metabolic Bone Disease and Clinical Related Disorders, 2nd ed. Philadelphia: WB Saunders, 1990.
2. Manolagas SC: Birth and death of bone cells: basic regulatory mechanisms and implications for the pathogenesis and treatment of osteoporosis. *Endocr Rev* 21:115, 2000.



3. Ducy P, Schinke T, Karsenty G: The osteoblast: a sophisticated fibroblast under central surveillance. *Science* 289:1501, 2000.
4. Patel MS, Karsenty G: Regulation of bone formation and vision by LRP5. *N Engl J Med* 346:1572, 2002.
5. Wagner EF, Karsenty G: Genetic control of skeletal development. *Curr Opin Genet Dev* 11:527, 2001.
6. Harada S, Rodan GA: Control of osteoblast function and regulation of bone mass. *Nature* 423:349, 2003.
7. Turner CH, et al: Do bone cells behave like a neuronal network? *Calcif Tissue Int* 70:435, 2002.
8. Teitelbaum SL: Bone resorption by osteoclasts. *Science* 289:1504, 2000.
9. Boyle WJ, Simonet WS, Lacey DL: Osteoclast differentiation and activation. *Nature* 423:337, 2003.
10. Lars ET, Boyle WJ, Penninger JM: RANK-L and RANK: T cells, bone loss and mammalian evolution. *Ann Rev Immunol* 20:795, 2002.
11. Young MF, et al: Structure, expression, and regulation of the major noncollagenous matrix proteins of bone. *Clin Orthop* 281:275, 1992.
12. Raisz LG: Physiology and pathophysiology of bone remodeling. *Clin Chem* 45:1353, 1999.
13. Olsen BR, Reginato AM, Wang W: Bone development. *Annu Rev Cell Dev Biol* 16:191, 2000.
14. Mundlos S, Olsen BR: Heritable diseases of the skeleton. Part I: Molecular insights into skeletal development—transcription factors and signaling pathways. *FASEB J* 11:125, 1997.
15. Mundlos S, Olsen BR: Heritable diseases of the skeleton. Part II: Molecular insights into skeletal development—matrix components and their homeostasis. *FASEB J* 11:227, 1997.
16. Superti-Furga A, Bonafe L, Rimoin DL: Molecular-pathogenetic classification of genetic disorders of the skeleton. *Am J Med Genet* 106:282, 2001.
17. Cole WG: Advances in osteogenesis imperfecta. *Clin Orthop* 401:6, 2002.
18. Bullough PG, Davidson DD, Lorenzo JC: The morbid anatomy of the skeleton in osteogenesis imperfecta. *Clin Orthop* 159:42, 1981.
19. de Vernejoul MC, Besichow O: Human osteopetrosis and other sclerosing disorders: recent genetic developments. *Calcified Tiss Int* 69:1, 2002.
20. Kornak U, et al.: Loss of the CIC-7 chloride channel leads to osteopetrosis in mice and man. *Cell* 104:205, 2001.
21. Tuck SP, Francis RM: Osteoporosis. *Postgrad Med J* 78:526, 2002.
22. Mosekilde L: Mechanisms of age-related bone loss. *Novartis Found Symp* 235:150, 2001.
23. Kenny AM, Prestwood KM: Osteoporosis. Pathogenesis, diagnosis, and treatment in older adults. *Rheum Dis Clin North Am* 26:569, 2000.
24. Reddy SV, et al: Paget's disease of bone: a disease of osteoclast. *Rev Endocr Metab Disord* 2:195, 2001.
25. Leach RJ, Singer FR, Roodman G: The genetics of Paget's disease of the bone. *J Clinical Endocrin Metab* 86:24, 2001.
26. Hadjipavlou AG, Gaitanis IN, Kontakis GM: Paget's disease of the bone and its management. *J Bone Joint Surg Br* 84:160, 2002.
27. Gonzalez EA, Martin KJ: Renal osteodystrophy. *Rev Endocr Metab Disord* 2:187, 2001.
28. Khan SN, Bostrom MP, Lane JM: Bone growth factors. *Orthop Clin North Am* 31:375, 2000.

29. Saucacos PN, Urbaniak JR: Osteonecrosis. Clin Orthop 386:2, 2001.
30. Lew DP, Waldvogel FA: Osteomyelitis. N Engl J Med 336:999, 1997.
31. Cunningham R, Cockayne A, Humphreys H: Clinical and molecular aspects of the pathogenesis of *Staphylococcus aureus* bone and joint infections. J Med Microbiol 44:157, 1996.
- 

32. Senac MO, Jr., Isaacs H, Gwinn JL: Primary lesions of bone in the 1st decade of life: retrospective survey of biopsy results. Radiology 160:491, 1986.
33. Klein MH, Shankman S: Osteoid osteoma: radiologic and pathologic correlation. Skeletal Radiol 21:23, 1992.
34. Ragland BD, et al: Cytogenetics and molecular biology of osteosarcoma. Lab Invest 82:365, 2002.
35. Unni KK, Dahlin DC: Osteosarcoma: pathology and classification. Semin Roentgenol 24:143, 1989.
36. Bielack SS, et al: Prognostic factors in high-grade osteosarcoma of the extremities or trunk: an analysis of 1,702 patients treated on neoadjuvant cooperative osteosarcoma study group protocols. J Clin Oncol 20:776, 2002.
37. Ramappa AJ, et al: Chondroblastoma of bone. J Bone Joint Surg Am 82-A:1140, 2000.
38. Zillmer DA, Dorfman HD: Chondromyxoid fibroma of bone: thirty-six cases with clinicopathologic correlation. Hum Pathol 20:952, 1989.
39. Lee FY, et al: Chondrosarcoma of bone: an assessment of outcome. J Bone Joint Surg Am 81:326, 1999.
40. Weinstein LS, Chen M, Liu J: Gs( $\alpha$ ) mutations and imprinting defects in human disease. Ann NY Acad Sci 968:173, 2002.
41. Papagelopoulos PJ, et al: Clinicopathologic features, diagnosis, and treatment of malignant fibrous histiocytoma of bone. Orthopedics 23:59, 2000.
42. Arvand A, Denny CT: Biology of *EWS/ETS* fusions in Ewing's family tumors. Oncogene 20:5747, 2001.
43. Meideiros LJ, et al: Giant cells and mononuclear cells of giant cell tumor of bone resemble histiocytes. Appl Immunohistochem 1:115, 1993.
44. Aigner T, McKenna L: Molecular pathology and pathobiology of osteoarthritic cartilage. Cell Mol Life Sci 59:5, 2002.
45. Firestein GS: Evolving concepts of rheumatoid arthritis. Nature 423:356, 2003.
46. Lee DM, Weinblatt ME: Rheumatoid arthritis. Lancet 358:903, 2001.
47. Gravallese EM, Goldring SR: Cellular mechanisms and the role of cytokines in bone erosions in rheumatoid arthritis. Arthritis Rheum 43:2143, 2000.
48. Gregersen PK: Teasing apart the complex genetics of human autoimmunity: lesions from rheumatoid arthritis. Clin Immunol 107:1, 2003.
49. Hyrich KL, Inman RD: Infectious agents in chronic rheumatic diseases. Curr Opin Rheumatol 13:300, 2001.

50. Feldmann M: Development of anti-TNF therapy for rheumatoid arthritis. *Nat Rev Immunol* 2:364, 2002.
51. Schneider R, Passo MH: Juvenile rheumatoid arthritis. *Rheum Dis Clin North Am* 28:503, 2002.
52. Sieper J, et al: Ankylosing spondylitis: an overview. *Ann Rheum Dis* 61 (suppl 3):III8, 2002.
53. Granfors K: Host-microbe interaction in HLA-B27-associated diseases. *Ann Med* 29:153, 1997.
54. Gross M: Molecular recognition. Crystallographic antibodies. *Nature* 373:105, 1995.
55. Steere AC: Lyme disease. *N Engl J Med* 345:115, 2001.
56. Ytterberg SR: Viral arthritis. *Curr Opin Rheumatol* 11:275, 1999.
57. German DC, Holmes EW: Hyperuricemia and gout. *Med Clin North Am* 70:419, 1986.
58. Morgan MP, McCarthy GM: Signaling mechanisms involved in crystal-induced tissue damage. *Curr Opin Rheumatol* 14:292, 2002.
59. Timms AE, et al: Genetic studies of disorders of calcium crystal deposition. *Rheumatology (Oxford)* 41:725, 2002.
60. Sandberg AA: Cytogenetics and molecular genetics of bone and soft-tissue tumors. *Am J Med Genet* 115:189, 2002.
61. Oliveira AM, Nascimento AG: Grading in soft tissue tumors: principles and problems. *Skeletal Radiol* 30:543, 2001.
62. De Wever I, et al: Cytogenetic, clinical, and morphologic correlations in 78 cases of fibromatosis: a report from the CHAMP Study Group. *Chromosomes and Morphology. Mod Pathol* 13:1080, 2000.
63. Xia SJ, Pressey JG, Barr FG: Molecular pathogenesis of rhabdomyosarcoma. *Cancer Biol Ther* 1:97, 2002.
64. Malogolowkin MH, Ortega JA: Rhabdomyosarcoma of childhood. *Pediatr Ann* 17:251, 1988.

## Chapter 27 - Peripheral Nerve and Skeletal Muscle

---

**Douglas C. Anthony MD, PhD**  
**Matthew P. Frosch MD, PhD**  
**Umberto De Girolami MD**

---



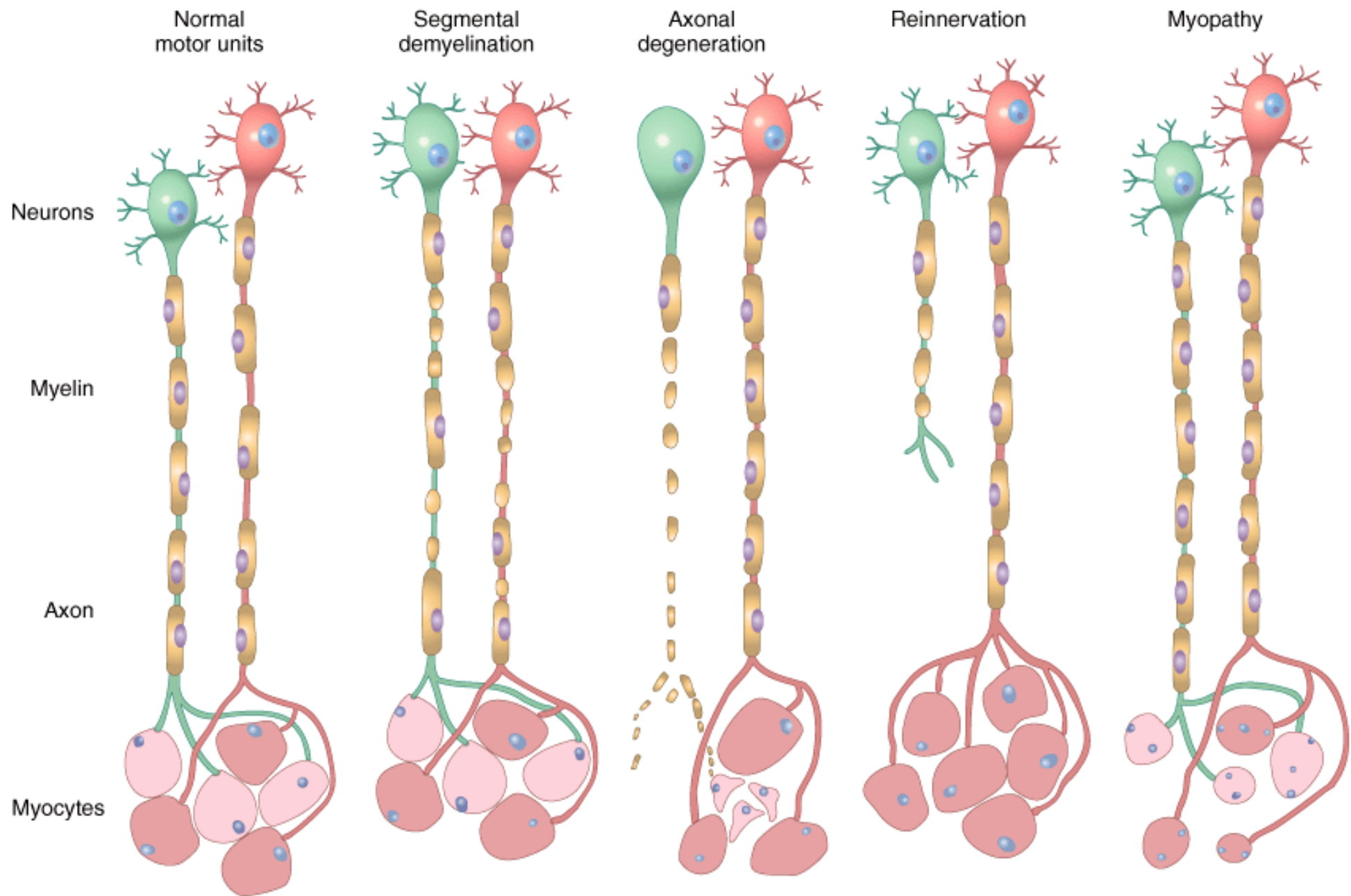
## Normal

The functional unit of the neuromuscular system is the *motor unit*, which consists of (1) a *lower motor neuron* in the anterior horn of the spinal cord or cranial nerve motor nucleus in the brain stem, (2) the *axon* of that neuron, and (3) the multiple *muscle fibers* it innervates ( Fig. 27-1 ). Lower motor neurons are distributed in the anterior horns of the spinal cord in columns or groups; they are arranged somatotopically so that cells lying medially innervate proximal muscles and those lying laterally supply the distal musculature. The number of muscle fibers within each unit varies considerably. Muscles with highly refined movements, such as the extrinsic muscles of the eye, have a high neuron-to-muscle-fiber ratio (1:10); those with relatively coarse and stereotyped movements, such as calf muscles, have a much lower ratio (1:1800).<sup>[1]</sup>

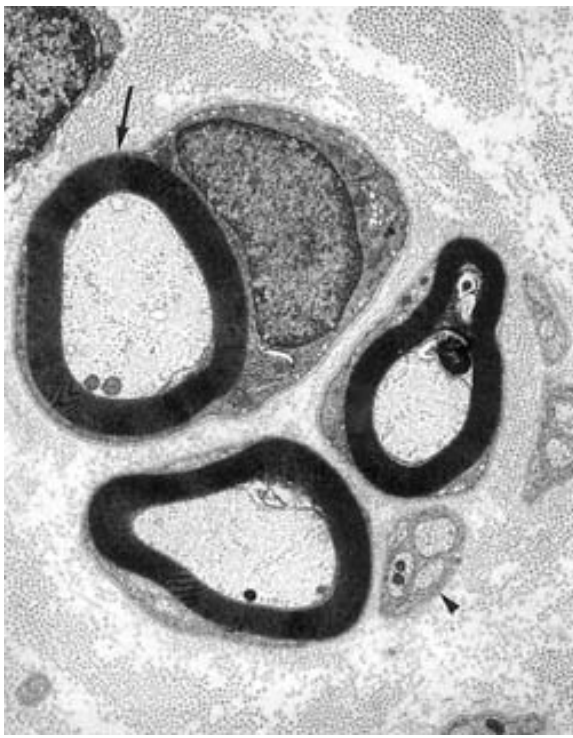### NORMAL PERIPHERAL NERVE

The principal structural component of peripheral nerve is the *nerve fiber* (an axon with its Schwann cells and myelin sheath). A nerve consists of numerous fibers that are grouped

**Figure 27-1** Normal and abnormal motor units. *Normal motor units*: Two adjacent motor units are shown. *Segmental demyelination*: Random internodes of myelin are injured and are remyelinated by multiple Schwann cells, while the axon and myocytes remain intact. *Axonal degeneration*: The axon and its myelin sheath undergo anterograde degeneration (shown for the green neuron), with resulting denervation atrophy of the myocytes within its motor unit. *Reinnervation of muscle*: Sprouting of adjacent (red) uninjured motor axons leads to fiber type grouping of myocytes, while the injured axon attempts axonal sprouting. *Myopathy*: Scattered myocytes of adjacent motor units are small (degenerated or regenerated), whereas the neurons and nerve fibers are normal.



**Figure 27-2** Electron micrograph of myelinated (*arrow*) and unmyelinated (*arrowhead*) fibers in human sural nerve. One Schwann cell nucleus is present.



**Figure 27-3** Electron micrograph of skeletal muscle in the longitudinal plane. A nucleus is located at the top of the illustration and the sarcomeres of two myofibrils are located below. The principal components of the sarcomere are identified, creating the pattern of cross-striations. (*From Bloom W, Fawcett DW: A Textbook of Histology, 11th ed. Philadelphia, WB Saunders, 1986.*)




TABLE 27-1 -- Muscle Fiber Types

	Type 1	Type 2
Action	Sustained force	Sudden movements
Strength	Weight-bearing	Purposeful motion
Enzyme content	NADH dark staining	NADH light staining
	ATPase at pH 4.2, dark staining	ATPase at pH 4.2, light staining
	ATPase at pH 9.4, light staining	ATPase at pH 9.4, dark staining
Lipids	Abundant	Scant
Glycogen	Scant	Abundant
Ultrastructure	Many mitochondria	Few mitochondria



	Wide Z-band	Narrow Z-band
Physiology	Slow-twitch	Fast-twitch
Color	Red	White
Prototype	Soleus (pigeon)	Pectoral (pigeon)

consist of specialized muscle and nerve fibers, delimited by a connective tissue capsule.

The connective tissue sheath of muscles includes the *endomysium*, which surrounds individual muscle fibers; the *perimysium*, which groups muscle fibers into primary and secondary bundles (fasciculi); and the *epimysium*, which envelops single muscles or large groups of fibers.

## Pathology

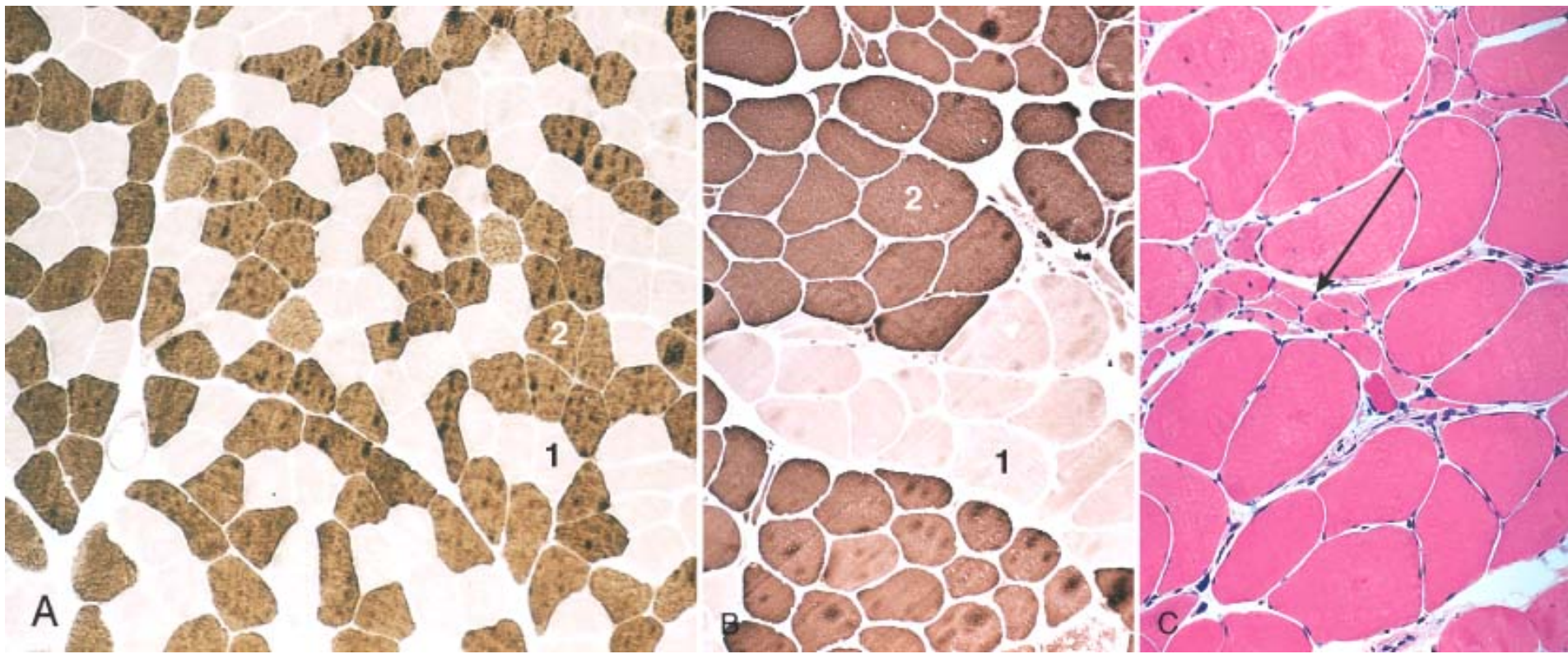
### General Reactions of the Motor Unit

The two main responses of peripheral nerve to injury are based on the target of the insult: either the Schwann cell or the axon. Diseases that affect primarily the Schwann cell lead to a loss of myelin, referred to as *segmental demyelination*. In contrast, primary involvement of the neuron and its axon leads to axonal degeneration. In some diseases, axonal degeneration may be followed by *axonal regeneration* and *reinnervation* of muscle. The two principal pathologic processes seen in skeletal muscle are denervation atrophy, which follows loss of axons, and those due to a primary abnormality of the muscle fiber itself, referred to as *myopathy*. We now consider the general features of these processes.

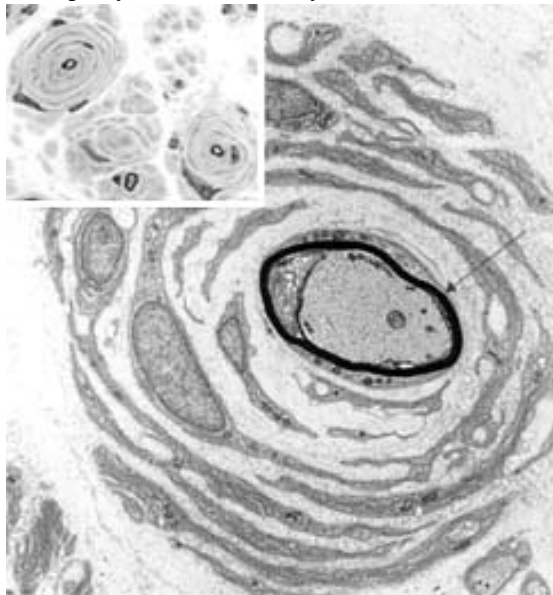
### SEGMENTAL DEMYELINATION

Segmental demyelination occurs when there is dysfunction of the Schwann cell (as in Guillain-Barré Syndrome) or damage to the myelin sheath (e.g., in hereditary motor and sensory neuropathy); there is no primary abnormality of the axon. The process affects some Schwann cells and their corresponding internodes while sparing others (see Fig. 27-1 ). The disintegrating myelin is engulfed initially by Schwann cells

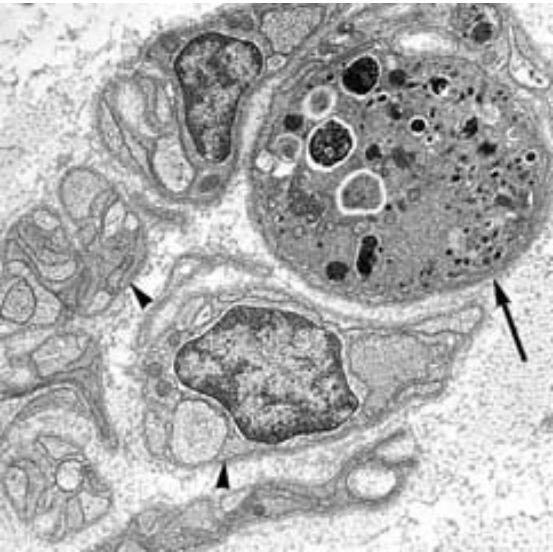**Figure 27-4** *A*, ATPase histochemical staining, at pH 9.4, of normal muscle showing checkerboard distribution of intermingled type 1 (*light*) and type 2 (*dark*) fibers. *B*, In contrast, fibers of either histochemical type are grouped together after reinnervation of muscle. *C*, A cluster of atrophic fibers (group atrophy) in the center (*arrow*).



**Figure 27-5** Electron micrograph of a single, thinly myelinated axon (*arrow*) surrounded by concentrically arranged Schwann cells, forming an onion bulb. (Courtesy of G. Richard Dickersin, MD, from *Diagnostic Electron Microscopy: A Text-Atlas*. New York, Igaku-Shoin Medical Publishers, 2000, p. 984.) *Inset*, Light microscopic appearance of an onion bulb neuropathy, characterized by "onion bulbs" surrounding axons.



**Figure 27-6** Electron micrograph of a degenerating axon (*arrow*) adjacent to several intact unmyelinated fibers (*arrow-heads*). The axon is markedly distended and contains numerous degenerating organelles and dense bodies.



**TABLE 27-2** -- Hereditary Sensory and Autonomic Neuropathies

Disease and Inheritance	Gene and Locus	Clinical and Pathologic Findings
HSAN I; autosomal-dominant	Serine palmitoyl transferase, long-chain base, subunit 1 (SPTLC1) gene; 9q22.1-q22.3	Predominantly sensory neuropathy, presenting in young adults; axonal degeneration (mostly myelinated fibers)
HSAN II; autosomal-recessive (some cases are sporadic)	Unknown	Predominantly sensory neuropathy, presenting in infancy; axonal degeneration (mostly myelinated fibers)
HSAN III (Riley-Day syndrome; familial dysautonomia; most often in Jewish children); autosomal-recessive	Inhibitor of kappa light polypeptide gene enhancer in B cells, kinase complex-associated protein (IKBKAP or IKAP) gene; 9q31-q33	Predominantly autonomic neuropathy, presenting in infancy; axonal degeneration (mostly unmyelinated fibers); atrophy and loss of sensory and autonomic ganglion cells

The pathologic findings of many of the hereditary neuropathies are those of an axonal neuropathy. Fiber loss is the most prominent finding.

**Hereditary Motor and Sensory Neuropathy Type I**

The most common hereditary peripheral neuropathy, *Charcot-Marie-Tooth (CMT) disease, hypertrophic form (HMSN I)*, usually presents in childhood or early adulthood. A characteristic progressive muscular atrophy of the calf seen in these patients gives rise to the common clinical term *peroneal muscular atrophy*. Patients may be asymptomatic, but when they present, it is often with symptoms such as distal muscle weakness, atrophy of the calf, or secondary orthopedic problems of the foot (such as *pes cavus*).

**Molecular Genetics.**

The disease is genetically heterogeneous. In most pedigrees (known as HMSN IA or CMT1A), there is a duplication of a large region of chromosome 17p11.2-p12, resulting in "segmental trisomy" of the duplicated region. The duplicated segment includes the gene for

**TABLE 27-3** -- Hereditary Neuropathies Accompanying Inherited Metabolic Disease

Disease	Metabolic Defect	Inheritance	Clinical Findings	Pathologic Findings
Adrenoleukodystrophy	ATP-binding cassette, or ABC, transporter protein, subfamily D, member 1 (ALD protein, or ABCD1) gene; Xq28	X-linked; 4% of female carriers are symptomatic	Mixed motor and sensory neuropathy, adrenal insufficiency, spastic paraplegia; onset between 10 and 20 years for males with leukodystrophy, between 20 and 40 years for females with myeloneuropathy	Segmental demyelination, with onion bulbs; axonal degeneration (myelinated and unmyelinated); electron microscopy; linear inclusions in Schwann cells
Familial amyloid polyneuropathies	Transthyretin (TTR) gene (rarely other genes); 18q11.2-q12.1	Autosomal-dominant	Sensory and autonomic dysfunction; age at onset varies with site of mutation	Amyloid deposits in vessel walls and connective tissue with axonal degeneration
Porphyria, acute intermittent (AIP) or variegate coproporphyria	Enzymes involved in heme synthesis (acute intermittent porphyria—porphobilinogen deaminase deficiency; 11q24.1-q24.2)	Autosomal-dominant	Acute episodes of neurologic dysfunction, psychiatric disturbances, abdominal pain, seizures, proximal weakness, autonomic dysfunction; attacks may be precipitated by drugs	Acute and chronic axonal degeneration; regenerating clusters
Refsum disease	Peroxisomal enzyme phytanoyl CoA $\alpha$ -hydroxylase (PAHX) gene; 10pter-p11.2	Autosomal-recessive	Mixed motor and sensory neuropathy with palpable nerves; ataxia, night blindness, retinitis pigmentosa, ichthyosis; age at onset before 20 years (a genetically distinct infantile form also exists)	Severe onion bulb formation

peripheral myelin protein 22 (PMP22), but whether the disease is caused by overexpression of PMP22, by gene dosage effect,<sup>[28] [29]</sup> or by duplication of other adjacent genes is not clear. A separate genetic locus on chromosome 1 involves myelin protein zero (MPZ) but produces an identical clinical phenotype (HMSN IB).<sup>[26]</sup> A third set of pedigrees shows linkage to chromosome 16p, and is associated with mutations in a gene whose product is involved in protein degradation pathways.<sup>[30]</sup> In addition, some pedigrees are associated with mutations in the gene for the gap junction protein connexin-32, which is located on the X chromosome.<sup>[31]</sup>

#### Morphology.

CMT1 is a demyelinating neuropathy, both by nerve conduction velocity studies and pathologically. Histologic examination shows the consequences of repetitive demyelination and remyelination, with multiple onion bulbs, more pronounced in distal nerves than in proximal nerves (see Fig. 27-5 ). The axon is often present in the center of the onion bulb, and the myelin sheath is usually thin or absent. The redundant layers of Schwann cell hyperplasia surrounding individual axons are associated with enlargement of individual peripheral nerves that may be individually palpable, which has led to the term **hypertrophic neuropathy**. In the longitudinal plane, individual segments of the axon may show evidence of segmental demyelination. Autopsy studies of affected individuals have shown degeneration of the posterior columns of the spinal cord.

#### Clinical Course.



The disorder is usually autosomal-dominant, and although it is slowly progressive, the disability of sensorimotor deficits and associated orthopedic problems such as pes cavus are usually limited in severity, and a normal life span is typical. The relationship between the molecular events and the observed peripheral nerve pathology is not well understood.

#### **Other Hereditary Motor and Sensory Neuropathies**

##### **HMSN II**

This is a neuronal form of autosomal-dominant Charcot-Marie-Tooth disease that presents with signs and symptoms similar to those of HMSN I, although nerve enlargement is not seen and the disease presents at a slightly later age. This form is less common than HMSN I, and in some families (designated CMT2A), it is linked to chromosome 1p35-p36.<sup>[26]</sup> Additional, less common loci have been linked to forms CMT 2B to 2G.<sup>[26]</sup> Nerve biopsy specimens in this disorder show loss of myelinated axons as the predominant finding. Segmental demyelination of internodes is infrequent. These findings suggest that the site of primary cellular dysfunction is the axon or neuron.

##### **Dejerine-Sottas Disease (HMSN III)**

Dejerine-Sottas disease is a slowly progressive, autosomal-recessive disorder that begins in early childhood, manifested by delay in developmental milestones, such as the acquisition of motor skills. In contrast to HMSN I and HMSN II, in which muscular atrophy is limited to the leg, both trunk and limb muscles are involved in Dejerine-Sottas disease. On physical examination, *enlarged peripheral nerves* can be detected by inspection and palpation. The deep tendon reflexes are depressed or absent, and nerve conduction velocity is slowed. HMSN III is genetically heterogeneous, and arises from distinct mutations in the same myelin-associated genes that are mutated in HMSN I. These include genes encoding peripheral

myelin protein 22 (PMP22), myelin protein zero (MPZ), periaxin (PRX), and early growth response 2 (EGR2).<sup>[32]</sup> <sup>[33]</sup> <sup>[34]</sup> Morphologically, the size of individual peripheral nerve fascicles is increased, often dramatically, with abundant onion bulb formation as well as segmental demyelination. There is usually evidence of axonal loss, and the axons that remain are often of diminished caliber. These findings are most severe in the distal portions of the peripheral nervous system; however, autopsy studies have shown that similar findings may be present in spinal roots.

Other less common forms of HMSN are characterized by additional neurologic and ophthalmologic abnormalities, such as retinitis pigmentosa and deafness.

#### **ACQUIRED METABOLIC AND TOXIC NEUROPATHIES**

Functional and structural changes in peripheral nerve develop in response to various metabolic alterations—either from endogenous disorders or from exogenous agents. The most common of these processes are discussed here.

##### **Peripheral Neuropathy in Adult-Onset Diabetes Mellitus**

The prevalence of peripheral neuropathy in patients with diabetes mellitus depends on the duration of the disease, with up to 50% of diabetic patients having peripheral neuropathy clinically after 25 years of diabetes and nearly 100% having conduction abnormalities electrophysiologically.<sup>[35]</sup> Several distinct clinicopathologic patterns of diabetes-related peripheral nerve abnormalities have been recognized ( Chapter 24 ). They are categorized as *distal symmetric sensory or sensorimotor neuropathy*, *autonomic neuropathy*, and *focal or multifocal asymmetric neuropathy*. Individuals may develop any combination of these lesions; in fact, the first two (sensorimotor and autonomic) are often found together.